

# Modified stethoscope for auscultation of temporomandibular joint sounds

S. R. Dagar, A. J. Pakhan, R. U. Thombare, A. Bhovar

Department of Prosthodontics, Sharad Pawar Dental College and Hospital, Sawangi (Meghe), Wardha, Maharashtra, India

## For correspondence

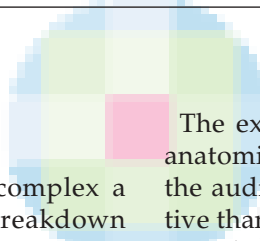
Sanjiv Rajender Dagar, Room No 16, Department of Prosthodontics, Sharad Pawar dental college & hospital, Sawangi (Meghe), Wardha - 442 001, Maharashtra, India. E-mail: sanjivdagar\_55@yahoo.co.in

The masticatory system is extremely complex. It is made up primarily of bones, muscles, ligaments and teeth. Normally, the physical examination of the masticatory muscles and temporomandibular joint (TMJ) involves thorough muscle palpation, palpation, auscultation for TMJ sounds and measurement of mandibular range of motion. A trained clinician who uses palpation and a stethoscope, typically performs this assessment. One of the characteristic features of many patients with temporomandibular disorders, is joint sound. A widely used method for joint sound detection, is the clinical examination of the joint with light finger palpation of the TMJ during motion and stethoscope auscultation, as needed.

**Key words:** Stethoscope, bell, soundscope, pop and thud

## INTRODUCTION

It is realistic to assume that the more complex a system is, the greater the likelihood that breakdown will occur. It is remarkable to think that in most instances, it functions without major complications for the lifetime of the individual. When breakdown does occur, it can produce a situation as complicated as the system itself. There are various commercial instruments like stethoscope, pressure algometers, sound/vibration detection devices, jaw tracking devices etc. that claim to aid in the diagnosis of various temporomandibular joint disorders. This article describes the fabrication of a simple modified stethoscope for auscultation of TMJ sounds. However, the reliability of stethoscope auscultation for TMJ sounds has been questioned. The studies previously cited, indicate that the ability to detect the presence of TMJ sounds varies from poor to excellent, depending on the technique used. The severity and nature of the click may vary from patient to patient and even within different sides in the same patient. It was documented that quantitative and qualitative analysis of the joint sounds and vibrations, allow clinicians to better differentiate abnormal joints from normal joints. Each specific disease of the TMJ was characterized by a unique relationship between the sounds propagated by the joint and the movement.<sup>[1]</sup>



The external auditory meatus (EAM) is the closest anatomically approachable structure to the TMJ and the auditory canal has been shown to be more sensitive than the surface of the skin, when evaluating joint sounds.<sup>[2]</sup> Fabrication of the simple modified stethoscope allows the small and smooth end of the custom-made soundscope, for auscultation of TMJ sounds in EAM.

## MATERIALS AND METHODS

*The Stethoscope:* It consist of bell chestpiece with membrane, Y-tubing and eartips. The stiffer the membrane, the higher is its natural frequency of oscillation and the more efficient it is at higher frequencies. It also gives resonance to the bell and the resonance of the bell amplifies the joint sound. The short length of tube can maximize high frequencies and still not be too short. However, 15 inches is a good compromise between the ideal of 12 inches and the usual length of 20 to 22 inches, that are commercially available. Reflected waves in the tubing may amplify sounds. Therefore, different tubing lengths may amplify different frequencies. The thicker the tube, the better is the elimination of room noise. A vinyl tube has been found to be better than rubber for this purpose. Very narrow tubes carry low frequencies best and wide tubing carries high frequencies best. An internal diameter of 3

mm was once recommended as the ideal compromise for carrying both frequencies. However, it has recently been found that 4.6 mm is even better.<sup>[3]</sup>

The greatest impairment of the efficiency of a stethoscope, is the air leak. Room noise due to air leaks tends to mask high frequencies more than low, once.

### Procedure

1. A stethoscope was obtained (Microtone; M. R. surgical co. India) [Figure 1].
2. Stainless steel "soundscope", 18 mm in length and 10 mm in diameter, was fabricated [Figure 2].
3. The soundscope consist of a metal tube (A), stiff membrane (B) threaded metal cap (C) [Figure 3].
4. A stiff, 8 mm diameter membrane was cut.
5. This 8 mm round membrane was placed on soundscope and tightened with a threaded metal cap.
6. The bell of stethoscope was removed along with its 30 mm long metal connector from the Y-tubing and the screw that joins the bell to the metal connector was loosened. This 30 mm long metal connector was inserted into the soundscope and rotated, until it was fully tightened [Figure 4]. This whole unit is then inserted in the Y-tubing [Figure 5].

Insert the smooth end of the soundscope into the external auditory meatus of the patient to auscultate TMJ sounds [Figure 6].

## DISCUSSION

### Functional disorders of the temporomandibular joints:

Functional disorders of the temporomandibular joints are probably the most common findings one sees when examining a patient for masticatory dysfunction. Some do not produce painful symptoms and therefore the patient may not seek treatment. When present however, they generally fall into two broad categories.<sup>[4]</sup>

- a. Disc-interference disorders
- b. Inflammatory disorders

Disc-interference disorders arise from disturbances between the articular disc and the condyle. They can be due to irregularities of the articular surfaces, or to alterations in the attachment between the disc and the condyle (condyle-disc complex).

Inflammatory disorders arise from any localized protective response of the tissues that make up the TMJ. They are often the result of chronic or progressive disc interference disorders.

The two major symptoms with functional TMJ problems, are pain and dysfunction.

Dysfunction is common with functional disorders of the TMJ. Usually, it presents as a disruption of the normal condyle-disc movement, with the production

of joint sounds. The joint sounds may be a single event of short duration, known as a click. If this is loud, it may be referred to as a pop. Crepitation is a multiple, rough, gravel like sound, described as grating and complicated. Dysfunction of the TMJ may also present as catching sensations, when the patient opens his mouth. Dysfunction of the TMJ is always directly related to jaw movements.

### a) Disc-interference disorders

The disc-interference disorders are divided into their various subcategories.

#### *Derangement of the condyle - disc complex*

These present as a range of conditions, most of which can be viewed as a continuum of progressive events. They occur because the relationship between the articular disc and the condyle changes. The important feature of this, is that the condyle translates across the disc to some degree, when movement begins. During such abrupt movements, often a clicking sound occurs. This type of movement does not occur in the normal joints. This single click observed during opening movement, represents the very early stage of what is called, internal derangement.

If this condition persists, a second stage of internal derangement is noted, which is characterized by reciprocal click. As the disc is more chronically repositioned forward and medially by muscle action of the superior lateral pterygoid, the discal ligaments are further elongated. During mandibular opening, a sound is heard, that represents the condyle moving across the posterior border of the disc, to its normal position on the intermediate zone. During closing, the normal disc position is maintained until the condyle returns to very near the closed joint position. This final movement of the condyle across the posterior border of the disc creates a second clicking sound and thus the reciprocal click.

#### *Functional dislocation of the disc*

A functionally displaced disc can create joint sounds, as the condyle skids across the disc during normal translation of the mandible. If the disc becomes functionally dislocated, the joint sounds are eliminated since no skidding can occur. This can be helpful information in distinguishing a functional displacement from a functional dislocation.

#### *Structural incompatibility of the articular surface*

- i) Adhesion between condyle and disc:  
Adhesion can occur between the disc and the condyle, as well as between the disc and the fossa. When movement begins, a sense of stiffness is felt in the joint, until enough energy is exerted to break

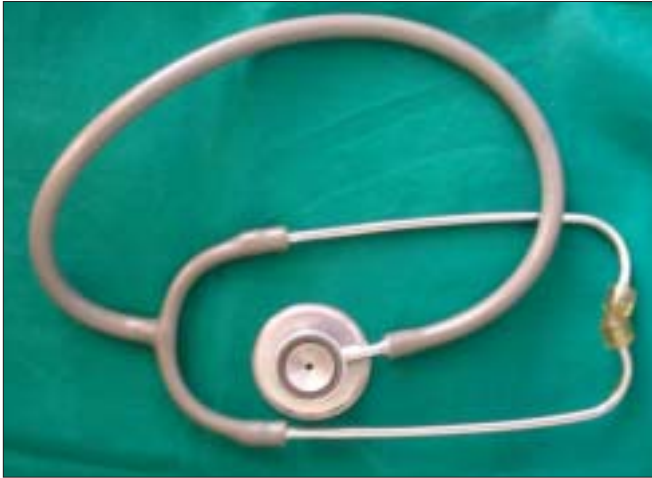

Figure 1: Stethoscope



Figure 4: Metal connector inserted into the soundscope



Figure 2: Soundscope

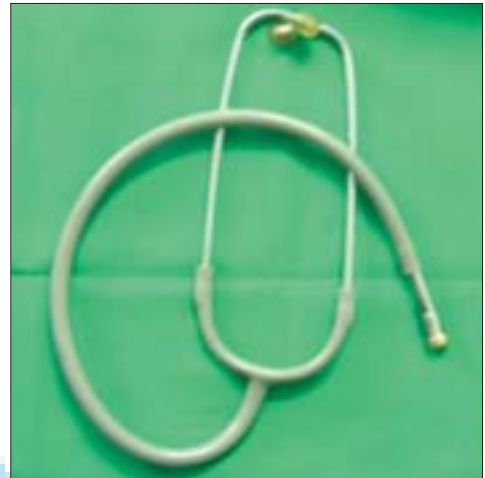

Figure 5: Modified stethoscope



Figure 3: Metal tube (A), Stiff membrane (B) and Metal cap (C)

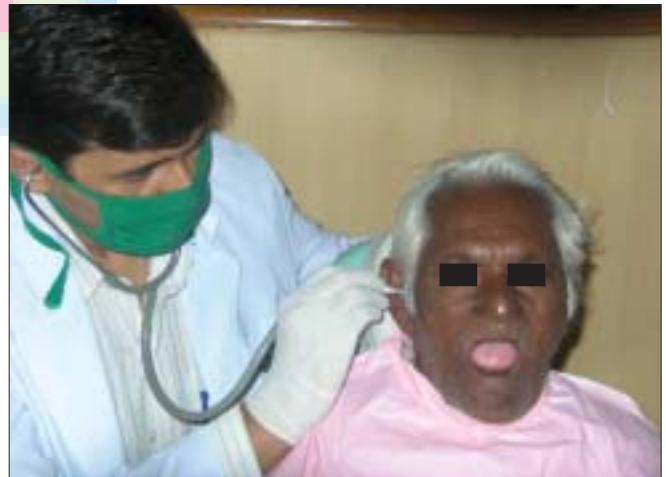

Figure 6: Auscultation of TMJ sounds by modified stethoscope

apart the adhering surfaces. This breaking apart of adhesions can be felt as a click and it denotes the instant return to normal range of mandibular movement.

- ii) Structural (morphological) defect in the condyle and disc:

If the morphology of the disc, condyle, or fossa is altered, joint function can be impaired. This alterations in form, can create clicking and catching of the jaw, similar to that seen with functional disc

displacements. The main clinical characteristics differentiating this type of problem from disc displacements, is the consistent presence of clicking sound during jaw movement. Since the disorder is associated with altered form, the opening and closing clicks can occur at the same interincisal opening, even when the speed and force of opening and closing change. With disc displacements, the opening and closing clicks are usually at different interincisal distances.

### **Subluxation**

Clinical observations of some joints reveal that, as the mouth opens to its full extent, there is a momentary pause followed by a sudden jump or leap to the maxillary open position. This jump does not produce a clicking sound, but instead, is accompanied by more of a thud.

### **Spontaneous dislocation**

Wide opening of mouth beyond the maximum limit of opening, almost always produces this condition. Spontaneous dislocation typically occurs in a patient whose fossa anatomy, that permits subluxation. As with the subluxation, the disc becomes maximally rotated posteriorly on the condyle, as far as permitted by the anterior capsular ligament, before full translation of the condyle occurs. If the mouth is forcefully opened wider, the anterior capsular ligament through the discal space, pulls the disc forward. Then the discal space collapses as the condyle suddenly rides superiorly on the retrodiscal tissues and this traps the disc forward along with a loud sound. In spontaneous dislocation, the patient cannot close the mouth because the mandible locks.

## **CONCLUSION**

The TMJ is the only joint which is directly related to the prosthetic dentistry. The signs and symptoms of temporomandibular disorders are extremely common findings. Some of these appear as significant symptoms, that motivate the patient to seek treatment. Many however, are subtle and not even at a level of clinical awareness by the patient. Some subclinical signs can later become apparent and represent more significant functional disturbances, if left unattended. It is therefore extremely important, that each sign and symptom be identified by means of a thorough history and examination procedure. This modified stethoscope is a simple and economical diagnostic aid, exclusively for TMJ sound auscultation. This modification provides more precise sound analysis than conventional stetho-

scope, which is the essential foundation for successful treatment. From our in-vivo study we can conclude that:

- The single click during mandibular opening represents the very early stage of internal derangement. If this condition persists, the reciprocal sound is heard.
- The disc displacement and the adhesion between condyle and disc, also produce clicking. The clicks due to adhesions can be differentiated from clicks associated with disc displacement by the fact that, in joint adhesion, after the single click, the joint is silent during subsequent opening and closing. With a disc displacement, the clicking is repeated during each opening and closing cycle.
- The morphological defects in the condyle or disc also create clicking similar to that heard with disc displacements. The differentiating feature is that in morphological defects, the opening and closing clicks occur at the same interincisal opening, whereas with disc displacement, the opening and closing clicks are usually at different interincisal distances.
- The thud type of sound denotes subluxation, whereas pop type of sound during wide mouth opening denotes the spontaneous dislocation.

This is based on in-vivo study. And further additional research on sound/vibratory analysis of joint sounds on mandibular movement is required.

## **REFERENCES**

1. Baba K, Tsukiyama Y, Yamazaki M, Clark GT. A review of temporomandibular disorder diagnostic techniques. *J Prosthet Dent* 2001;86:184-94.
2. Leknius C, Kenyon BJ. Simple instrument for auscultation of temporomandibular joint sounds. *J Prosthet Dent* 2004;92:604.
3. Constant J. *Bedside cardiology*. 5th ed. Lippincott Williams and Wilkins: Philadelphia; 1999. p. 119-22.
4. Okeson JP. *Management of temporomandibular disorders and occlusion*. 2nd ed, The CV Mosby Co: St. Louis; 1989. p. 173-206.