

# Prosthetic rehabilitation following segmental mandibulectomy

**Pramod Raj Joshi, Gaganjit Singh Saini, Pratheek Shetty, Sudhakar G. Bhat**

Department of Prosthodontics and Maxillofacial Prosthetics, Manipal College of Dental Sciences, Manipal Academy of Higher Education, Mangalore, Karnataka, India

## For correspondence

Dr. Pratheek Shetty, Department of Prosthodontics and Maxillofacial Prosthetics, Manipal College of Dental Sciences, Light House Hill Road, Mangalore - 575 001, Karnataka, India. E-mail: [pratheek.shetty@manipal.edu](mailto:pratheek.shetty@manipal.edu)

Mandibular defects caused by surgical intervention to eradicate or control disease frequently involve jaw resection. Loss of continuity of the mandible destroys the balance of the lower face and leads to decreased mandibular function by deviation of the residual segment toward the surgical site. Prosthetic methods advocated to reduce or eliminate mandibular deviation include intermaxillary fixation, removable mandibular guide flange prosthesis, implant-supported prosthesis, and palatally based guidance restorations. These methods and restorations would be combined with a well-organized mandibular exercise regimen. This clinical report describes the prosthetic rehabilitation following segmental mandibulectomy.

**Key words:** Guide flange prosthesis, prosthetic rehabilitation, segmental mandibulectomy

## INTRODUCTION

Success of mandibular guidance therapy varies and depends upon the nature of the surgical defect, early initiation of guidance therapy, patient cooperation, and other factors. When the condyle is lost on the resected side, guidance therapy may be required to achieve improved alignment and function. Deviation of mandible towards resected side is dependent upon the amount of soft and hard tissue resected, the method of surgical site closure, the degree of impaired tongue function, the presence and condition of teeth, the loss of proprioceptive sense of occlusion, and the timing of prosthodontic therapy. The goals of prosthodontic treatment include providing lip support, improving articulation, reducing drooling, and regaining favorable esthetics.<sup>[1-3]</sup>

## REVIEW OF LITERATURE

Robinson and Rubright<sup>[4]</sup> suggested that if the mandible can be manipulated into an acceptable maxillomandibular relationship but the patient lacks the motor control to bring the mandible into occlusion, a cast mandibular resection restoration is appropriate. This mandibular guidance prosthesis consists of removable partial denture framework, with a metal flange extending superiorly on the buccal aspect of the bicuspids, and molars on the nondefect side. This flange engages the maxillary teeth during

mandibular closure, thereby directing the mandible into an appropriate intercuspal position.

Fattore *et al.*<sup>[5]</sup> advocated a 2-piece Gunning splint both for intermaxillary fixation and as a guidance appliance for an edentulous patient following hemisection of the mandible.

Marunick *et al.*<sup>[6]</sup> concluded that an implant-assisted mandibular resection prosthesis enhanced masticatory function (swallowing-threshold performance).

Beumer *et al.*<sup>[1]</sup> reported that if the mandible can be manipulated comfortably into an acceptable occlusal position, a cast metal guidance ramp will be appropriate. If some resistance is encountered in positioning the mandible, a guidance ramp of acrylic resin is suggested, as this material can be periodically adjusted as improved relationship is obtained.

Cheng *et al.*<sup>[3]</sup> suggested a hinged removable mandibular complete denture prosthesis using a sectional impression tray technique and a custom-made hinge mechanism for patients with the presence of excessive lingual undercuts after mandibulectomy and surgical reconstruction.

Oelgiesser *et al.*<sup>[7]</sup> stated that an implant-supported fixed prosthesis can be an optional treatment modality for functional and esthetic rehabilitation.

Sahin *et al.*<sup>[2]</sup> described the fabrication of cast metal guidance prostheses with supporting flanges and retentive flanges for a patient following segmental mandibulectomy.

Garrett *et al.*<sup>[8]</sup> suggested that careful consideration

must be given to selection of the type of prosthetic rehabilitation and the timing of implant placement if an implant-supported prosthesis is planned.

### CASE REPORT

A 32-year-old male patient was referred to the Department of Prosthodontics, MCOCS, Mangalore, for prosthetic rehabilitation following resection of the right mandible [Figure 1]. The patient's history indicated that 15 years back, fracture of the right side of the mandible occurred due to contact sports; the lesion eventually degraded and was later diagnosed as ameloblastoma. Mandibular resection surgery

was carried out then, and the right side of mandible beyond right lateral incisor region was resected and augmented using Bowerman/Conroy prosthesis.<sup>[9]</sup> After 15 years, surgery was carried out once again (Dept. of Oral Surgery, MCOCS, Mangalore) and iliac bone graft placed. The surgery focused mainly to provide the edentulous region with favorable tissue bed to receive a prosthesis.

### Clinical examination and treatment plan

The mandibular defect reported in this clinical report is Cantor and Curtis Class IV defect [Figure 2], wherein resection of lateral portion of mandible is carried out with subsequent augmentation to restore form and function. TMJ examination revealed severe deviation of the mandible towards the resected site. Intraoral examination revealed an intact natural dentition in maxillary arch. Mandibular teeth present were 21 12345678 after resection. The tissue bed in the edentulous region was not displaceable, and the denture foundation in the edentulous area was ideal for the support. Panoramic radiograph revealed mandibular continuity defect on the right side beyond right lateral incisor and Bowerman/Conroy prosthesis being used to augment the defect [Figure 3].<sup>[10]</sup>

Based on the clinical situation, a cast-removable partial denture with a buccal guiding flange was planned.

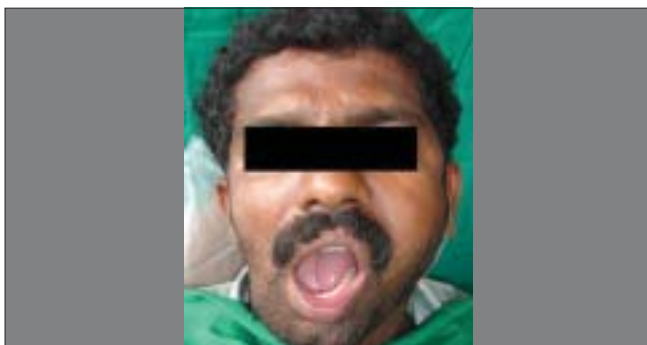

Figure 1: Extraoral view of patient

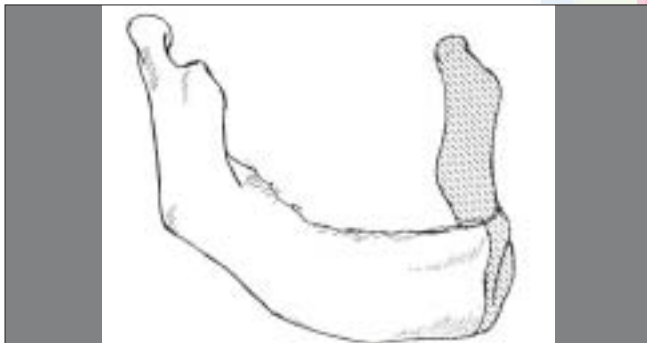


Figure 2: Class IV resection of lateral portion of mandible with subsequent augmentation (based on a classification of mandibular defects described by Cantor and Curtis)

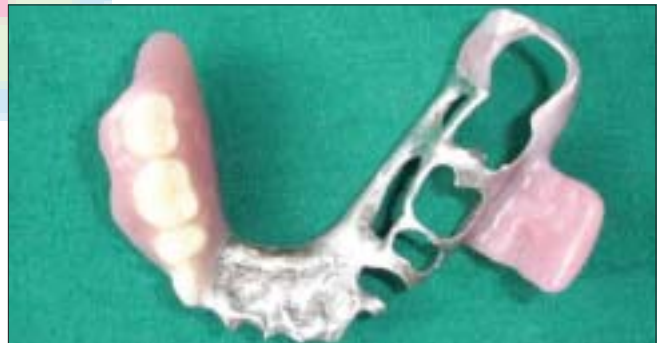

Figure 4: View of framework with guidance flange on left side

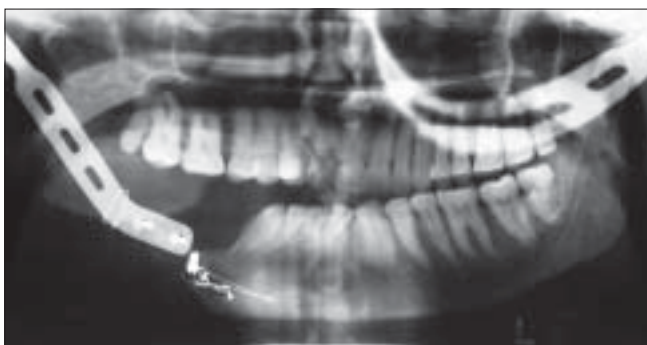


Figure 3: Orthopantomograph showing Bowerman/Conroy prosthesis used to augment the mandibular defect

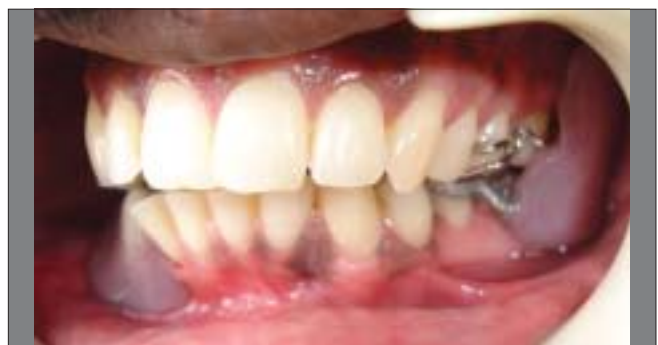

Figure 5: Definitive intraoral result

It was noted that that the patient's mandible could be manually placed into centric occlusion without excessive force.

Occlusal rest seats were prepared using a triangular configuration of support, which is effective in neutralizing leverage. Definitive impressions were made with addition of polysilicone (Affinis, Coltene Whaledent, Switzerland) for removable partial denture frameworks for the mandible. Definitive casts were poured with type IV dental stone (Kalrock, Kalabhai Karson Pvt. Ltd., Mumbai, India). The casts were surveyed (surveyor: Paraline, Dentarum, Germany), and removable partial denture for the mandible was designed. RPD framework engaged most of the remaining teeth to gain the additional retention needed for guidance and support. The guidance flange was designed to extend from a continuous clasp along the buccal surface of the premolar and molar teeth on the nondefect side. The framework was finished, evaluated, and adjusted intraorally.

As the mandible could be guided into centric occlusion, the framework was inserted intraorally and interocclusal record obtained using modeling wax (modeling wax no. 2, The Hindustan Dental Products, Hyderabad, India). It was determined that the cheek and the tongue had sufficient support for future acrylic resin. Guide flange was established grossly on the articulator in modeling wax. Completed wax patterns were replaced with heat-polymerized acrylic resin following conventional laboratory procedures and finished and polished [Figure 4]. The framework was evaluated intraorally and adjusted. It was noted that the patient was able to achieve a functional intercuspal position immediately after insertion of the prosthesis. The prosthesis was removed from the mouth. The prosthesis was repolished and inserted. Hawleys appliance incorporating Adams clasp and triangular clasp was inserted in order to resist the movement of maxillary teeth adjacent to the flange. Cast partial denture framework for maxilla can also be a better alternative for the bimaxillary stabilization [Figure 5].

## DISCUSSION

Mandibular guidance prosthesis can be helpful in minimizing the unavoidable sequelae resulting from extensive mandibular resection, some of which are muscular contraction, mutilation of occlusal plane, scar contracture, etc. Its success varies and depends upon the nature of the surgical defect, early initiation of the guidance therapy, patient's expectation/cooperation, and other factors.<sup>[1]</sup>

This prosthesis should be provided to restore the mastication within the unique movement capabilities of the residual function in the mandible. This should be

designed following customary prosthodontic guidelines. These include broad stress distribution, cross arch stabilization using a rigid major connector stabilizing and retaining components at locations within the arch to minimize dislodgement, and replacement of tooth position — all these optimize prosthesis. Stability and functional needs and modification to these principles are determined on an evidence basis and greatly influenced by unique residual tissue characteristics and mandibular movement dynamics.<sup>[11]</sup>

The mandibular guidance prosthesis consists of a removable partial denture framework, with a flange extending laterally and superiorly on the buccal aspect of the bicuspid and molars on the nondefect side. This flange engages the maxillary teeth during mandibular closure, thereby directing the mandible into an appropriate intercuspal position. The terminal aspects of the retentive and reciprocal elements are joined so that stresses originating from the prosthesis can be favorably distributed between multiple abutment teeth; and also to provide support for the retentive mesh, which is subsequently used to develop the acrylic guide flange. The clasps were positioned as far posterior as possible; and the other, as far anterior so that a large possible area of the denture will be enclosed in a triangle formed by the retentive clasps, which is most effective in neutralizing leverage.<sup>[1,12]</sup>

Earlier the mandibular guidance therapy is initiated in the course of treatment, more successful the patient's definitive occlusal relationship. Mandibular guidance therapy begins when immediate postsurgical sequelae have subsided, usually 2 weeks after surgery. Various methods advocated to reduce or eliminate mandibular deviation include mandibular guidance therapy, intermaxillary fixation, resection guidance restorations, splinting, and fabrication of prosthesis similar to 'swing lock' removable partial dentures. For best results, these methods and restorations would be combined with a well-organized mandibular exercise regimen. An implant-supported fixed prosthesis can be an optional treatment modality for functional and esthetic rehabilitation. Given the poor prognosis for most mandibular resection patients, the conservative approach of delayed implant placement from 2 to 5 years for these patients should be appreciated.<sup>[1,5,13-15]</sup>

The use of resection guidance restoration is predicted on the basis of presence of maxillary and mandibular teeth, as teeth presence in both arches is important for effective guidance and reprogramming of mandibular movement. The patient in this clinical report retained all of his maxillary dentition and mandibular dentition from left third molar till right lateral incisor, and consequently better proprioceptive sense. For the patient, this prosthesis provided comfort and sufficient function, and he was able to achieve functional intercuspal position immediately after the insertion

of the prosthesis.<sup>[1,10]</sup>

A removable prosthesis is an equally effective alternative for most patients with mandibular defects, considering the poor prognosis, difficulty in decision making for use of implant, and economic feasibility.

## REFERENCES

1. Beumer J 3rd, Curtis TA, Marunick MT. Maxillofacial rehabilitation: Prosthodontic and surgical consideration. St. Louis: Ishiyaku. Euro America; 1996. p. 184 – 8.
2. Sahin N, Hekimoglu C, Aslan Y. The fabrication of cast metal guidance flange prostheses for a patient with segmental mandibulectomy: A clinical report. *J Prosthet Dent* 2005;93:217-20.
3. Cheng AC, Wee AG, Morrison D, Maxymiw WG. Hinged mandibular removable complete denture for post-mandibulectomy patients. *J Prosthet Dent* 1999;82:103-6.
4. Robinson JE, Rubright WC. Use of a guide plane for maintaining the residual fragment in partial or hemimandibulectomy. *J Prosthet Dent* 1964;14:992-9.
5. Fattore L, Marchmont-Robinson H, Crinzi RA, Edmonds DC. Use of a two-piece Gunning splint as a mandibular guide appliance for a patient treated for ameloblastoma. *Oral Surg Oral Med Oral Pathol* 1988;66:662-5.
6. Marunick M, Mathog RH, Boyd SB. Functional outcome of an implant-retained edentulous mandibular resection prosthesis: A clinical report. *J Prosthet Dent* 1995;74:441-5.
7. Oelgiesser D, Levin L, Barak S, Schwartz-Arad D. Rehabilitation of an irradiated mandible after mandibular resection using implant/tooth-supported fixed prosthesis: A clinical report. *J Prosthet Dent* 2004;91:310-4.
8. Garrett N, Roumanas ED, Blackwell KE, Freymiller E, Abemayor E, Wong WK, *et al.* Efficacy of conventional and implant-supported mandibular resection prostheses: Study overview and treatment outcomes. *J Prosthet Dent* 2006;96:13-24.
9. Bowerman JE, Conroy B. A universal kit in titanium for immediate replacement of the resected mandible. *Br J Oral Surg* 1969;6:223.
10. Fonseca RJ, Davis WH. Reconstructive preprosthetic oral and maxillofacial surgery. 2<sup>nd</sup> ed. WB Saunders Company; p.1063 -7.
11. Carr AB, McGivney GP, Brown DT. McCracken's removable partial prosthodontics. 11<sup>th</sup> ed. India: Mosby Inc; p. 414.
12. Steward KL, Rudd KD, Kuebker WA. Clinical removable partial prosthodontics, 1<sup>st</sup> ed. St. Louis, Toronto, London: C.V. Mosby Company; 1983. p. 103-4.
13. Aramany MA, Myers EN. Intermaxillary fixation following mandibular resection. *J Prosthet Dent* 1977;37:437-44.
14. Swoope CC. Prosthetic management of resected edentulous mandibles. *J Prosthet Dent* 1969;21:197-202.
15. Marunick MT, Roumanas ED. Functional criteria for mandibular implant placement post resection and reconstruction for cancer. *J Prosthet Dent* 1999;82: 107-13.

Source of Support: Nil, Conflict of Interest: None declared.