

## Telescopic Overdenture Supported by a Combination of Tooth and an Implant: A Clinical Report

Ponsekhar A. Abraham · Pradeep Koka ·  
K. Murugesan · M. Vasanthakumar

Received: 5 August 2010 / Accepted: 26 August 2010 / Published online: 9 December 2010  
© Indian Prosthodontic Society 2010

**Abstract** The conventional modality of treatment of partial edentulousness with reduced number of teeth was to render them complete edentulous and provide them complete denture or an overdenture with support of few remaining teeth. The goal of maintenance of roots are to prevent alveolar bone resorption, provide better load transmission, maintain sensory feedback and achieve better stability of denture with emphasis on psychological aspect of not being completely edentulous. Over the recent past titanium dental implants have been successfully used as tooth replacement with predictable results. A combination of tooth and implant support is well documented for fixed partial dentures but rarely for overdentures. This clinical report aims at evaluation of tooth root and implant supported mandibular overdenture treatment with telescopic coping.

**Keywords** Reduced dentition · Removable prosthesis · Over denture · Telescopic denture · Combination of tooth and implant · Proprioception

### Introduction

Rehabilitation of a partially edentulous patient can be established using a wide range of prosthetic treatment options. Depending upon the clinical need and demand, restoration of the lost structure can be achieved by using simple conventional removable partial denture, overdenture, fixed partial denture, or dental implants [1].

Many elderly patients exhibit a highly reduced dentition with regard to number of teeth lost due to periodontal disease or caries. In these cases fabrication of fixed prostheses becomes impossible [2].

An overdenture, defined as “a removable partial or complete denture that covers and rests on one or more remaining natural teeth, roots, and/or dental implants is a viable option [3].

Overdentures supported by implants have subsequently gained popularity in the late 1980s and 1990s, due to the overwhelming success of osseointegration. Titanium implants have been used as a successful replacements for tooth [4].

The use of implant-supported overdentures has improved outcomes for edentulous patients compared with conventional dentures. These include, reduced residual ridge resorption, improved retention and support of the prostheses resulting in better quality of life, function, chewing, nutritional status and general health [5].

Telescopic crowns were initially introduced as retainers for removable partial dentures (RPDs) at the beginning of the 20th century. They are also known as a double crown, crown and sleeve coping (CSC), or as Konuskroner, a German term that described a cone shaped design. These crowns consist of an inner or primary telescopic coping, permanently cemented to an abutment, and a congruent detachable outer or secondary telescopic crown, rigidly

---

P. A. Abraham · P. Koka · K. Murugesan · M. Vasanthakumar  
Department of Prosthodontics, SRM Dental College,  
Ramapuram, Chennai 60030, India  
e-mail: pradeepkoka@gmail.com

K. Murugesan  
e-mail: mgsan2k@yahoo.com

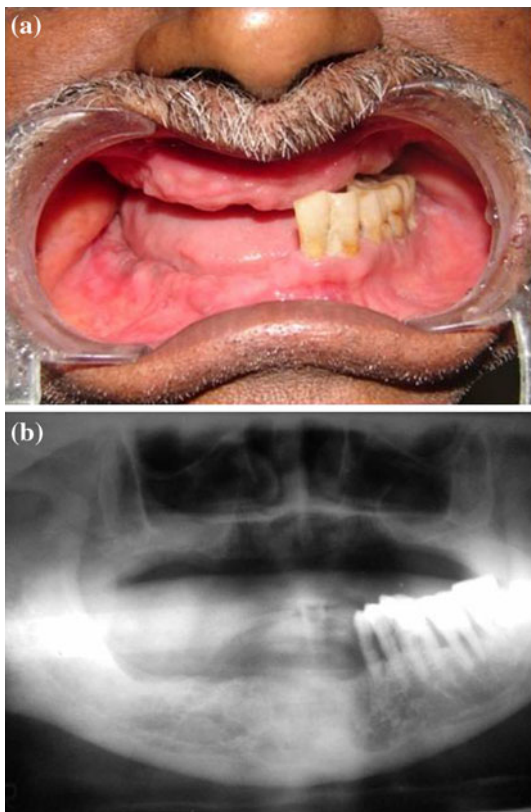
P. A. Abraham (✉)  
2, 11th Avenue, Harrington Road, Shenoy Nagar,  
Chennai 60030, India  
e-mail: drponabe@gmail.com

connected to a detachable prosthesis. The secondary crown engages the primary coping to form a telescopic unit and serves as an anchor for the remainder of the dentition [1, 6].

A telescopic prosthesis is a more versatile alternative because the prosthesis can be repaired without reconstruction of the entire superstructure, despite a localized failure. The patient can disengage telescopic restoration with dislodgment of the outer telescopic crowns from their coping.

### Case Presentation

A 64 year old male patient reported to the Prosthodontics Department, SRM Dental College, Chennai complaining of missing teeth causing inability to masticate food and difficulty in speech. He wanted replacement of missing teeth so that the function can be restored. On examination the following findings were seen—completely edentulous maxilla and unilaterally distributed periodontally compromised teeth in relation to 34, 35, 36, 37 in the mandibular arch as shown in (Fig. 1a, b). Pre treatment clinical examination was performed which included a thorough medical and dental history, radiographic evaluation. Following which a treatment plan was executed which



**Fig. 1** a Intra oral pre-operative. b Pre-operative radiography

included extraction of 34 and 37, periodontal and endodontic therapy in relation to 35 and 36 and placement of a two piece implant in the right mandibular canine region for cross arch stabilisation which is essential for overdenture treatment. Patient was asked to sign a consent form in addition to written explanation regarding the nature of treatment, associated procedures and risks involved with the treatment.

The treatment was divided into three phases—Diagnostic phase included bone mapping procedure and template fabrication, Surgical phase included implant placement and Prosthetic phase includes fabrication of the telescopic prosthesis.

### Diagnostic Phase

Diagnostic casts were prepared from diagnostic alginate impressions (Zelgan 2002—Dentsply) and mounted on mean value articulator to analyze the inter-arch factors. Bone mapping procedure was done to assess the thickness of the alveolar bone. On the mounted study cast a surgical splint template was made with clear self-cure acrylic material.

### Surgical Phase

Following prophylactic course of antibiotics the patient was administered 2% of xylocaine with 1:200000 epinephrine inferior alveolar, lingual and buccal nerve blocks at the proposed implant site area. A crestal incision was made with no: 15 B P blade and handle and a full thickness flap was raised to access the alveolar bone. The exact position of the implant was marked using the surgical template. The pilot drill was used to mark the proposed implant site and penetrate the cortical plate into the cancellous bone through the initial access. The subsequent drills were used as per manufacturers specifications to the required diameter and length. After the osteotomy an endosseous root form two piece UNITI implant D3.3 and L13 mm implant was inserted with placement head delivery and implant inserted with ratchet to final position. Per mucosal-healing extension was screwed to the implant body and flap repositioned and sutures placed.

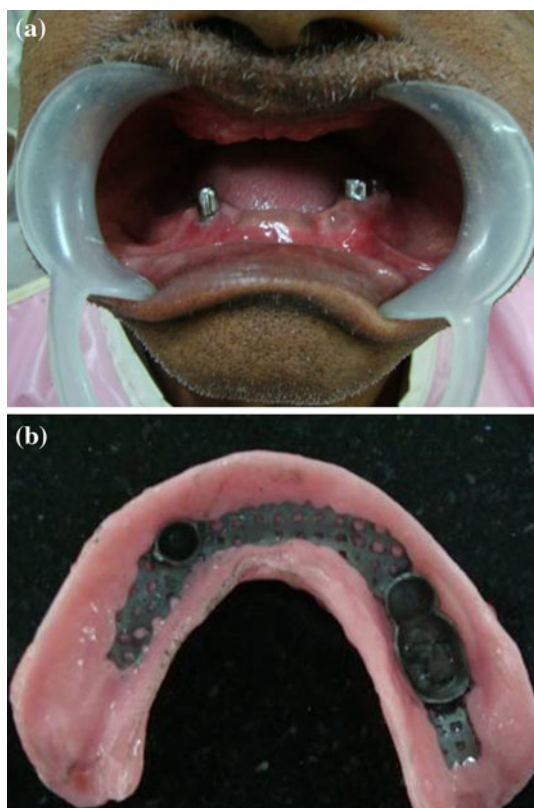
### Prosthetic Phase

The abutment connection followed a healing period of 3 months in the mandible. The teeth present were prepared with a round end tapered diamond. After preparation, impressions were made with addition silicone material

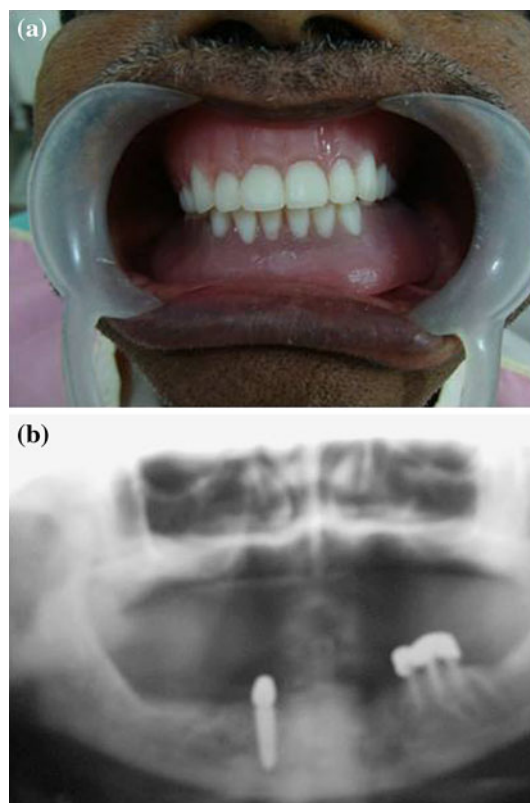
(Aquasil-Dentsply) in a two-stage putty wash technique. Stone models were poured using die stone (Fuji Rock). On the stone models; the implant abutment and prepared teeth were waxed up with primary copings with dome shaped upper surface and a side taper of 6, cast with cobalt–chromium alloy. The castings were milled using a parallel cutting device. The primary copings were cemented with Type I glass ionomer cement (Fuji I) [6] as shown in (Fig. 2a) to the respective abutments.

A putty impression with the primary coping in place was made for the fabrication of the framework. Stone models were poured using Fuji Rock stone die and the cast duplicated with Agar (Bego). The framework with secondary copings were waxed up on the refractory cast and casted in cobalt chromium alloy (Fig. 2b). Retention of the denture was finally provided by the friction between the parallel surfaces of the primary and secondary copings.

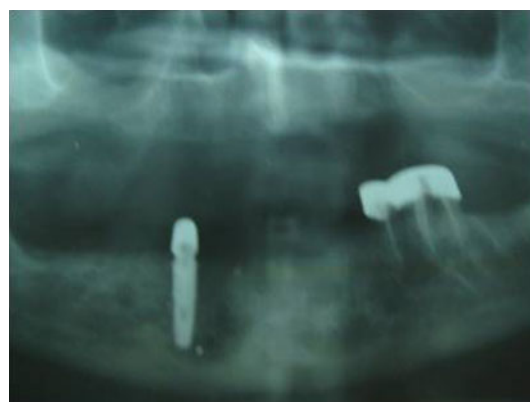After fitting the framework the primary impression of the maxillary and mandibular arches were made and overdenture was fabricated (Fig. 3a) following steps of the conventional complete denture. The patient was recalled after 3 and 6 months for follow up for evaluation of gingival, periodontal health. The patient satisfaction was assessed using the visual analogue scale (VAS) [2] (Figs. 3b, 4).



**Fig. 2** a Cemented primary copings. b Frame work with secondary coping



**Fig. 3** a Intra oral view of maxillary complete and mandibular tooth and implant supported telescopic dentures. b 3 months post operative radiography



**Fig. 4** 6 months post operative radiography

## Discussion

Edentulism leads to an acknowledged impairment of oral function with both aesthetic and psychological changes. Patients who are originally adaptive wearing complete denture may become maladaptive with time, due to ongoing residual ridge resorption, physiological intra-oral changes and the development of altered muscular patterns [7, 8].

In the past patients with reduced dentition were often in danger of being rendered completely edentulous, with fabrication of complete dentures [9].

Clinical experience and the historical literature support the recommendation of at least one root or implant per quadrant in the mandible for cross arch stabilization of overdentures. In case of reduced dentition it is acknowledged that removable overdentures gaining support and retention from roots of teeth or/and implants have more predictable prosthodontic outcomes [10].

The anchorage systems used for overdentures include clips on bar connecting implants, ball attachments and magnets. Recent studies have shown that resilient telescopic crowns can also be used as an alternate treatment modality for overdentures. Telescopic crowns are the least expensive and are very successful if properly maintained by the patient. It requires a high polish of the denture surface, fluoride maintenance and attention to the oral hygiene [1, 6].

The available bone assessed by bone mapping procedure and radiographic evaluation enable placement of a implant with 3.3 mm diameter and 13 mm length in the canine region.

The patient was recalled after 3 and 6 months to evaluate the gingival and periodontal health and patient satisfaction. There were no significant marginal gingival changes observed around the tooth and implant supporting the overdenture and no significant change in the probing depth around the teeth supporting the overdenture.

Further the patient acceptance, Ease of oral hygiene, General satisfaction with overdentures, ability of speak, comfort, esthetic appearance, stability of overdenture during function, and ability to chew showed marked improvement when assessed using visual analogue scale(VAS) [2].

## Summary

For the partially dentate patient, an overdenture design involving teeth and implant may be used successfully to

overcome many of the difficulties associated with a large edentulous span and provided the patient with an esthetic and functional prosthesis. However a study with a large number of subjects and more periodic evaluation of the supporting structures is essential.

## References

1. Siegfried MH, Alexander S, Friedrich G, Manfred GW, Hans-Peter W (2004) Mandibular two-implant telescopic overdentures—10-year clinical and radiographical results. *Clin Oral Implant Res* 15:560–569
2. Hug S, Mantokoudis D, Mericske-Stern R (2006) Clinical evaluation of 3 overdenture concepts with tooth roots and implants: 2-year results. *Int J Prosthodont* 19:236–243
3. Batenburg RH, Meijer HJ, Raghoobar GM, Vissink A (1998) Treatment concept for mandibular overdentures supported by endosseous implants: a literature review. *Int J Oral Maxillofac Implant* 13:539–545
4. Fenton AH (1998) The decade of overdentures: 1970–1980. *J Prosthet Dent* 79:31–36
5. Van Waas MA, Jonkman RE, Kalk W, Van't Hof MA, Plooij J, Van Os JH (1993) Differences two years after tooth extraction in mandibular bone reduction in patients treated with immediate overdentures or with immediate complete dentures. *J Dent Res* 72:1001–1004
6. Dong J, Ikebe K, Gonda T, Nokubi T (2006) Influence of abutment height on strain in a mandibular overdenture. *J Oral Rehabil* 33:594–599
7. Crum RJ, Rooney GE Jr (1978) Alveolar bone loss in overdentures: a five-year study. *J Prosthet Dent* 40:610–613
8. Zarb GA, Mericske-Stern R (2004) Clinical protocol for treatment with implant-supported overdentures. In: Zarb GA, Bolender CL (eds) *Prosthodontic treatment for edentulous patients*, 12th edn. St Louis, CV Mosby and CO, pp 498–509
9. Tallgreen A (1972) The continuing reduction of the residual alveolar ridges in complete denture wearers: a longitudinal study. *J Prosthet Dent* 27:120–131
10. Mericske-stern R (1994) Oral tactile sensibility recorded in overdenture wearers with implant or natural roots. *Int J Oral Maxillofac Implant* 9:63–70