

Gingival Biotype - Prosthodontic Perspective

K. R. Nagaraj, Ravindra C. Savadi, Anupama R. Savadi, G. T. Prashanth Reddy, Srilakshmi J., Malathi Dayalan, Jins John

© Indian Prosthodontic Society

During treatment planning it is important to recognize different gingival biotypes and forms, because they can affect the esthetic outcome of the treatment. This review provides an insight into the different gingival biotypes, their response to inflammation and trauma; significance in different prosthodontic modalities like esthetic rehabilitation and implant therapy.

Keywords: Thick and thin biotypes, Dentogingival complex, Bioform

Introduction

In our modern competitive society, a pleasing appearance often means the difference between success and failure in both our personal and professional lives. The gingival perspective of esthetics is concerned with the soft tissue envelope surrounding the teeth. To provide excellent esthetics, evaluation of gingival type and form is very important from the start of treatment plan to the final restorative placement.

Anatomy of the Dentogingival Complex

The dentogingival complex is composed of three entities:

- The supra-crestal connective tissue attachment - the connective tissue fibers originate from the osseous crest to the cemento-enamel junction (CEJ);
- Epithelial (or junctional epithelium) attachment - the epithelial attachment from the CEJ onto the tooth enamel; and
- The sulcus-coronal to the junctional epithelium is the gingival sulcus.

K. R. Nagaraj✉ • R. C. Savadi • A. R. Savadi • G. T. P. Reddy • Srilakshmi J. • M. Dayalan • J. John
Department of Prosthodontics,
The Oxford Dental College and Hospital,
Bengaluru - 560068, Karnataka, India

e-mail: drkrnag@yahoo.co.in

The biologic width is 2.04 mm (calculated by addition of the linear measurement of the connective tissue and epithelial attachment) [1, 2, 3].

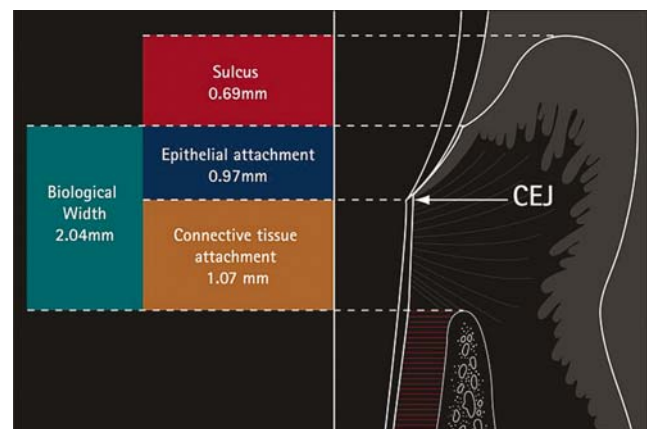


Fig. 1 Biologic width

Gingival Biotype and Bioform

The gingival biotype is classified as thin or thick. Whereas the prevalence of thick biotype is 85% and thin biotype is 15%.

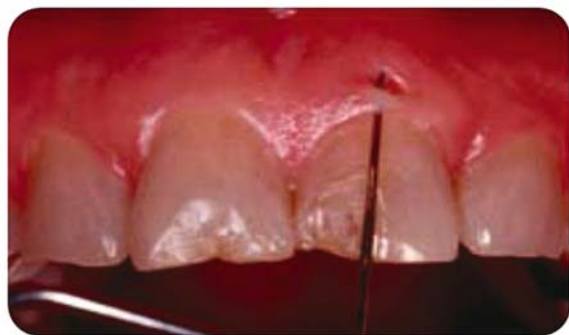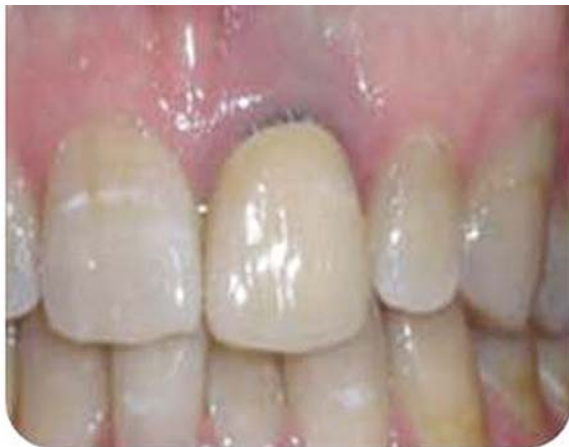The thin periodontal biotypes: Thin gingival tissue tends to be delicate and almost translucent in appearance, the tissue appears friable with a minimal zone of attached Gingiva. Which escalates the risk of recession following crown preparation and periodontal or implant surgery. It

is particularly significant in full coverage crowns for the following reasons.

- The thin gingival margins allow visibility of a metal substructure (either porcelain fused to a metal crown or implant abutment), thereby compromising esthetics in the anterior regions of the mouth. In these circumstances, all-ceramic crowns, or ceramic implant abutments are a prerequisite to avoid esthetic reproof.
- Due to the fragility of the thin tissue, delicate management is essential for avoiding recession and hence visibility of subgingivally placed crown margins at the restoration/tooth interface [1, 4, 5].

Characteristics of Thin Gingiva

- Highly scalloped soft tissue and bony architecture
- Delicate friable soft tissue
- Minimal amount of attached gingiva
- Thin underlying bone characterized by bony dehiscence and fenestration
- Reacts to insults and disease with gingival recession [6].

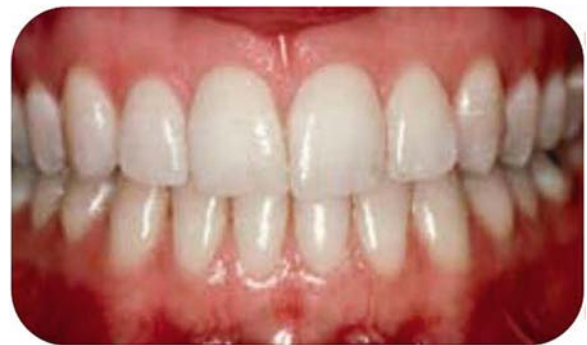

Thin gingival biotype

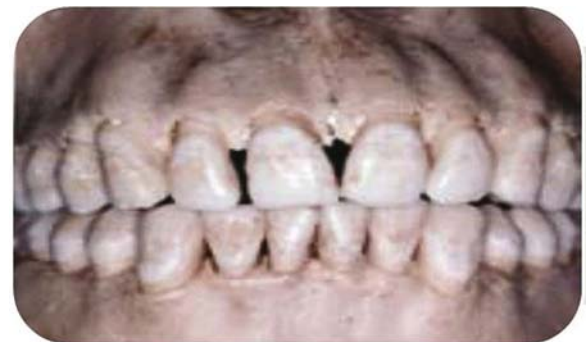Thick periodontal biotype is fibrotic and resilient, making it resistant to surgical procedures with a tendency for pocket formation (as opposed to recession). Therefore, a thick biotype is more conducive for implant placement, resulting in favorable esthetic outcomes.

Characteristics of Thick Gingiva

- Relatively flat soft tissue and bony architecture
- Dense fibrotic soft tissue
- Relatively large amount of attached gingiva
- Thick underlying osseous form
- Relatively resistant to acute trauma
- Reacts to disease with pocket formation and infrabony defect formation [4, 5, 6].



Thick biotype



Bony architecture

Gingival Bioforms

Periodontal bioforms are categorized into three basic gingival scallop morphologies, high, normal and flat. Whereas the facial and lingual gingival scallop mimics the underlying bone architecture, but not interproximally.

Comparison of tissue response to inflammation, surgery and tooth extraction [1, 7]

	Thick gingival biotype	Thin gingival biotype
Inflammation	<ul style="list-style-type: none"> • Soft tissue: marginal inflammation; cyanosis; bleeding on probing; edema/fibrotic changes • Hard tissue: bone loss with pocket formation/infrabony defects 	<ul style="list-style-type: none"> • Soft tissue: thin marginal redness gingival recession • Hard tissue: rapid bone loss associated with soft tissue recession
Surgery	Predicable soft and hard tissue contour after healing	Difficult to predict where tissue will heal and stabilize
Tooth extraction	Minimal ridge atrophy	Ridge resorption in the apical and lingual direction

The normal discrepancy is 4 mm between the interproximal gingival peaks (most coronal) and the mid-facial free gingival margin peaks (most apical). When this discrepancy is <4 mm, a flat scallop is evident, while a >4 mm discrepancy results in an exaggerated or high scallop. With a shallow scallop, the interproximal bone is thin, and the interproximal gingival contour nearly parallel to the underlying bone contour. The flat bioform is advantageous for implant therapy since the bone has a congruous relationship with the free gingival margin (FGM) and is less prone to postsurgical recession. With a pronounced or high scallop, the interproximal bone is wider, but the disparity between the bone contour and the FGM is problematic for favorable esthetics (due to possible recession and creation of ‘black triangles’) following implant or restorative procedures [1].

Tooth Morphology

Tooth morphology determines two aspects of gingival undulations.

- The basic tooth forms
- Convex acuity of a tooth circumference.

The basic tooth forms - circular, square or triangular, determine the degree of gingival scallop. Circular (oval) or square teeth produce a shallower gingival scallop, while triangular teeth form the opposite, a pronounced scallop, predisposes to the so-called ‘black triangles’; especially with a thin biotype which has a propensity for recession. Furthermore, triangular teeth have divergent roots with thicker interproximal bone, resulting in reduced vertical bone loss compared with square teeth, whose root proximity and thinner interdental bone have a higher incidence of vertical bone resorption.

Tissue Biotype in Prosthodontic Treatment

Tooth preparation: Margins of the preparation have to be placed supragingivally in thin biotypes. If margins are placed subgingivally for porcelain fused to metal restoration grayish discoloration of the margin is seen because of translucency of thin biotype, which leads to esthetic failure. Whereas in thick biotypes margins can be placed subgingivally in esthetic zones.

Over contoured restorations will lead to gingival recession in thin biotypes. Pocket formation is seen in thick biotype.

Gingival retraction: Care to be taken to avoid injury to the soft tissue in thin biotypes. Thin retraction cord is used for retraction. If cord is retained more than 15 minutes, chances of recession are more. Retraction of gingiva can be accomplished more comfortably in thick biotype.

Tissue biotype in implant treatment planning: The thick and thin biotypes have different osseous and soft tissue forms and these distinctions would significantly influence implant site preparation and treatment planning. The stability of the osseous crest and soft tissue is directly proportional to the thickness of the bone and gingival tissue. Thick biotypes are associated with thick bony plates and thin biotypes are associated with thin bony plates, with potential for fenestrations and dehiscence and respond differently to extraction and have a different pattern of osseous remodeling following implant placement. Proper care should be taken during extraction in thin biotype cases to prevent labial plate fracture. During postoperative healing phase, more dramatic alveolar resorption is seen in apical and lingual direction for the ridge associated with thin biotype. When these tissue biotypes are carefully considered, various periodontal and surgical strategies can be employed to improve the treatment outcome either by

minimizing alveolar resorption or by providing a better tissue environment for implant placement.

Ridge Preservation in Thick vs Thin Biotypes

Prevention of postextraction alveolar bone loss is critical in assuring implant success. Thin periodontal biotype is associated with thin alveolar plate, so it is usual to see more ridge remodeling when compared with thick periodontal biotype which is associated with thick alveolar plate.

In thin biotypes, it's not only a traumatic extraction is critical in ridge preservation, it is important to consider strategies to preserve the alveolar bone such as socket preservation or ridge preservation procedures [1, 8].

This loss can be 1.5–2.0 mm over the first 12 months with most loss occurring during the initial 3 months. A variety of approaches can be employed to address this problem, but most involve grafting the extraction socket and using membranes to support missing/perforated bony walls. Ridge preservation should be considered for most thin biotype cases.

Classically, socket or ridge preservation involves the use of a graft material placed in the socket followed by a variety of other substances such as demineralized freeze-dried bone allograft, mineralized freeze-dried bone allograft, xenograft (mostly of bovine source), and alloplastic materials (β -tricalcium phosphate, durapatite, hydroxyapatite).

The ridge preservation strategy is only successful if the graft material is retained in the extraction socket. A variety of approaches can be utilized to achieve socket closure. These include the use of barrier membranes, tenting pins, collagen plugs, connective tissue grafts, free gingival grafts, acellular dermal grafts, and advancement of the buccal flap.

When excessive bone is lost to resorption, leaving a narrow ridge with a large buccal deficiency or decreased vertical height, a block graft is generally the technique that yields predictable results. The block graft material can be of autologous or allograft origin. Autologous graft material is commonly harvested from either the mandibular ramus or mandibular symphysis. Allograft block grafts can be obtained from several commercial providers. The advantage of this technique is that the graft is placed as a block instead of in particulate form, providing increased structural support [1].

Immediate Implants in Thick vs Thin Biotypes

For a thin biotype case, practitioners must be aware of the

possibility of significant resorption, which may have an impact on esthetics. Furthermore, the loss of peri-implant structures may result in thin, translucent tissue over the implant, which appears grayish, especially if the facial plate is lost and implant threads are exposed. In these cases, further bone and soft tissue grafting procedures may be necessary. However, once an implant is in place, it may be difficult to regain pre-extraction tissue contours. In a thick biotype environment, immediate placement of an implant can be completed with predictable results.

Conclusion

Evaluation of gingival tissue biotypes is important in treatment planning. Since thick and thin gingival biotypes are associated with thick and thin osseous patterns, the two tissue types respond differently to the inflammation and trauma and have different patterns of osseous remodeling following the extraction or implant procedure. In fixed prosthodontics, care to be taken in finish line placement and retraction and type of restoration selection in esthetic zone.

By understanding the nature of the tissue biotype, the practitioner can employ appropriate periodontal and surgical procedures to minimize alveolar resorption and provide a more favorable environment for implant placement.

References

1. Ahmad (2005) Anterior dental esthetics: Gingival perspective *Br Dent J* 199(4):195–202
2. Sanavi F, Weisgold AS, Rose LF (1998) Biologic width and its relation to periodontal biotypes. *J Esthet Dent* 10:157–163
3. Garguilo AW, Wentz FM, Orban B (1961) Dimensions and relations of the dentogingival junction in humans. *J Periodontol* 32:321
4. RR Cluade. *Fundamentals of Esthetics*. Lombard, Illinois: Quintessence Publishing Co, Inc; 1990
5. Goldstein RE. 3rd Ed. *Change your smile*. Carol Stream, Illinois: Quintessence Publishing Co, Inc; 1997
6. Richard TK, Mark C, Gregory JC (2008) Thick vs. Thin Gingival Biotypes: A Key Determinant in Treatment Planning for Dental Implants *CDA J* 36(3):193–198
7. Kao RT, Pasquinelli K (2002) Thick vs. thin gingival tissue: a key determinant in tissue response to disease and restorative treatment. *J Calif Dent Assoc* 30(7):521–526
8. Atwood DA (1963) Post extraction changes in the adult mandible as illustrated by microradiographs and mid-sagittal section and serial cephalometric roentgenographs. *J Prosthet Dent* 13:810–816