

Crowns to Create Esthetics for Mal-Aligned Central Incisors: A Case Report

Ravindra C. Savadi · Anupama R. Savadi ·
Preeti Satheesh Kumar

Received: 23 April 2011 / Accepted: 27 May 2011 / Published online: 10 June 2011
© Indian Prosthodontic Society 2011

Abstract This case report describes the smile design of crowded upper central anteriors in a female patient aged 25 years. The patient wanted the correction to be completed in a short period of time. A smile design schedule was drawn up involving root canal treatment of the central incisors and placing posts in both the teeth. All ceramic crowns were then fabricated to establish a very satisfactory and pleasing esthetics.

Keywords Golden proportion · Esthetics · Glass fiber posts · All ceramic crowns

Introduction

The smile constitutes an important component in the presentation of a human being. A non harmonic smile decreases the beauty of the face and it can cause discomfort in the social setting, as it is one of the most important facial expressions that demonstrates friendship, pleasant sensation and appreciation [1].

Dento-facial attractiveness is particularly important to a person's psycho-social well being. People with a normal dental appearance are judged more socially attractive over many personal characteristics than those

with malocclusions [2, 3]. Mal-alignment of teeth not only causes difficulty in maintenance of oral hygiene but also affects the esthetics. Authors [4] have noted that most young adults are more concerned about the appearance of their anterior teeth than their occlusion. Thus it is not surprising that the general public considers smile the second most important feature of the face after the eyes when judging facial esthetics [1].

Aesthetic improvement is most important for anterior teeth. The type of material used also has an important bearing on appearance and amount of preparation. They are an important part of esthetic cost to benefit equation [5]. Esthetic fixed partial dentures have evolved significantly in the last few decades. In a span of just 25–30 years, dentistry has gone from the use of conservative partial coverage metal retainers with cemented ceramic pontic facings to full coverage ceramometal restorations with ceramic margins. The excellent level of esthetics achievable with ceramometal FPDs combined with their predictable strength and proven longevity makes them the primary choice for most of the esthetic FPDs [6].

Case Report

The following case report describes the restorative management of a 25 year old female patient with mal-aligned central incisors.

A detailed history revealed that the patient was reluctant to smile and conscious about her mal-aligned teeth. On clinical examination, it was found that the maxillary teeth position created both esthetic and functional difficulty. Both the maxillary central incisors had a mesio-labial rotation. Crowding in the central incisors itself suggested lack of arch space for alignment of teeth.

R. C. Savadi · P. S. Kumar
Department of Prosthodontics, Oxford Dental College
and Research Center, Bangalore, India

A. R. Savadi (✉)
Department of Orthodontics, Oxford Dental College
and Research Center, Bangalore, India
e-mail: anusavadi@gmail.com

Treatment Plan

Several treatment plans were proposed to the patient for esthetic correction. A problem list related to the dentofacial problems enlisting individual solutions for individual problems and the impact on the overall outcome was explained to the patient. Orthodontic alignment of the teeth was suggested. The time involved in the procedure dissuaded the patient from accepting the proposed plan. The type of restorations, restorative materials, esthetic expectations, complications, limitations and oral hygiene requirements were discussed. The patient provided her consent as this option met the stated objectives. (Fig. 1)

The diagnostic wax up was completed on a set of mounted diagnostic casts to establish the desired esthetics, occlusal plane, tooth contour and positioning for final restoration. Crown preparation and crown placement on the maxillary central incisors would not have been sufficient as there was insufficient space combined with crowding. To achieve optimal tooth esthetics, it was essential to mimic the optical effects of the pulp, the orange color of the dentin adjacent to the pulp, and the light-scattering effect of the enamel prisms. Hence the maxillary central incisors were subjected to endodontic treatment. It is important to reinforce the endodontically treated tooth and protect it against vertical fracture. To achieve this, some type of stabilization was required that will fasten the restoration to the remaining tooth structure which was obtained from the post. Metal or carbon fibre dowels and amalgam placed in the canal can result in unacceptable gingival discoloration from the underlying root. This adversely affects the natural appearance of the restored tooth. To overcome this disadvantage tooth colored posts were used. Parapost Fibre White (Coltene, Whaledent) was selected as the post material. Similarly, tooth coloured, rather than opaque, composite core material should be selected for esthetics. Hence paracore material was used.

One of the critical aspects of esthetic dentistry is creating geometric or mathematical proportions to relate the successive widths of the anterior teeth. The most harmonious recurrent tooth-to-tooth ratio was found in the golden

Fig. 1 Pre-treatment photographs: occlusal (*left*) and frontal (*right*) view of the crowded maxillary central incisors

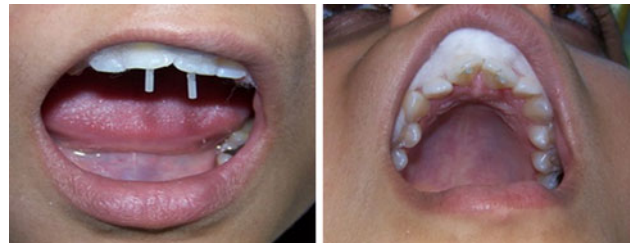
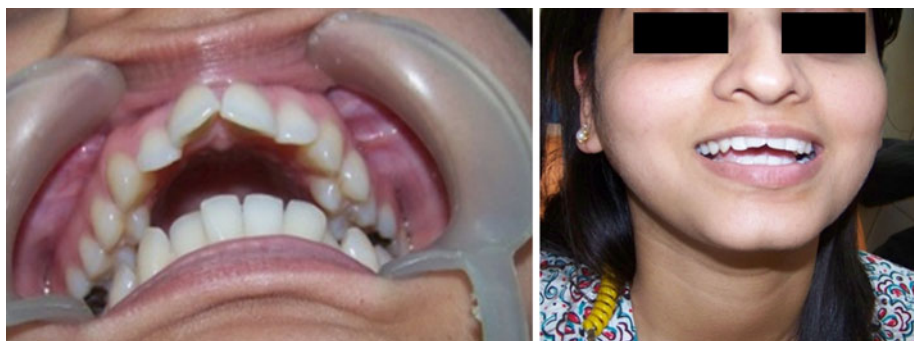
Fig. 2 Frontal (*left*) and occlusal (*right*) view of the placement of the glass fiber posts in the maxillary central incisors

proportion [7]. This implies that the maxillary central incisor should be approximately 60% wider than the lateral incisor, which in turn should be 60% wider than the mesial aspect of the canine, the distal aspect of the canine being obscured from the facial aspect. Further the lateral negative space, the area that appears between the anterior segment of the teeth and the corner of the mouth on smiling, should be in golden proportion to one half the width of this anterior segment. A grid was developed to help detect what is esthetically wrong in the anterior proportional relationship.

Tooth preparations were completed on the maxillary anterior teeth. Mandibular and maxillary impressions were made using vinyl polysiloxane impression material (Express, 3M ESPE; St. Paul, MN). Lithium disilicate (LS2) (E-max 2) Crowns were fabricated and cemented with a resin cement (RelyX™U 100,3 M EspE, St Paul, MN) of appropriate shade. (Figs. 2, 3).

Discussion

The perception of beauty as a corporal expression can vary from one individual to another, one civilization to another and from one ethnic group to another. Human beauty being a subjective factor changes the treatment modules of similar problems from one patient to another thus disallowing a standardization of the treatment plans.

Orthodontic treatment though advised, with the help of proximal slicing, was not accepted by the patient since it

involved a longer duration of time. Also, retention of the orthodontic treatment was a problem for the patient since the appliance was to be worn for a longer period of time.

Treatment sequencing, an integral part of treatment planning was done. A phase-wise distribution of treatment procedures, which was charted considering periods of healing, patient convenience and interdisciplinary treatment modalities was formulated. If this tooth is to be covered with a restoration for realignment and cosmetics without orthodontic treatment, sufficient tooth structure must be removed to allow not only for porcelain, but also for the realignment. Hence prophylactic endodontic therapy was necessary. Therefore the maxillary anteriors were endodontically treated to avoid pulpal exposure.

An intact endodontically treated tooth requires critical control of endodontic materials in the coronal third of the canal and pulp chamber in order to maintain its color and translucency. The obvious choice was esthetic posts because of their increased translucency and compatible strength. Glass fiber posts allow fabrication of highly esthetic restoration that contains no metal substructure. These restorations have remarkable depth of life-like colour vitality, with no unnatural opacity, shadows, grey discoloration, or artificial brightness from underlying metal or masking agents. Parapost Fibre White (Coltene, Whaledent) post was used, which has longitudinally arranged glass fibres. The post is essentially parallel with small steps to aid mechanical retention of the cement. The head of the post has two rounded sections to aid in retention of the core material. It is compatible with existing Parapost system in shape and is available in diameters of 1.14, 1.25, 1.4 and 1.5 mm. Each post has a removable colour coded ring around the head for identification. The core was anchored to the tooth by extending into the coronal aspect of the canal through the glass fiber post.

The two main objectives in Dental Esthetics are to create teeth of pleasing inherent proportions and of pleasing proportions to one another and to create a pleasing tooth arrangement in harmony with the gingiva, lips and face of the patient.

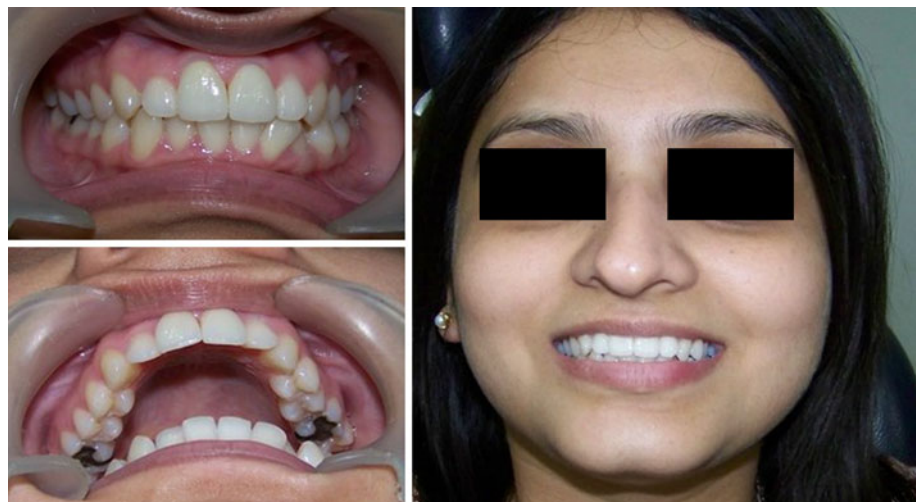
Esthetics is quite an empiric subject and harmony is not always a mathematical issue. The traces of the face and of the smile are valid just as guidelines for esthetic reconstruction, but the individual characteristic of each patient should be taken into consideration. According to Dierkes [8], the beauty of the face can be broken down into horizontal, vertical, and transverse components, and all of these must harmonize with the contours of the face to produce a beautiful smile. Hence the golden proportion was used to correct the smile.

Successful esthetic and functional results obtained with all porcelain crowns cannot be credited solely to the quality of the particular material used. There are now a bewildering number of porcelain systems on the market which are strong, aesthetic and suitable for multiple applications, including crowns and bridges. E-max, a functionally durable material was chosen as the material for fabrication of the all ceramic crowns. The E-max framework becomes more translucent during the fabrication process and complements the underlying tooth structure as soon as it is in the mouth. Additionally, the framework itself has an incredibly polishable surface and high wear compatibility with the opposing natural teeth.

Conclusion

An organized and systematic approach is required to evaluate, diagnose and resolve esthetic problems predictably. The treatment sequence may change during the

Fig. 3 Post treatment photographs: Intra-oral frontal (left upper), intra-oral occlusal (left lower) and the smile photograph on the right side, after the placement of the all ceramic crowns on the maxillary central incisors



treatment, as some conditions may need to be reviewed or certain additional procedures may become necessary to get the desired result. The practitioner must strive to merge function and beauty with the values and needs of each individual patient.

Ultimately a well designed smile is a product of consolidated efforts accomplished by accurate diagnosis, methodical treatment planning, use of advanced materials and contemporary techniques rendered by the dentist.

References

1. Simon J (2004) Using the golden proportion in aesthetic treatment: a case report. *Dent Today* 23:82, 84
2. Anderson KM, Behrents RG, Mckinney T, Buschang PH (2005) Tooth shape preferences in an esthetic smile. *Am J Orthod Dentofac Orthop* 128:458–465
3. Shaw WC, Rees G, Dawe M, Charles CR (1985) The influence of dentofacial appearance on social attractiveness of young adults. *Am J Orthod* 87:241–243
4. Espeland LV, Stenvik A (1991) Perception of personal dental appearance in young adults: relationship between occlusion, awareness, and satisfaction. *Am J Orthod Dentofac Orthop* 100:234–241
5. Steele NJG, Wassell RG (2002) Crowns and extra-coronal restoration: esthetic control. *BDJ* 192:443–450
6. Crispin BJ (1994) *Contemporary esthetic dentistry: practice fundamentals*, 1st edn. Quintessence, Tokyo
7. Fayyad M, Jamani KD (2006) Geometric and mathematical proportions and their relations to maxillary anterior teeth. *J Contemp Dent Pract* 7(5)
8. Dierkes JM (1987) The beauty of the face: an orthodontic perspective. *J Am Dent Assoc* 89E–95E