

# Designing a Custom Made Gauge Device for Application in the Access Hole Correction in the Dental Implant Surgical Guide

Elnaz Moslehifard · Saeid Nokar

Received: 1 January 2011 / Accepted: 6 September 2011 / Published online: 16 October 2011  
© Indian Prosthodontic Society 2011

**Abstract** Anatomic limitation and restorative demands encourage the surgeon to gain precision in planning and surgical positioning of dental implants. Ideal placement facilitates the establishment of favorable forces on the implants and the prosthetic component as well as ensures an esthetic outcome. The predictability of success can be increased, if the implants are placed properly. During oral implant placement, the drill must be guided by the surgeon according to the final form of the restoration. A surgical template would be helpful in more accurate placement of the dental implants. Surgical guides fabricated in laboratory are still being used. But these guides often need correction after computed tomography (CT) scan evaluation. For their correction and reducing the possibility of error, a scaled milling machine is usually required. But this scaled milling machine is not available omnipresent. In this article a simple device is described that can be attached to any milling machine and surveyor. The presented device can correct the diagnostic template easily and predicts dental implants placement with more favorable esthetic and occlusal outcome.

**Keywords** Computed tomography · Dental implants · Surgical templates

## Introduction

The success of implant therapy depends primarily on appropriate treatment planning and properly performed implant placement surgery [1]. A close collaboration with the prosthodontic members of the team will facilitate the preparation of the surgical stent or surgical guide. A surgical and prosthetic combined procedure has been developed to provide optimum results by taking full advantage of capabilities of each clinician including the surgeon and the prosthodontist [2]. Planning the prosthodontic phase will make the success of the treatment more predictable because it will provide the surgeon a guide for the establishment of the optimal position and inclination of the implants. The use of surgical templates or guides for correct implant placement can be a criterion for success. The surgical template dictates the implant body placement to the surgeon, offering the best combination of (1) support for the repetitive forces of occlusion, (2) esthetic, and (3) hygiene requirements. Furthermore, a little decision making stage will be needed at the time of surgery [3]. Surgical templates are recommended for an accurate placement of implant on the surgical site, although both the final restorative prosthesis (i.e., the bio-mechanical and aesthetic requirements) and the internal anatomy (i.e., bone volume and position of vital structure) should be taken into account [4].

Generally, the surgical guide fabrication process begins with a diagnostic tooth positioning, either through a diagnostic waxing denture teeth arrangement or via the duplication of the preexisting dentition or restoration [5]. Fabrication techniques may vary in the manner of transferring such diagnostic information to the surgical guide and its application during the surgery. Surgical guides may be categorized based on the material used and amount of surgical restriction. Clear vacuum-formed matrices, with or

---

E. Moslehifard (✉)  
School of Dentistry, Tabriz University of Medical Sciences,  
Tabriz, Iran  
e-mail: elnaz\_moslehi@yahoo.com

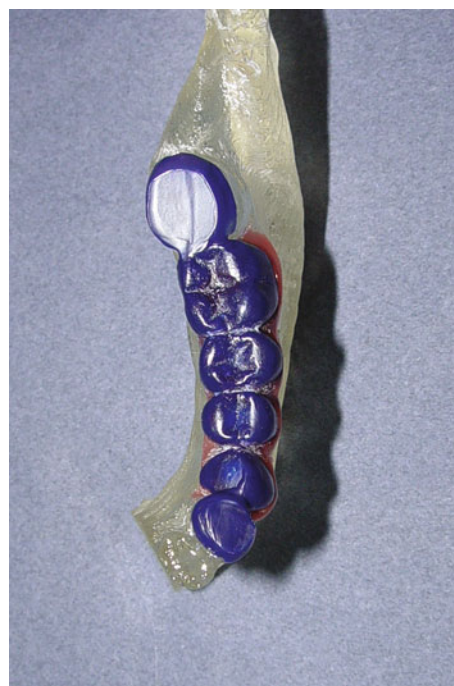S. Nokar  
School of Dentistry, Tehran University of Medical Sciences,  
Tehran, Iran

without using autopolymerized acrylic resin, and gutta-percha or metal rods for contrast and radiographic assessment, have been used in the past. Acrylic resin has also been widely used for the fabrication of surgical guides [6]. A barium sulfate-based radiopaque material enables the visualization of the essential elements required for implant planning, directly from the radiographs [7]. To indicate screw-access channels, holes with a diameter of 2 mm should be drilled in the cingulum area of the anterior teeth and central fossa of the posterior area so that the channels do not interfere with the interproximal papillae or the opposing dentition. After fabricating the surgical template, the clinician will drill pilot holes or grooves to indicate implant positions or planned osteotomies, respectively; in the template [8]. These stents dictate the implant's position and angle during the surgery. These stents can combine with computerized tomography (CT) scans to increase the accuracy of the stent. The use of cross-sectional images in the bucco-lingual direction, which can be delivered by computed tomography (CT), allows us to plan a more accurate design of implant placement before the surgery [9]. Radiographic templates that are then modified for surgical purposes have the advantage of transferring the radiographic information to the surgical guide. For this purpose, a radiopaque contrast medium should be applied to the template and after CT scan the buccolingual images should be accessed to determine the modification achieved in the template, making it possible to localize anatomical structures and determine precisely the amount of bone available at prospective implant sites. After analyzing the CT scan data, the implant's access hole in the stent should be corrected. Some devices are available for correction. Some milling machines are scaled and the table tilt can be changed according to the correction needed and then implants hole can be corrected. For some cases in that the milling machines are not scaled, the guide should be corrected with other methods to predict the implants position. This article describes a simple gauge to correct the stent. This custom made gauge can be attached to any milling machine and any dental surveyor. By the application of this gauge, there will be no need to any scaled milling machine as an instrumental limitation. Consequently, the modification of stent for the surgical procedures is accomplished. In this article a model is used to present the cast and procedure for simplicity.

### Technique

1. Pour complete arch impressions in type III dental stones. Mount the casts on the semi adjustable articulator using a face bow transfer and either a centric relation or maximum intercuspation record.


2. Determine the potential implant recipient sites and complete an accurate diagnostic wax up. The tooth set-up should reflect the final expected results in terms of lip support, occlusion, phonetics, etc. Both the prosthodontist and the implant surgeon should contribute towards making this decision during the whole process. Expand the wax over adjacent teeth to create occlusal wing to support the surgical guide and increase its stability during surgery (Fig. 1).
3. Make an impression of the wax up using silicone putty impression material or muffle the wax up. Wash out the wax by dissolving it in hot water.
4. Apply separating fluid over the edentulous area using a brush.
5. Fill the entire tooth volume with a clear autopolymerized methyl–metacrylate resin mixture. Put the silicone mold over the plaster model and fix it into an appropriate place with elastic bands or insert the cap of the muffle and process the heat cure clear resin (Clear Acron Clear, GC, Corp).
6. When the resin is completely hardened, take it out from the mold. Carefully trim the excess from the cervical contours of the teeth.
7. Polish and finish the surgical guide to improve the appearance to meet the patient's demands. Help the patient try the guide and prove the stability. For any problems of adaptation or stability in patient's mouth, the surgical guide can be relined. Stability



**Fig. 1** Completed diagnostic wax up

is essential at this step. Because the patient must be confident in wearing the guide during the CT scan procedure. The correct fit will guarantee that proper data is transferred into the scan images.

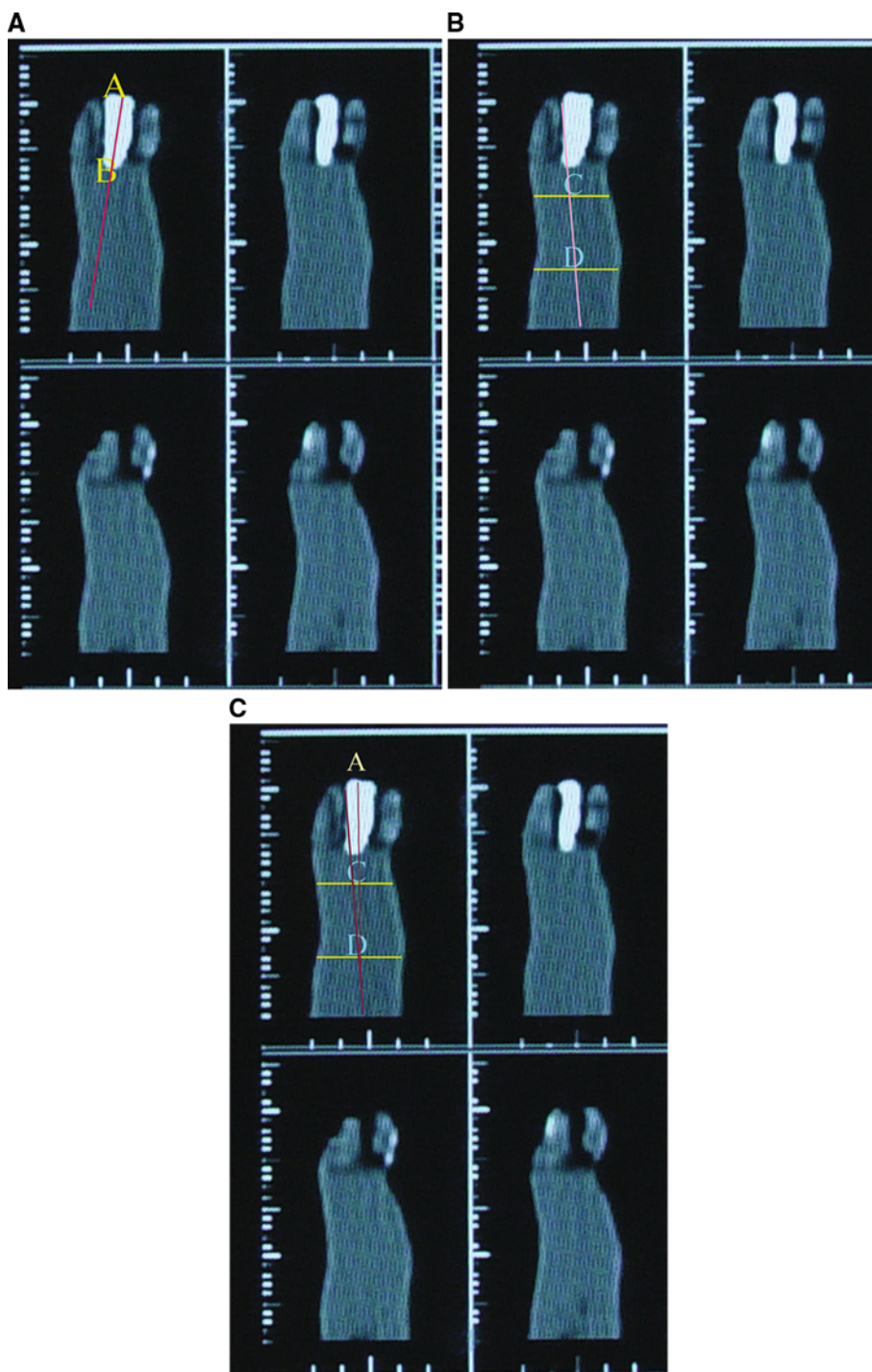
8. Place the cast on the surveying table. The panoramic view should be used to estimate mesiodistal angulations of adjacent teeth and tilt the surveying table to find the appropriate angulation of the implant in accordance with the anticipated bone angulation. Use the selected implant system drills (pilot and twist drills) and drill the holes from the center of the occlusal surface of posterior teeth and cingulum of anterior teeth down to the base, following the long axis of each tooth. At this stage a pin hole for each implant site should be made. Since the implants may not be parallel to each other guiding marks are placed for each implant site to enable the holes be in better parallel position. Then, tripod the cast (Fig. 2).
9. After drilling the stent, coat the template with a barium sulfate liquid (barium sulfate, Daroupakhsh Co, Teh, Iran) to produce a thin, uniform layer. Alternatively, a mixture of 10% barium sulfate to 90% acrylic resin can be used to fabricate the teeth which eliminates the need for coating with the barium liquid.



**Fig. 2** The holes were drilled from the center of the occlusal surface of posterior teeth and cingulum of anterior teeth down to the base, and guiding marks were placed for each implant site to enable further paralleling the holes

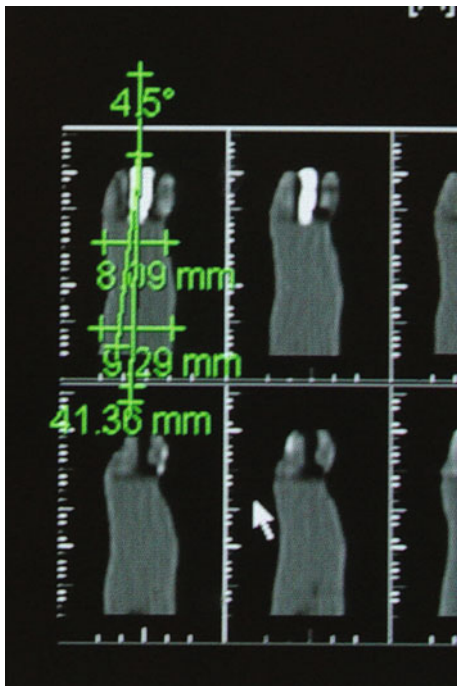
10. Instruct the patient how to position the template in the mouth and how to stabilize the guide by biting on 2 cotton rolls or on a bite template.
11. Perform the CT scans at 1.5 mm slices in the maxilla and 1 mm intervals for the mandible. Reformatted computerized images are obtained in both panoramic and cross sectional planes. The Reformatted radiographs provide profile images of diagnostically waxed teeth in axial, cross sectional, and panoramic views.
12. Perform radiographical analyses on the implant sites. Define the optimal final tooth position (axial center) by locating the center of the optimal final tooth position in the axial view. This line indicates the mesiodistal center of the proposed implant sites [10].
13. Determine the buccolingual center of the computer profile image. Point A is the incisal edge of anterior teeth or central fossa of posterior teeth. Point B is the buccolingual center of the computer profile image at its cervix. Point C is the widest coronal of the one third of the alveolar ridge. Point D is the buccolingual center of the residual ridge. Point A provides the most optimal screw access hole location. AD is derived as the implant compatible line to find the deviation in degrees between AB and AD lines which should be compensated in the stent in buccolingual direction. This procedure is shown in Fig. 3a, b and c in which AB and AD lines are plotted on the actual images of CT scans. This will provide the necessary information for proper buccolingual placement and will provide proper emergence profile [10]. In Fig. 4, one practiced example is shown. The degree of correction of 4.5 degrees needed was determined in the first premolar CT scan image.
14. After calculating the correction angle, place the template and the cast on the surveyor and realign the table according previous references and attach the device to the surveyor. This custom made gauge composes of a scaled plate and two parallel bars. These bars can be inserted in any milling machine and surveyor. One of these bars is fixed to the plate and the second bar is attached to the device with a hinge which can be rotated on the plate. Degree of rotation is monitored and controlled on the scaled plate. A horizontal bar is attached to the fixed bar in right angle. When this horizontal bar is aligned with the central fossa, the plate is adjusted in accordance with buccolingual direction (Fig. 5). For correcting the implant path, adjust the table in the previous position that the holes were drilled. While the horizontal bar is aligned with the central fossa, insert a bar perpendicularly in the milling machine (Fig. 6). This position indicates the first drilling position.

**Fig. 3** Degree between AB and AD was determined on the CT scan image. This degree represented the correction needed in the stent



According to the angular correction determined during CT analysis, rotate the second bar and insert it in the milling machine (Fig. 7). Then, rotate the table until fixed bar stands over the hole and consequently is inserted. In this position lock the table and then attach the headpiece to the milling machine and correct the implant access hole.

15. Fill the unfilled portion of the hole (the first drilling hole) with clear auto polymerizing acrylic resin (Great Lakes Splint Resin Acrylic #040-008, Great Lakes Orthodontic) and then simply correct the implant access hole. By this mean, there is no need to use of complex milling machine. In the other hand, a simple surveyor can solely be used.




**Fig. 4** 4.5 Degrees correction was needed in the first premolar CT scan image

16. After correction, insert stainless steel tubes with the same diameter of the drill into the stent and by removal of the adherent barium sulfate, convert the diagnostic template to a surgical guide and place the template in disinfectant solution before the surgery for disinfection.

## Discussion

The location of implant placement is often critical in the success or failure of a particular restoration. Implants placed in the interproximal areas of the superstructure may cause oral maintenance issues, while implants overangulated towards the labial can lead to either esthetic disharmony due to the developed location of the opening for screw access on the facial surface of the prosthesis or its complete removal. Implants, placed very lingually relative to the superstructure, usually result in a bulky prosthesis with an unfavorable palatal contour and may also interfere with speech.

The need for more accurate placement of implants has led to the development of numerous template designs, including the labial outline surgical guide made from a wax arrangement of the proposed definitive restoration, a clear vacuum-formed matrix, a duplicate of the existing restoration, and other methods. The clear vacuum-formed surgical guide with a guide hole made over the anticipated



**Fig. 5** The gauge composes of a scaled plate and two parallel bars. These bars can be inserted in the surveyor

implant position does not prevent deviation of the angle of placement. Significant inaccuracies due to the absence of a guiding channel may occur at the apical portion of the pilot or twist drills close to the edentulous residual ridge.

Parel and Funk described a surgical guide with the buccal contours of the proposed implant-supported restoration created in the guide [11]. This type of surgical guide may not serve as a direct mechanical guide and site preparation may be performed freehand.

Engleman et al. [12] described a similar surgical guide. This design may not provide accurate spatial information for an implant. Ku and Shen [13] demonstrated a surgical guide fabricated with a vacuum-formed matrix filled with clear acrylic resin. In this technique, the guide channel was prepared by drilling through the clear acrylic resin using carbide burs with the same diameter as the pilot drill. This technique only allows for correct initial positioning and does not allow for correct inclination at implant placement because the implant cannot be placed with the guide after the initial preparation due to insufficient diameter for the larger pilot drill or twist drill to pass through the channel prepared within the guide.

Jeffry et al. used a light-polymerized composite material and drill blanks placed in the prosthodontically driven implant position. Surgical guides for each implant drill were constructed on the diagnostic cast to be used for implant placement surgery. A series of templates was examined for implant insertion that complicated the hole process [1].

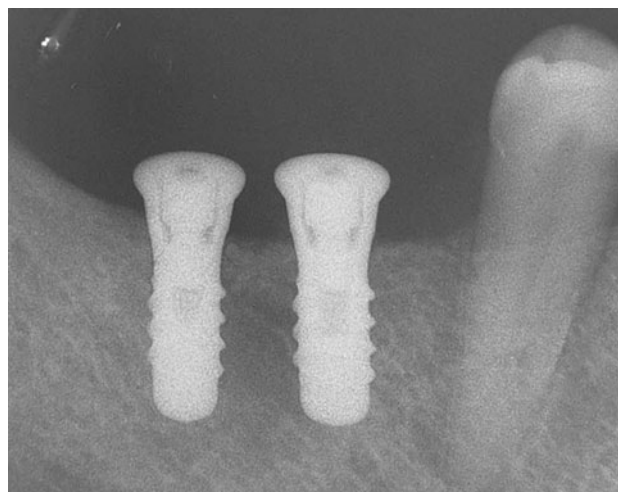


**Fig. 6** The horizontal bar was aligned with the central fossa, fixed perpendicular bar was inserted in the milling machine



**Fig. 7** The second bar was rotated and inserted it in the milling machine

The presented device can correct the diagnostic template easily and predicts implant placement with more favorable esthetic and occlusal outcome. The performance of this gauge was evaluated using periapical radiography of the posterior edentulous area as shown in Fig. 8. The



**Fig. 8** Periapical radiography of the posterior edentulous area after implant placement using the modified template achieved by the gauge

correction made on the angle of stent was ensured using this device.

This device has been frequently used in our practice in edentulous area to correct the access hole in template. The technique for this surgical guide is economical and simple, and the method can be used for a partially edentulous arch. In addition, this device can function as a radiographic guide. When the clear nature of the template is present it provides a good visualization of buccal contours during the implant placement. Other methods for fabrication of surgical guide in the literature require duplication of the diagnostic cast and some trimming of the cast [14, 15]. However, the technique presented here requires no cast duplication or trimming [16]. Advantages of this technique include its cost effectiveness and the use of equipment and materials commonly found in dental offices. During surgery, this removable surgical template offers flexibility without compromising access to the implant sites. Furthermore, there is no need to complex milling machine and the correction procedure can be done easily.

## Conclusion

Proper implant placement is crucial for successful implant-supported restorations. It was shown that a simple gauge can be successfully used for simple correction of the access hole in a surgical guide to assist in dental implant placement in edentulous regions. This custom made gauge can be attached to any milling machine and any dental surveyor. By the application of this gauge, there will be no need to any scaled milling machine as an instrumental limitation. Consequently, the modification of stent for the surgical procedures is accomplished. This technique is more convenient, economical, and less traumatic for the

patient. It can be used with any implant system and only minimal materials and components are required.

## References

1. Shotwell JL, Billy EJ, Wang H-L, Oh T-J (2005) Implant surgical guide fabrication for partially edentulous patients. *J Prosthet Dent* 93:294–297
2. Modica F, Fava C, Benech A, Preti G (1991) Radiologic prosthetic planning of the surgical phase of the treatment of edentulism by osseointegrated implants: an in vitro study. *J Prosthet Dent* 65:541–546
3. Misch CE (2005) *Dental implant prosthetics*. Elsevier, China
4. Fortin T, Champlébourg G, Lormée J, Coudert J (2000) Precise dental implant placement using surgical guides in conjunction with medical imaging techniques. *J Oral Implantol* 264:300–303
5. Neidlinger J, Lilien BA, Kalant DC Sr (1993) Surgical implant stent: a design modification and simplified fabrication technique. *J Prosthet Dent* 69:70–72
6. Park C, Raigrodski AJ, Rosen J, Spiekerman C, London RM (2009) Accuracy of implant placement using precision surgical guides with varying occlusogingival heights: an in vitro study. *J Prosthet Dent* 101:372–381
7. Wulfman C, Hadida A, Rignon-Bret C (2010) Radiographic and surgical guide fabrication for implant-retained mandibular overdenture. *J Prosthet Dent* 103:53–57
8. Zinner ID, Panno FV, Small SA, Landa LS (2004) *Implant dentistry: from failure to success*. Quintessence Publishing, Beijing
9. Naitoh M, Ariyi E, Okumura S, Ohsaki C, Kurita k, Ishigami T (2000) Can implants be correctly angulated based on surgical templates used for osseointegrated dental implants. *Clin Oral Impl Res* 11:409–414
10. Stephen LG, Rothman MD (1998) *Dental applications of computerized tomography*. Quintessence Publishing, Beijing
11. Parel SM, Funk JJ (1991) The use and fabrication of a self-retaining surgical guide for controlled implant placement: a technical note. *Int J Oral Maxillofac Implant* 6:207–210
12. Engleman MJ, Sorensen JA, Moy P (1988) Optimum placement of osseointegrated implants. *J Prosthet Dent* 59:467–473
13. Ku YC, Shen YF (2000) Fabrication of a radiographic and surgical stent for implants with a vacuum former. *J Prosthet Dent* 83:252–253
14. Akca K, Iplikcioglu H, Cehreli MC (2002) A surgical guide for accurate mesiodistal paralleling of implants in the posterior edentulous mandible. *J Prosthet Dent* 87:233–235
15. Tsuchida F, Hosoi T, Imanaka M, Kobayashi K (2004) A technique for making a diagnostic and surgical template. *J Prosthet Dent* 91:395–397
16. Atsu SS (2006) A surgical guide for dental implant placement in edentulous posterior regions. *J Prosthet Dent* 96:129–133