

Rehabilitation of Partial Maxillectomy Defect with Implant Retained Hollow Bulb Obturator Prosthesis: A Case Report

Anuj Chhabra · G. N. Anandakrishna ·
Girish Rao · Sumit Makkar

Received: 3 December 2010 / Accepted: 21 October 2011 / Published online: 4 November 2011
© Indian Prosthodontic Society 2011

Abstract Tissue integrated oral implants have initiated a new perspective in oral rehabilitation of tumor patients who have had undergone surgical resection procedure. The present case demonstrated a simple and predictable approach to rehabilitate a patient who had partial maxillectomy using dental implants. The use of an implant in conjunction with hollow bulb obturator shared remarkable improvement in retention and stability of the existing complete denture prosthesis.

Introduction

Surgical resection is a well established and common procedure employed for the treatment of maxillofacial carcinoma. Such surgical intervention usually involve partial or total removal of orbital, nasal, antral contents and jaws effecting speech, swallowing, mastication and facial topography.

The replacement of lost structures caused by ablative cancer surgery of maxillary region is never easy to achieve by reconstructive surgery especially after initial extensive and resective operation. Currently available maxillary reconstructive techniques include placement of a prosthetic obturator, local and regional flaps, and micro vascular free flaps [1–3]. The different reconstructive techniques have specific indications and advantages depending on the ablative defect, the medical status of the patient and the patient prognosis.

Obturator prosthesis is most frequently the choice of treatment because of the complexity of maxillary surgical reconstructions and the uncertainty of the functional outcome [4, 5]. Its primary role is to aid healing during the recovery period and to shorten long term convalescence and rehabilitation. It supports the soft tissues thus maintaining scar contracture, protects the wound from trauma and contamination with food debris, maintains skin grafts in position and prevents excessive formation of hematoma. Moreover, the prosthesis recreates a partition between the oral and nasal cavities; restores facial contour; improves mastication, articulation and speech intelligibility; and reduces drooping [3, 4].

Retention of the obturator is difficult because of enhanced weight of the prosthesis and poor border seal associated with it. Mechanical retention may be obtained by engaging tissue undercuts superior to the hard palate, but this is not always possible to accomplish without the use of a two piece obturator [6–8]. Such obturators are usually bulky and difficult for the patient inset and remove.

Introduction of the osseointegrated root form implant in 1983 by P-I Branemark to the dental profession expanded the treatment modalities for solving many clinic problems associated with partial or complete edentulism. Branemark defined osseointegration as “contact on the

A. Chhabra (✉)
Department of Prosthodontics, ITS Dental College,
Hospital & Research Centre, Greater Noida, UP
e-mail: i_ac80@yahoo.co.in

G. N. Anandakrishna
Department of Prosthodontics, M.S. Ramaiah Dental College
& Hospital, Bangalore, India

G. Rao
Department of Oral & Maxillofacial Surgery,
R.V. Dental College & Hospital, Bangalore, India

S. Makkar
Department of Prosthodontics, ITS Dental College & Hospital,
Ghaziabad, UP

light microscopic level between living bone tissue and implant” [9]. Because of the high predictability of success, osseointegrated dental implant systems have become viable treatment modalities for solving many problems traditionally associated with removable prosthesis [10, 11]. Implants may be used to support, stabilize and retain fixed or removable prosthesis and are extremely beneficial for the maintaining alveolar bone [12]. Prosthetic components like ball attachments can be placed on dental implants and the combination of Dalla bona type ball and socket attachment and maxillary obturator prosthesis has helped immensely in oral rehabilitation of this completely edentulous maxillectomy case.

The following clinical report describes the use of osseointegrated dental implant to provide retention for obturator prosthesis in a patient with a completely edentulous maxilla and unilateral partial defect of hard & soft plate. This prosthesis fabricated was more stable, retentive and easy to place.

Case Report

A 65 year old female patient reported to Mukha Implant Centre, Bangalore complaining unfit upper denture (Fig. 1). Her primary concerns were inability to chew food, nonretentive upper complete denture and the regurgitation of the food into the nasal cavity. The patient’s medical history revealed that she was diagnosed with the squamous cell carcinoma of left maxilla for which a unilateral maxillectomy was done followed by post surgical radiation therapy. Patient was not referred for presurgical

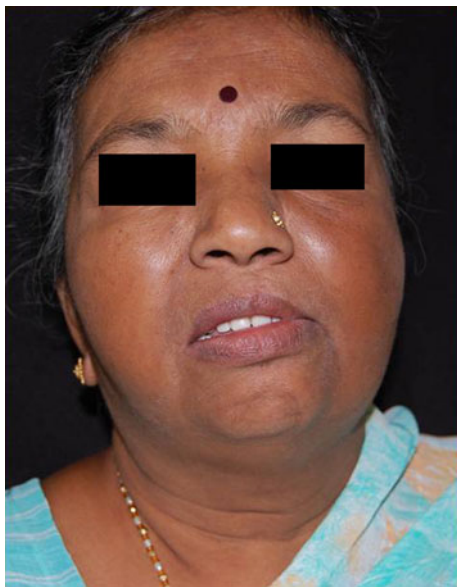

Fig. 1 Pretreatment photograph of the patient

prosthodontic evaluation so no surgical obturator was used post surgery. Patient managed nutritional intake orally without using a feeding tube and maintained body weight post surgery and presently she was managing with maxillary and mandibular complete denture constructed 1 year prior to tumor surgery.

On clinical examination it was revealed that middle and posterior portion of the left of the maxilla was completely resected in the edentulous mouth (Fig. 2). There was evidence of healthy mucosal graft on the lateral wall of the defect. No restriction was found in the range of movement of the soft palate and mandible. Speech was altered without the obturator. The patient indicated that the complete denture prosthesis which were fit before resection were not retentive and stable now though she was happy with the esthetics of the denture.

Treatment Plan

Considering the poor stability, retention but satisfactory esthetics of the existing complete denture, the decision was made to rehabilitate the patient’s existing complete denture with addition of hollow bulb obturator and two osseointegrated implants with ball attachments were used to assist with retention and stability of Obturator prosthesis.

Clinical Procedure

Surgical Phase

After the thorough radiographic evaluation and bone mapping procedure to assess the available bone, it was decided that the remaining bone structure in relation to 13 and 22 were adequate for the dental implants (Fig. 3). Two 2-Stage osseointegrated dental implants (Hi-Tec,

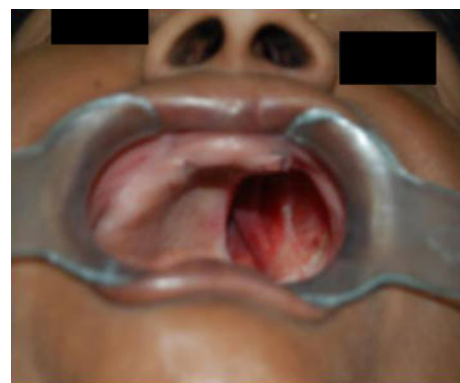

Fig. 2 Introral view of unilateral maxillectomy defect

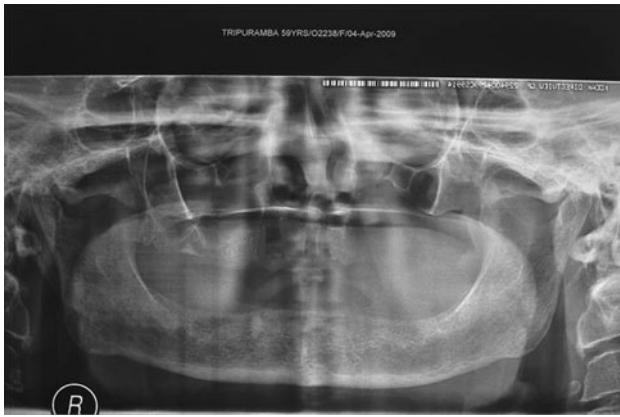

Fig. 3 Panoramic radiographic image showing maxillary defect on left side

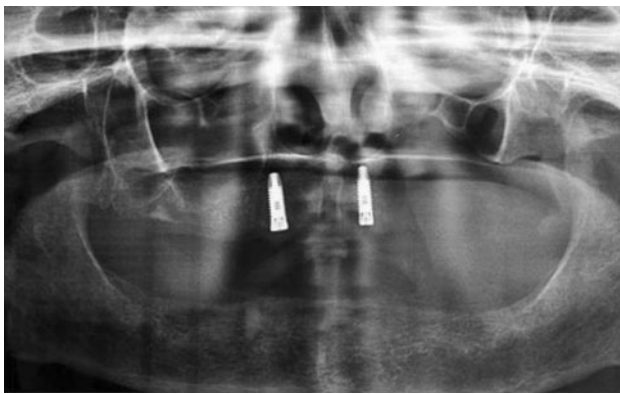


Fig. 4 Orthopantomograph showing the position of the two osseointegrated dental implants

Life Care, Israel) were placed in maxilla: diameter of 4.2 mm and length of 13 mm in relation to 13 and diameter of 3.3 and length of 13 mm in relation to 22. The two implants were then covered with cover screw (Fig. 4).

Prosthetic Phase

1. Following a 6 month healing period, the implants were exposed for prosthetic rehabilitation and healing abutments were placed for another 2 weeks period.
2. The next challenge was to add bulb portion of the obturator on the existing denture (Fig. 5). To enable this, warm water softened modeling wax (Dental Products of India Ltd) was incrementally added on tissue surface of maxillary denture corresponding to the left maxillary defect area (Fig. 6) and the denture was then placed in the oral cavity to record the defect portion of maxilla (Fig. 7).
3. The medial surface of the wax record was not kept as high as the lateral surface and the anterior aspect was kept higher than posterior aspect in order to encourage mucous drainage in a medial and posterior

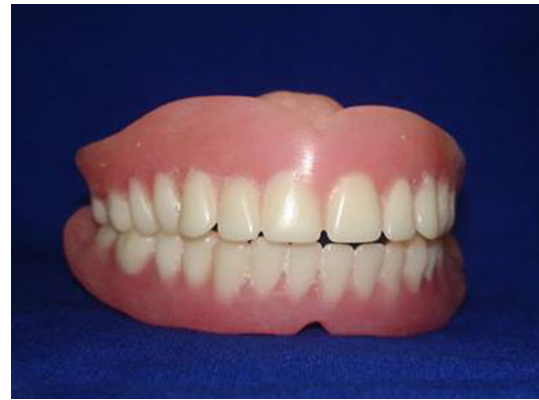

Fig. 5 Patient's existing denture

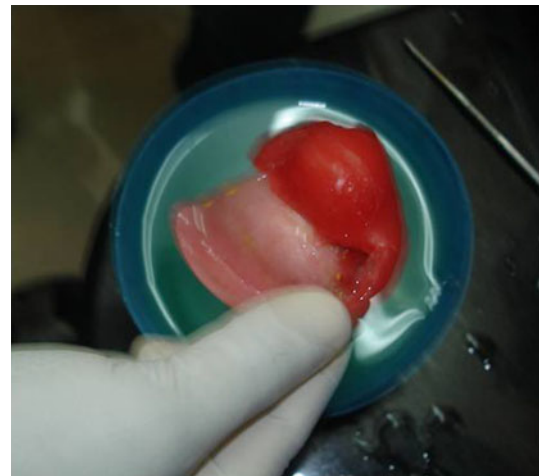

Fig. 6 Incrementally contouring softened wax on the tissue surface of maxillary denture

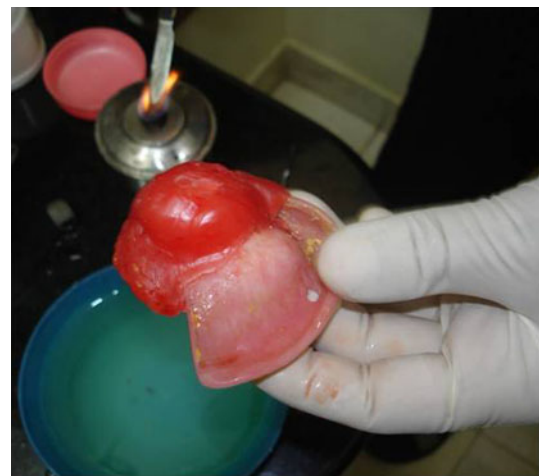

Fig. 7 Recorded adequate extension of maxillary defect area in the mouth

direction into her nasopharynx. The anterior and labial surface were extended superiorly to enhance

retention by minimizing vertical displacement and to support the facial musculatures.

4. Universal tray adhesive (Zhermack, Italy) was then applied on the tissue surface of maxillary denture bearing area. A Closed mouth and functional impression was then made of the resected and non-resected maxillary foundation utilizing addition silicone medium body (Elite HD, Zhermack, Italy) loaded on the tissue surface foundation of the maxillary denture (Fig. 8).
5. The impression was made with patient's head in lateral, upward and downward positions. The impression included hard and soft tissue of the posterior and lateral pharyngeal walls in their static and active states.
6. The master cast was then poured in dental stone and existing maxillary denture was processed (Fig. 9) and relined using chalian technique [13] to obtain a hollow bulb obturator and inserted in the patient's mouth to check adaptability.
7. Once the obturator was properly inserted and checked for adaptability, placement of the ball attachment was considered.
8. Healing abutments were replaced with ball attachments (Dalla Bona) (Fig. 10 and Fig. 11). The locations of the ball attachment were transferred to the obturator prosthesis for fixation of the female component with the help of the indicator paste. The prosthesis was fully relieved at that point.
9. The retentive component (Metal housing) was placed onto the ball attachment and the acrylised obturator prosthesis was checked for adequate space for the retentive component to be transferred to the prosthesis (Fig. 12).

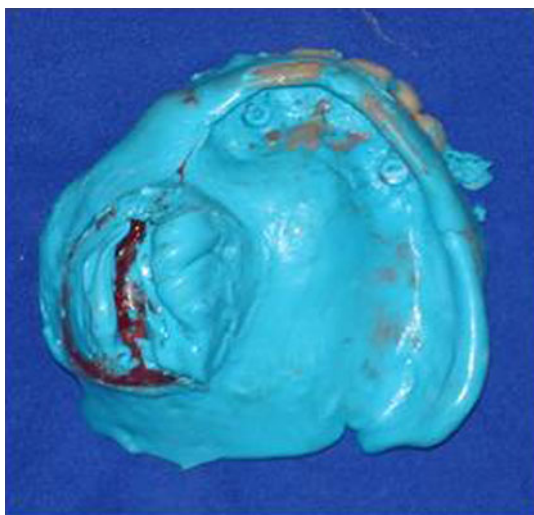


Fig. 8 Closed mouth final impression of entire maxillary foundation

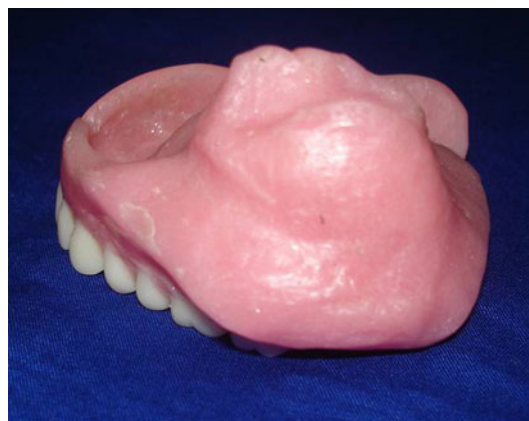

Fig. 9 Acrylized hollow bulb obturator

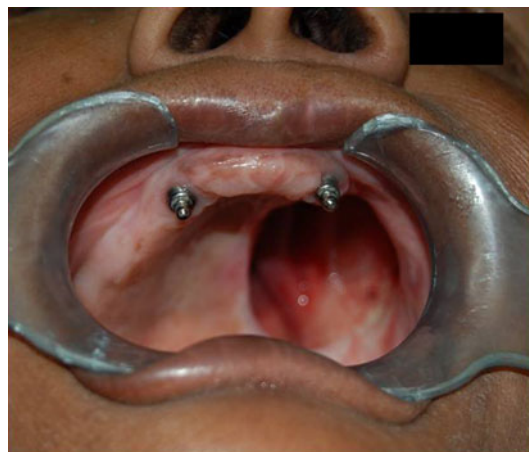

Fig. 10 Healing abutments replaced with Dalla Bona ball attachment

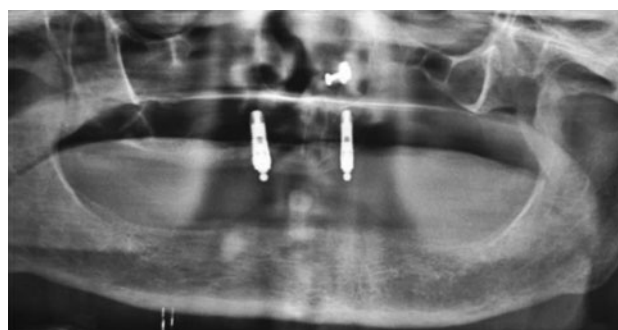


Fig. 11 Panoramic view showing adaptation of Dalla Bona attachments to implants

10. The abutments undercuts were blocked out with the latex (Fig. 13). Venting holes were made in the prosthesis for expressing excess acrylic resin and autopolymerizing resin was used to clinically relate

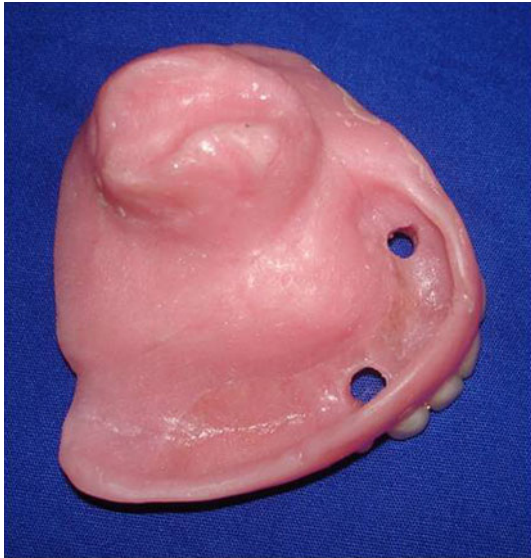

Fig. 12 Vent holes were created to house retentive component of attachment in the obturator

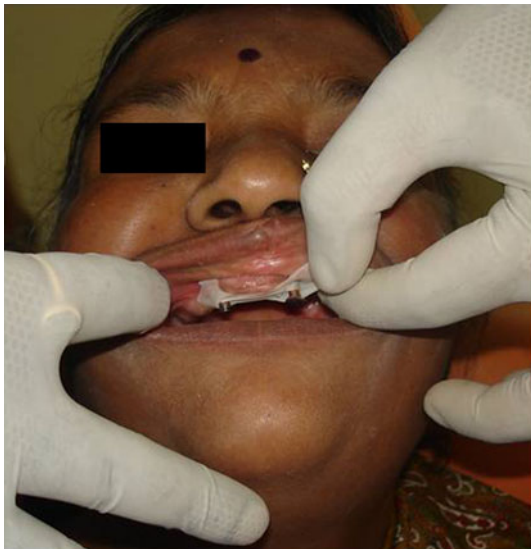

Fig. 13 Latex used to block abutment undercuts

the metal housing to the obturator. The denture was placed with finger pressure and the patient was asked to occlude until polymerization was complete.

11. The prosthesis was then removed and the positions of the components were rechecked (Fig. 14). The obturator was very retentive and stable. The prosthesis was finished and polished (Fig. 15).
12. The patient was trained to remove and place the prosthesis correctly. Oral hygiene instructions, especially around the implants, were reinforced and routine recall appointments were scheduled.

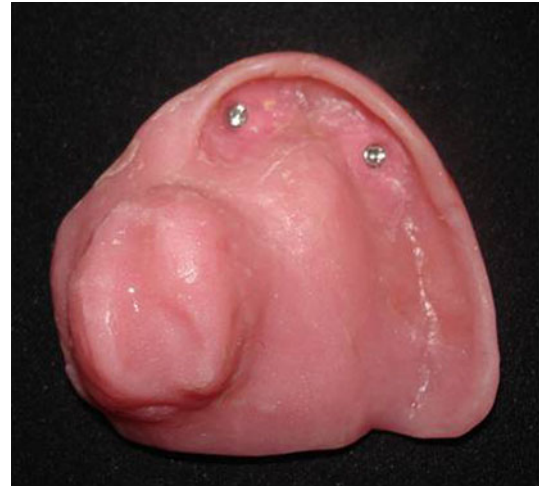


Fig. 14 Metal housing being transferred in the maxillary obturator prosthesis

The last follow up of the patient was 1 year after insertion of the prosthesis. The patient was functioning well with her prosthesis, and no signs of failure associated with implants were detected. The oral tissues appeared healthy and the prosthesis restored function of speech, deglutition, esthetics and psychological well being (Fig. 16).

Discussion

Patient with maxillary resection present a challenging situation for maxillofacial prosthodontists. A stable obturator was a prerequisite for satisfactory functional and esthetic rehabilitation after maxillectomy for this patient. Recent Investigations have confirmed the effectiveness of obturator prosthesis in terms of speech, masticatory function, swallowing and appearance [14], especially for small defects [15]. There is evidence that speech can be restored to a preoperative level with the maxillary obturator [4].

However, a stable and retentive prosthesis can seldom be achieved with conventional prosthesis treatment without adjunctive support of dental implants or natural teeth because of unfavorable postoperative conditions [16]. Prosthesis supported by endosteal implants and attachments are now available for oral rehabilitation of patients with maxillectomy [17, 18]. Ball attachments are proven to be an effective solution to various clinical problems related to edentulism. These are easily available, easy to master and cost effective alternative to improve the adaptability of conventional prosthesis for the patients.

The presented solution of using two endosteal dental implants with Dalla bona ball attachments offered adequate retention and support, while offering stability through well extended hollow bulb obturator. The anterior maxillary

Fig. 15 Finished and polished prosthesis

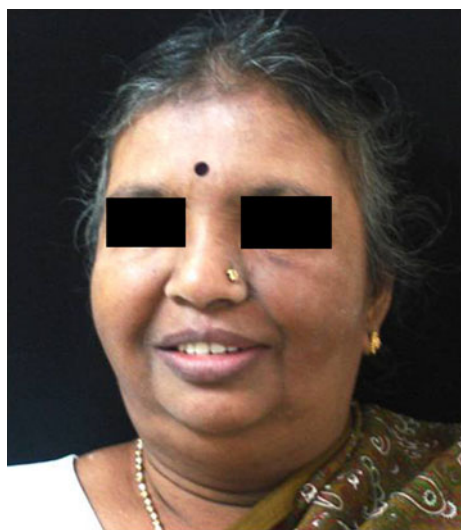
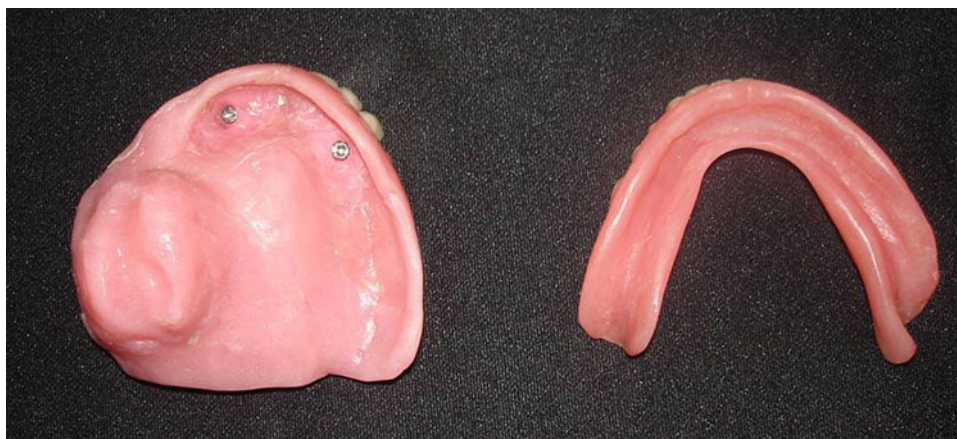


Fig. 16 Frontal view of maxillary rehabilitation displaying esthetics and satisfaction

segment is a key site for implant placement. After detailed exploration of the oral cavity under local anesthesia and radiographs, it was found that only suitable area for the implants was at the premaxilla region adjacent to 22 and canine region, 13. Implant placement in the posterior unresected area was limited by sinus pneumatization and alveolar ridge resorption. A sinus lift surgery, grafting procedure or zygomatic implant could have been planned, but the patient preferred to avoid secondary morbidity from the complex and reconstructive procedures. Therefore, the two osseointegrated implants were relied only for the retention. The close adaptation and maximum extension of the obturator within the defect were gained to improve the stability and support of the prosthesis, minimizing the amount of the lateral forces that are delivered to the implants.

The prosthetic rehabilitation of the presented edentulous patient with acquired maxillary defect with an obturator

had some difficulties at the stage of the impression making. Even the undercut area on the resected side was blocked with gauze piece before the impression, protecting the soft tissues from the residual impression materials like the rigid impression compound or the elastic putty consistency material and making a detailed removable impression of the defect was not easy. Beumer et al. [19] advocated the method in which the impression is achieved with the modeling plastic wax and an elastic impression material to record and relin the defect area. In this respect, recording the resected area with a semi-rigid material namely modeling wax being added incrementally over the denture base may be more protective and still an effective method.

Conclusion

Prosthetic rehabilitation of edentulous maxillectomy is a lengthy and clinically challenging situation. The goals of prosthetic rehabilitation include separation of oral and nasal cavities to allow adequate deglutition and articulation of teeth, prevention of enophthalmos and diplopia through possible support of the orbital contents, restore midfacial soft tissue contour and a satisfactory esthetic outcome. This clinical report presents the prosthodontic treatment of a patient with unilateral maxillectomy, in which osseointegrated implants and ball attachments were used to assist with retention, support and stability of definitive obturator prosthesis.

References

1. Davison SP, Sherris DA, Meland NB (1998) An algorithm for maxillectomy defect reconstruction. *Laryngoscope* 108:215–219
2. Sakuraba M et al (2003) Simple maxillary reconstruction using free tissue transfer and prostheses. *Plast Reconstr Surg* 111: 594–598

3. Kornblith AB et al (1996) Quality of life of maxillectomy patients using an obturator prosthesis. *Head Neck* 18:323–334
4. Rieger J et al (2002) Speech outcomes in patients rehabilitated with maxillary obturator prosthesis after maxillectomy: a prospective study. *Int J Prosthodont* 15:139–144
5. Mukohyama H et al (2005) Rehabilitation of a bilateral maxillectomy patient with a free fibula osteocutaneous flap. *J Oral Rehab* 32:541–544
6. Ackerman AJ (1953) Maxillofacial prosthesis. *Oral Surg Oral Med Oral Pathol* 6:176–200
7. Rosenthal LE (1964) The edentulous patient with jaw defects. *Dent Clin North Am* 8:773–779
8. Boucher LJ, Huepel EM (1966) Prosthetic restoration of a maxilla and associated structures. *J Prosthet Dent* 16:154–168
9. Branemark P-I et al (1984) An experimental and clinical study of osseointegrated implants penetrating the maxillary sinus. *J Oral Maxillofacial Surg* 42:497–505
10. Albrektsson T, Jansson T, Lekholm U (1986) Osseointegrated dental implants. *Dent Clin North Am* 30:151–174
11. Albrektsson T, Lekholm U (1989) Osseointegration: current state of the art. *Dent Clin North Am* 33:537–554
12. Adell R et al (1981) A 15 year study of osseointegrated implants in the treatment of the edentulous jaw. *Int J Oral Surg* 6:387–416
13. Chalian VA, Barnett MO (1972) A new technique for constructing a one-piece hollow obturator after partial maxillectomy. *J Prosthet Dent* 28:448–453
14. Rogers SN (2003) Health related quality of life after maxillectomy: a comparison between prosthetic obturation and free flap. *J Oral Maxillofacial Surg* 61:174–181
15. Okey DJ (2001) Prosthodontic guidelines for surgical reconstruction of the maxilla: a classification system of defects. *J Prosthet Dent* 86:352–363
16. Albrektsson T, Zarb G, Worthington P, Eriksson AR (1986) The long term efficacy of currently used dental implants: a review and proposed criteria of success. *Int J Oral Maxillofac Implants* 1:11–25
17. Niimi A, Ueda M, Kaneda T (1993) Maxillary obturator supported by osseointegrated implants placed in irradiated bone: report of cases. *J Oral Maxillofac Surg* 51:804–809
18. Mentag PJ, Kosinski TF (1981) Increased retention of a maxillary obturator prosthesis using osseointegrated intramobile cylinder dental implants: a clinical report. *J Prosthet Dent* 60:411–415
19. Beumer J III, Curtis TA, Firtell DN (1979) Maxillofacial rehabilitation. The C.V. Mosby Company, St. Louis, pp 221–226