

Customised Attachments Retained Cheek Plumper Prosthesis: A Case Report

Nandita N. Keni · Meena A. Aras · Vidya Chitre

Received: 19 July 2011 / Accepted: 26 May 2012 / Published online: 8 June 2012
© Indian Prosthodontic Society 2012

Abstract Emphasis on facial esthetics has become an integral part of dental treatment. Prosthetic rehabilitation of a completely edentulous patient no longer confines to only replacement of missing teeth. Patients are increasingly demanding improvement in esthetics at the end of treatment. Slumped or hollow cheeks can add years to a person's age. This article has described a simple, effective and noninvasive treatment alternative to improve facial appearance in a completely edentulous patient with hollow cheeks by making use of detachable plumper prosthesis using customised attachments.

keywords Hollow cheeks · Cheek plumper · Customised attachments · Detachable attachments · Complete denture · Separators

Introduction

In today's world esthetics play a very important role in a person's professional and social life. Cheeks due to their extreme visibility are an important factor in determining facial esthetics. Form of cheeks is determined by the support provided by internal structures—teeth, ridges or dentures. Extraction of molars, tissue thinning due to aging, or weight loss can cause concavities below the malar bone or hollow cheeks [1]. Slumped or hollow cheeks can add years to a person's age and hence have a detrimental psychological effect on the patient.

While replacing missing teeth, it is important that the prosthesis not only replace the missing teeth but also

restore the facial contours. Proper extensions and contours of denture flange can help to achieve this. However in some cases like patients with hollow cheeks, extra support has to be provided. This can be done using cheek plumper or cheek lifting appliances. Cheek plumpers or cheek lifting appliances have been used previously for the purpose of improving aesthetics and psychological profile in patients. Use of plumper prosthesis in maxillofacial prosthodontics is also well documented [2–4].

Slumped or hollow cheeks can add years to a person's age. A conventional cheek plumper prosthesis is a single unit prosthesis with extension near premolar–molar region which support the cheek. Major flaw of this design being increased weight of the prosthesis. Also the mesiodistal width may hinder placement especially in microstomia cases. Detachable plumper prosthesis is thus more beneficial. In a detachable plumper prosthesis, plumper part can be detached from the complete denture.

This clinical report illustrates the use of customised cobalt chromium attachments to support a detachable cheek plumper prosthesis in a completely edentulous patient with hollow cheeks.

Case Report

A 46 year old male patient reported to Goa dental college and hospital requesting replacement of missing teeth. On examination patient had completely edentulous upper and lower arches. Patient had lost his teeth over a period of 3 years as they were mobile and was edentulous for past 2 years. One of the major findings on extra oral examination was hollow cheeks. Patient was conscious of them and desired a prosthesis which would make his face look fuller and healthier. Treatment plan was formulated, keeping

N. N. Keni (✉) · M. A. Aras · V. Chitre
Department of Prosthodontics, GDCH (Goa), Panaji, Goa, India
e-mail: nandita.keni@gmail.com

patient's demand in mind. It was decided to give patient upper and lower complete dentures with detachable cheek plumpers for the maxillary denture.

Maxillary and mandibular impressions were made using impression compound (Y Dents, MDM Corporation, Delhi). Custom trays were made using autopolymerising acrylic resin. Border molding was done using low fusing impression compound (Aslate, Asian Acrylates, Mumbai) and wash impressions were made with medium body addition silicone impression material (Aquasil, Dentsply/caulk). Jaw relations were recorded. For the try in appointment waxed denture were first tried for occlusion and esthetics. After that cheek plumper made in wax and were attached to the maxillary denture and were evaluated to give patient a more fuller appearance. The waxed plumper was separated from the waxed denture. Prefabricated attachments were waxed in the complete denture in place of the plumper prosthesis.

Steps in fabrication of the attachments (Fig. 1).

- (1) Autopolymerising acrylic resin was used to form pattern for the attachment.
- (2) Attachment consisted of a flat rectangular thin base connected by a neck to two balls of 3 mm diameter. The width of rectangular base was kept slightly short of the width of the plumper prosthesis.
- (3) The attachments were cast using chrome cobalt alloy. They were polished on all surfaces except the one which would be waxed in the denture as the surface irregularities aid in better retention of attachment to the denture base.

Acrylisation was done in conventional way. Upper denture was acrylised with the attachments placed on the buccal surface of denture. The finished and polished dentures were tried in the mouth. The waxed plumper prosthesis was repositioned over the attachment and required corrections were done (Fig. 2). Wax pattern of plumper was invested and acrylised. The acrylised plumpers were tried in the mouth and orthodontic separators were placed in the plumper part which corresponded to the attachments in the denture to get snap fit. For this, concavities were made in



Fig. 1 Customised attachments

the plumper part. Separators were placed over the attachments. These were then picked using autopolymerising acrylic resin in the plumper part. These separators allowed close approximation of the plumper with the denture and also facilitated removal from the denture (Fig. 3).

Patient was instructed on the use of plumpers and dentures were delivered after evaluating them for fit and esthetics. Recall appointment were scheduled after 1 day, 1 month and every 6 months (Figs. 4, 5).

Discussion

In the present case detachable plumper prosthesis were planned to reduce weight of the final prosthesis and to

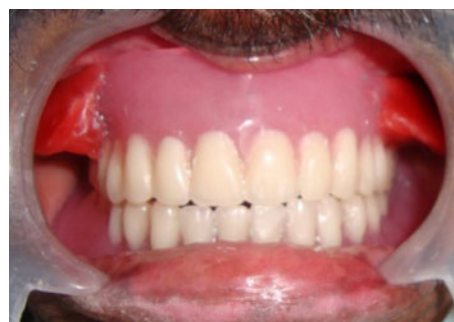

Fig. 2 Try in of acrylised denture with the cheek plumper

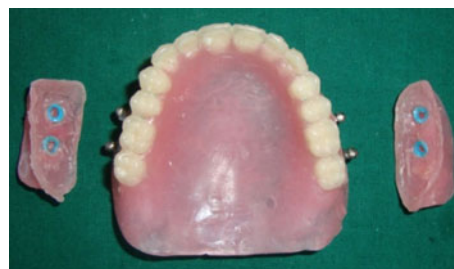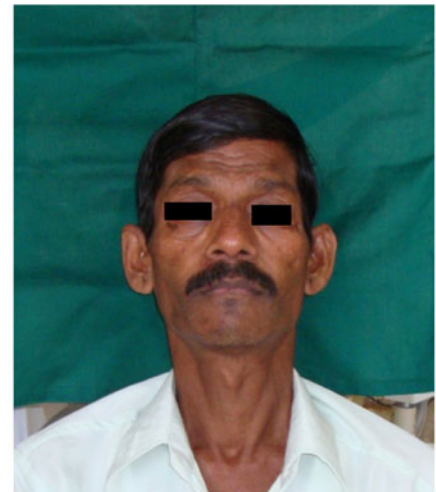


Fig. 3 Upper complete denture with detachable plumpers. Separators in plumpers allow a snap fit

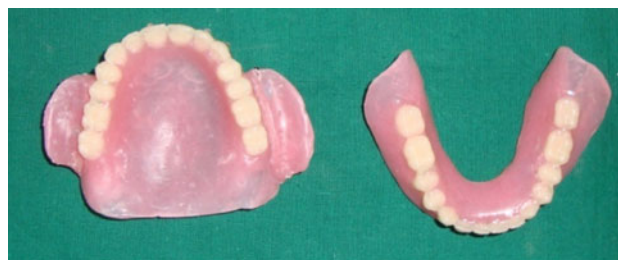

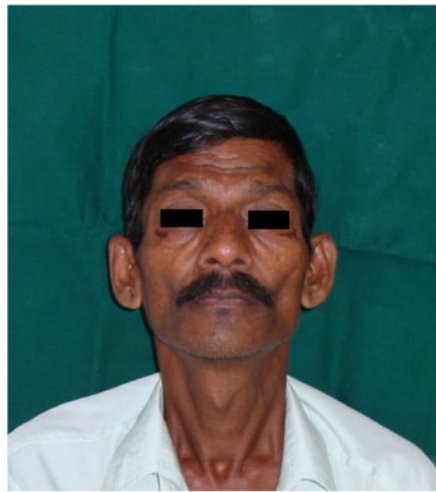Fig. 4 Upper complete denture with detachable plumpers and lower complete denture

Fig. 5 Pretreatment photograph (frontal view) post treatment photographs (frontal view)



Pretreatment photograph(frontal view) post treatment photographs(frontal view)

allow ease in placement of the prosthesis. Detachable plumpers enabled the patient to remove the plumpers and use the denture if required. In the past, magnet retained plumper prosthesis have been used but they exhibit poor corrosion resistance and loss of magnetic property over a period of time.

To form a detachable unit, attachments were used as they provide an easy, cost effective and reliable means. Cobalt chromium alloys were used to cast the customised attachments due to their biocompatibility, rare allergies [5, 6] and resistance to corrosion [7–9]. CoCr alloys are also routinely used for casting procedure in dental laboratories [10].

Conclusion

This article has described a simple, effective and noninvasive treatment alternative to improve facial appearance in a patient with hollow cheeks. An effort was made to improve patient's appearance by providing better support to the cheeks. The customised attachments retained cheek plumper prosthesis successfully restored the contour of cheek improving esthetics and psychological wellbeing of the patient.

References

1. Bains JW, Elia JP (1994) The role of facial skeletal augmentation and dental restoration in facial rejuvenation. *Aesthet Plast Surg* 18(3):243–246
2. Lazzari JB (1955) Intraoral splint for support of lips in Bells palsy. *J Prosthet Dent* 5(4):579–581
3. Larzen SJ, Cartern JF, Abrahamian HA (1976) Prosthetic support for unilateral facial paralysis. *J Prosthet Dent* 35(2):192–201
4. Hitoshi M, Chiaki K, Takashi O, Hisashi T (2004) Lip plumper prosthesis for a patient with a marginal mandibulectomy: a clinical report. *J Prosthet Dent* 92(1):23–26
5. Wiltshire WA, Ferreira MR, Ligthelm AJ (1996) Allergies to dental materials. *Quintessence Int* 27(8):513–520
6. Takeda T, Ishigami K, Shimada A, Ohki K (1996) A study of discoloration of the gingiva by artificial crowns. *Int J Prosthodont* 9(2):197–202
7. Khamis E, Seddik M (1995) Corrosion evaluation of recasting non-precious dental alloys. *Int Dent J* 45(3):209–217
8. Geis-Gerstorf J, Sauer KH, Passler K (1991) Ion release from Ni–Cr–Mo and Co–Cr–Mo casting alloys. *Int J Prosthodont* 4(2):152–158
9. Brune D (1986) Metal release from dental biomaterials. *Biomaterials* 7(3):163–175
10. Eisenburger M, Addy M (2002) Radiological examination of dental castings—a review of the method and comparisons of the equipment. *J Oral Rehabil* 29(7):609–614