

# A Simplified Approach for Placing the Iris Disc on a Custom Made Ocular Prosthesis: Report of Four Cases

Pradeep Kumar · Himanshi Aggrawal ·  
Raghuwar D. Singh · Pooran Chand ·  
Sunit K. Jurel · H. A. Alvi · Sanjiv K. Gupta

Received: 19 February 2012 / Accepted: 21 September 2012 / Published online: 18 October 2012  
© Indian Prosthodontic Society 2012

**Abstract** This case report describes a series of four cases of different age group, in which a simplified approach was applied for positioning the iris disc on a custom made ocular prosthesis. For each of the patient, a pre-fabricated eye was selected; whose iris and pupil closely matched that of the natural eye. This was duplicated for use as a tray in impression procedure. Iris portion of the stock eye was trimmed out and oriented on the cast according to previously transferred pupillary mark. This stock eye-wax pattern combination was tested in the eye socket, modified accordingly and finally cured in transparent heat cured acrylic resin. The technique to fabricate ocular prosthesis in present case reports modifies pre-fabricated eye prosthesis to a custom-made fit and aesthetics. This helped us to overcome the disadvantages of poor fit, inadequate movement and complex painting procedure and technique involved in making a custom-made ocular prosthesis. It can be concluded that close adaptation of the custom-made ocular prosthesis to the tissue bed provides maximum comfort and restores full physiologic function to the accessory organs of the eye.

**Keywords** Eye prosthesis · Ocular defect · Retinoblastoma

## Introduction

The unfortunate loss or absence of an eye may be caused by a congenital defect, irreparable trauma, tumor, a painful blind eye, sympathetic ophthalmia, or the need for histologic confirmation of a suspected diagnosis [1, 2]. The disfigurement associated with the loss of an eye can cause significant physical and emotional problems [3]. Most patients experience significant stress, primarily to adjusting with functional disability caused by the eye loss, and to societal reactions to the facial impairment [4]. Replacement of the lost eye as soon as possible after healing from eye removal is necessary to promote physical and psychological healing for the patient and to improve social acceptance [5]. A multidisciplinary management and team approach are essential in providing accurate and effective rehabilitation and follow-up care for the patient [6]. Therefore, the combined efforts of the ophthalmologist, the plastic surgeon, and the maxillofacial prosthodontist are essential to restore the patient's quality of life. This article presents four cases in which a simplified approach was performed for placing the iris disc in custom made ocular prosthesis to achieve ideal fit and aesthetics.

---

P. Kumar · H. Aggrawal · R. D. Singh · P. Chand ·  
S. K. Jurel · H. A. Alvi  
Department of Prosthodontics, Faculty of Dental Sciences,  
King George's Medical University UP, Lucknow,  
Uttar Pradesh, India

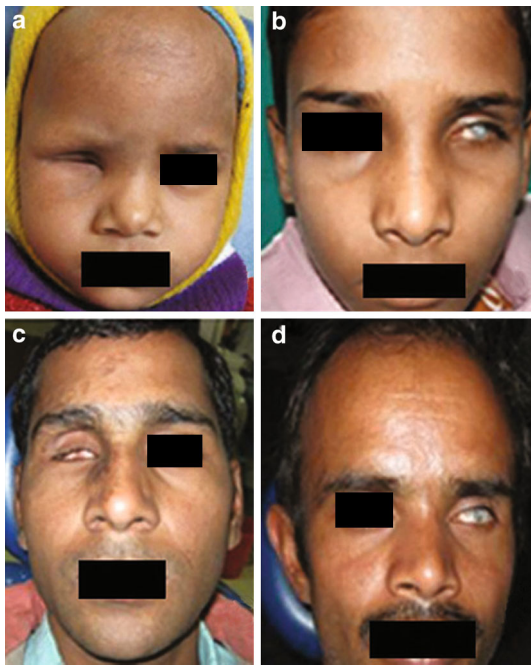R. D. Singh (✉)  
Type 4, Flat No. 9, Butler Palace Colony, Lucknow 226001,  
Uttar Pradesh, India  
e-mail: raghuwards@rediffmail.com

S. K. Gupta  
Department of Ophthalmology, King George's Medical  
University UP, Lucknow, Uttar Pradesh, India

## Case Report

### Case 1

A 4-year-old female child reported to the Department of Ophthalmology with complaints of white spot on the right eye accompanied by bulging and squint (Fig. 1a). After



**Fig. 1** Pre-operative view of the patients

through investigations, she was diagnosed with retinoblastoma and an enucleation surgery was performed. The patient was referred to the Department of Prosthodontics for the fabrication of an ocular prosthesis after healing of the eye socket. After detailed case history and proper examination treatment was planned.

#### Case 2

An 11-year-old male child patient visited the department of ophthalmology with the chief complaint of loss of vision and discoloration of his left eye (Fig. 1b). On examination, it was found that there was complete loss of vision in the left eye. Patient had a history of trauma with pencil 2 years back, but he didn't disclose it at home. When he gradually started losing his eyesight then he informed his parents, but at that time he was not able to regain his eyesight again. Because child was suffering from mental trauma due to loss of eyesight and unaesthetic appearance of his face, he was sent to the Department of Prosthodontics for the fabrication of ocular prosthesis.

#### Case 3

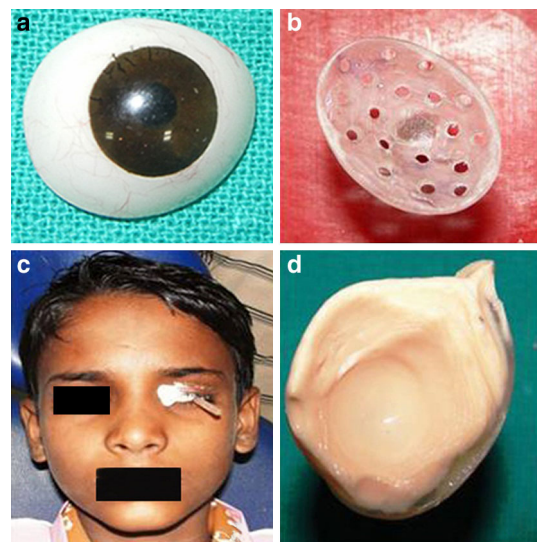
An 18-year-old male child reported to the Department of Ophthalmology with complaints of white spot in his right eye and diminution of vision completely (Fig. 1c). He was diagnosed with retinoblastoma. After enucleation surgery, he was referred to the Department of Prosthodontics for the fabrication of an ocular prosthesis after healing.

#### Case 4

A 35-year old male patient reported to the department of Prosthodontics with the chief complaint of loss of his left eye sight completely and unaesthetic appearance due to bulging white spot in his left eye with regressing eye ball (Fig. 1d). There was a history of trauma 3 year back, followed by gradual loss of left eyesight. He went through several ophthalmologists but couldn't regain the eyesight. Treatment was planned and it was decided to fabricate ocular prosthesis for left eye.

#### Clinical Procedure

After careful examination of the area of the defect and treatment planning, the procedure was explained to the patient/guardian to gain their co-operation. Patient/guardian consent was taken for making photographic records. The procedure was initiated by selecting and modifying a pre-fabricated (stock) eye as shown in Fig. 2a, whose iris and pupil closely matched that of the natural eye, to comfortably and loosely fit the socket. This was duplicated with clear-heat cured polymethyl methacrylate resin (PMMA—Trealon, Dentsply India Pvt. Ltd., Gurgaon, India) and perforated, for use as a tray in impression procedure (Fig. 2b). Perforation of the tray was done to avoid any compression of the ocular tissues. A thin tube (1 mm diameter and 2 cm length) made up of self cure acrylic resin was used to serve as a handle and attached at the pupillary point of the impression tray for proper tray orientation during impression making. The tray was placed in the socket and the patient was asked to gaze at a distant

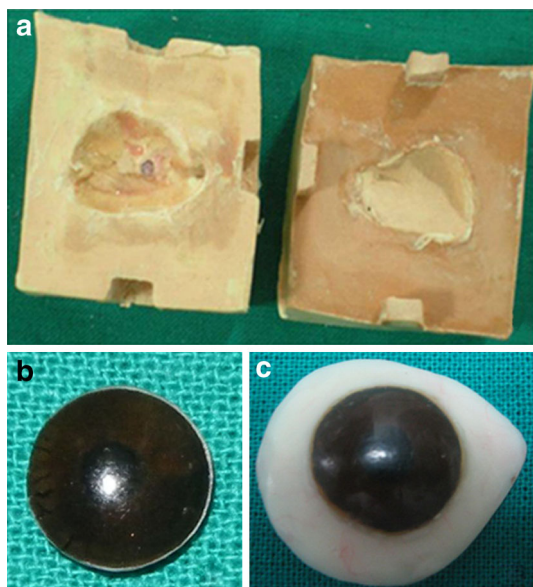


**Fig. 2** Impression procedure for ocular prosthesis

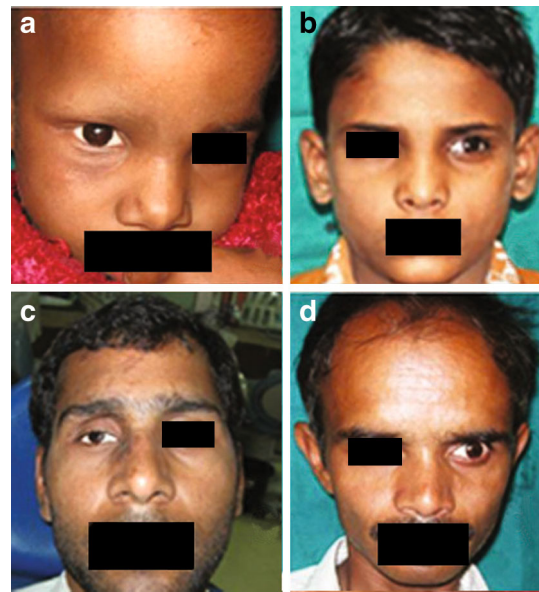point to accurately mark the pupil as per contralateral side, on the tray (Fig. 2c).

Petroleum jelly was applied to the eyebrows for the easy removal of the impression when it sets. A thin mix of an irreversible hydrocolloid (Ophthalmic moldite, Milton Roy Co. Sarasota Fla.) was then injected into the socket and some of it loaded in the tray, which was placed into position. The patient was asked to move his/her normal eye in all directions to allow the irreversible hydrocolloid to flow into all areas of the enucleated socket, as well as onto the outer surface of the tray to record lid movements, while taking care that the tray handle replicated the pupillary position of the natural eye. Impression was examined for accuracy as shown in Fig. 2d and the cast was poured in two parts with the second part being poured after applying lubricant and making orientation grooves on the partially set first half (Fig. 3a). The tube was maintained as a sprue to pour the wax and to transfer the pupillary point onto the cast.

The technique was modified here onwards by trimming out the iris portion of the stock eye, as shown in Fig. 3b, and orienting it on the cast according to previously transferred pupillary mark. Carving wax mixed along with the yellow sticky wax was poured into the cast, taking care that the iris portion that was trimmed from the stock eye was maintained in its previously oriented position, in the wax pattern. This stock eye-wax pattern combination was tested in the socket and modified for adequacy of ocular movements, correction of pupillary alignment, proper palpebral movements, scleral contour and convexity.



**Fig. 3** a Cast poured in two parts. b Iris taken out from the stock eye. c Finished ocular prosthesis with characterization



**Fig. 4** Patients with ocular prosthesis

The next step was to reproduce scleral shade of the normal eye. For this, shade tabs were prepared by mixing and matching different shades and proportions of tooth-colored acrylic (SC 10, Pyrax, Roorkee, India) till the color of sclera of the other eye was replicated. Then the adjusted and modified stock eye-wax pattern combination was invested, flaked and de-waxing was done. Red silk fibers (taken from the red ribbon; Keshav Traders, Surat, Gujarat, India) to mimic veins were placed in the dough of the determined acrylic shade followed by routine curing, finishing and polishing. Finally, a thin film of the sclera was removed and replaced by a clear film of transparent heat-cured PMMA (Trevalon, Dentsply India Pvt. Ltd., Gurgaon, India) to simulate corneal translucency. The properly finished and polished prosthesis, as shown in Fig. 3c, was inserted in the socket after being disinfected and lubricated with an ophthalmic lubricant (Ecotears, Intas Pharmaceuticals Ltd, Ahmedabad, India) to maintain a tear film over the prosthesis and to improve eye movements. Minor adjustments were made at the time of ocular prosthesis insertion as per the patient's comfort and aesthetics (Fig. 4). Necessary instructions for cleaning, placement and removal of the prosthesis were given and the need for regular recall appointments was emphasized.

## Discussion

Fabrication of ocular prosthesis has been known to human being since times immemorial. Prosthetic rehabilitation fulfils aesthetic as well as psychological requirement of the patients [7]. A correctly placed prosthesis should restore

the normal opening of the eye, support the eyelid, restore the degree of movement and be adequately retained and aesthetically pleasing [8]. Custom-made prosthetic eye fabrication involves complex painting procedures in various stages that are time taking and based purely on painting skills of the operator [4, 9]. Various impression techniques for ocular prosthesis have been described in the previous literatures [10, 11]. The technique to fabricate ocular prosthesis in present case reports modifies pre-fabricated eye prosthesis to a custom-made fit and esthetics. This helped us to overcome the disadvantages of poor fit, inadequate movement and complex painting procedure and technique involved in making a custom-made ocular prosthesis.

### Conclusion

The use of custom-made ocular prosthesis of appropriate contour, size and colour can provide an acceptable aesthetic result. The close adaptation of the custom-made ocular prosthesis to the tissue bed provides maximum comfort and restores full physiologic function to the accessory organs of the eye. Also, as discussed above, the aesthetic and functional outcome of the prosthesis was far better than the stock ocular prosthesis.

### References

1. Allen L, Webster HE (1969) Modified impression method of artificial eye fitting. *Am J Ophthalmol* 67:189–218
2. Laney WR (1979) Maxillofacial prosthetics: postgraduate dental handbook series, vol 4. PSG, Littleton, pp 279–306
3. Robert BW, John VN (1956) Ocular prosthesis. *J Prosthet Dent* 6:272–278
4. Reis RC, Brito e Dias R, Mesquita CJC (2008) Evaluation of iris colour stability in ocular prosthesis. *Braz Dent J* 19:370–374
5. Murphey PJ, Pitton RD, Schlossberg L, Harris LW (1945) The development of acrylic eye prosthesis at the national naval medical center. *J Am Dent Assoc* 32:1227–1244
6. Brown KE (1970) Fabrication of an ocular prosthesis. *J Prosthet Dent* 24:225–235
7. Artopoulou II, Montgomery PC, Wesley PJ, Lemon JC (2006) Digital imaging in the fabrication of ocular prosthesis. *J Prosthet Dent* 95:327–330
8. Kale E, Mese A, Izgi AD (2008) A technique for fabrication of an interim ocular prosthesis. *J Prosthodont* 17:654–661
9. Cain JR (1982) Custom ocular prosthesis. *J Prosthet Dent* 48:690–694
10. Robert LS (1986) Modified ocular prosthesis impression technique. *J Prosthet Dent* 55:482–485
11. Mekayarajjananonth T, Salinas T, Chambers M, Lemon J (2003) A mold-making procedure for multiple orbital prostheses fabrication. *J Prosthet Dent* 90:97–100