

Magnet retained lip prosthesis in a geriatric patient

Srinivasa B Rao, Sunil Kumar Gurram¹, Sunil Kumar Mishra², Ramesh Chowdhary³

Department of Maxillofacial Prosthodontics and Implantology, Gitam Dental College, Visakhapatnam, Andhra Pradesh, ¹Department of Maxillofacial Prosthodontics and Implantology, Mamata Dental College, Khammam, Telangana, ²Department of Maxillofacial Prosthodontics and Implantology, Peoples Dental Academy, Bhopal, Madhya Pradesh, ³Department of Maxillofacial Prosthodontics and Implantology, Rajarajeshwari Dental College, Bengaluru, Karnataka, India

Abstract

Surgical resection of lips is a relatively rare procedure. A defective lip may cause the patient to feel socially vulnerable as well as functionally handicapped and the defect will influence the patient's self-esteem and body image. Patients with labial defects also experience speech problems along with drying and crusting of the tissues in the area of defect. The lip and cheek provide a valve mechanism for speech. Rehabilitation of patients with this type of surgery creates numerous challenges for both the surgical and the maxillofacial prosthetic teams. The goals of prosthetic treatment include regaining favorable speech and restoration of esthetics. This case report presents a 65-year-old woman who was referred for restoration of her lost lip. This case paper describes a quick and simple method of positioning magnets with lip prosthesis attached to maxillary denture and thus esthetics and speech of the patient is restored. Use of retention magnets simplify the clinical and laboratory phase retains the denture and makes it stable and comfortable for the patient. The advent of magnets has enhanced the dental practitioner's capabilities with a remarkably improved potential for increasing prosthesis stability and preserving tissue.

Key Words: Esthetics, lip prosthesis, magnet, maxillofacial prostheses, partial denture

Address for correspondence:

Dr. Sunil Kumar Mishra, Department of Maxillofacial Prosthodontics and Implantology, Peoples Dental Academy, Bhopal, Madhya Pradesh, India.
E-mail: sunilmsr200@yahoo.co.in

Received: 08th January, 2015, **Accepted:** 17th April, 2015

INTRODUCTION

Restoration of a facial defect is a challenge for the maxillofacial prosthodontist and surgeon. The maxillary lip defects are reconstructed with the use of tissue from mandibular lip. The continuity of oral aperture is effectively restored, however because the net loss of soft tissue from maxillary lip is not replenished in such a procedure microstomia is inevitable. Such clinical situations introduced significant challenges for future dental treatment. The prosthodontist is limited by the

materials used for fabrication of a facial prosthesis, movable tissue beds, unsuitability of anatomic undercuts, and patient acceptance toward the use of a prosthesis. The aim of a facial prosthesis is to fulfill the esthetic needs of the patient and to improve the patient's quality of life. It is important that the patient be informed regarding the esthetics outcome. The rehabilitation of maxillary lip defects is a significant challenge in terms of creating retention and preserving existing dentition in an environment of expanded functional stress. The advent of magnets has enhanced the dental practitioner's capabilities in this regard with a remarkably improved potential for increasing prosthesis stability and preserving tissue. Extra oral defects producing gross anatomical changes produces deformity and affects the body image of the individual.^[1] Creating facial prostheses to restore midfacial defects involves many challenges. Apart from making the patient socially vulnerable the lip defect prevents adequate speech and deglutition. The speech problems are mainly associated with bilabial and labiodental phonemes.^[2]

Access this article online	
Quick Response Code:	Website: www.j-ips.org
	DOI: 10.4103/0972-4052.158081

With lack or compromised oral competency, leading to drying and crusting of the tissues in the area of the defect.^[3] The goals of prosthodontic treatment is to restore appearance and function.^[4]

CASE REPORT

A 60-year-old female patient reported to the Department of Prosthodontics with the chief complaint to inability to chew food properly and adversely affected appearance. A thorough case history revealed that she underwent resection of a portion of upper lip in early childhood. On examination, the defect was in the center of the upper lip [Figure 1] and the upper arch was partially edentulous with only posterior teeth remaining. The treatment plan was made to rehabilitate the patient with magnet retained lip prosthesis with maxillary removable partial denture. The ethical clearance was taken from ethics committee Mamata Dental College, Khammam, Telangana, India.

Upper and lower preliminary impressions were made in irreversible hydrocolloid (Alginate, Tropicalgin, Zhermack, Rovigo, Italy) and casts poured with type III dental stone (Kalrock, Kalabhai, Mumbai, Maharashtra, India). Impression of the lower half of the face was made with alginate [Figure 2] supported with plaster backing and the cast was poured with dental stone.

Special tray was fabricated with self-cure acrylic (DPI, Mumbai, Maharashtra, India) and final impression was made in elastomeric impression material (Reprosil, Dentsply, Caulk, Milford, DE, USA). The jaw relations were recorded in the usual manner and teeth arrangement was done. The wax pattern of the lip defect was sculpted and adapted on the cast [Figure 3a]. During try in stage the removable partial denture [Figure 3b] and preliminary wax sculpture [Figure 4a] were evaluated on patient for esthetics and function. The margins

and contours of the lip prosthesis were carved to blend with the adjacent structures. Sufficient lip support was obtained without violating the patient's neutral zone and lip competency. The shade matching was done.

The wax pattern was invested and dewaxing done. During packing the stains were mixed in the acrylic resin. The material to be packed in the supralabial region was stained to simulate the skin color and the material to be packed in the labial region was stained to simulate the lip color [Figure 4b]. After curing and deflasking, the cured removable partial denture and lip prosthesis were retrieved. Trimming, finishing, and polishing procedures were performed. Two marks were made on the labial flange of the interim prosthesis and on the inner surface of the lip prosthesis to place the magnetic attachment. A pair of commercially available magnets (Magna fix, Dentsply, Milford, USA) was employed to retain the lip prosthesis with the intraoral removable partial denture. Air abrasion of magnet with alumina was done than primer 4-methacryloxyethyl trimellitic anhydride (4-META) (META Fast primer, Sun medical company, Moriyama, Japan) was applied to increase the bonding with autopolymerizing resin. Provision for placement of magnets in the flange of the final prosthesis and in the lip prosthesis was made and positioned with the help of autopolymerizing resin. Complete polymerization was ensured by placing in a pressure pot and finishing and polishing was then carried out. The attachment of lip prosthesis to the removable partial denture prosthesis was first checked outside the patient's mouth, then it was checked in the patient's mouth for comfort, function and esthetics [Figure 5] and the patient was instructed about the maintenance of the prosthesis.

At the recall appointment of the 1st, 3rd, and 6th month, it was observed that there was no deformation of the prosthesis' margins related to the application of magnets and cleaning

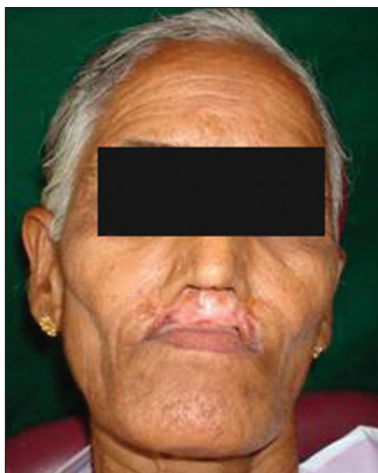

Figure 1: Patient with maxillary lip defect

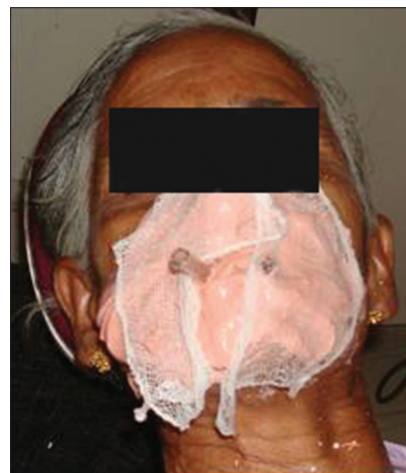

Figure 2: Impression of the lower half of the face

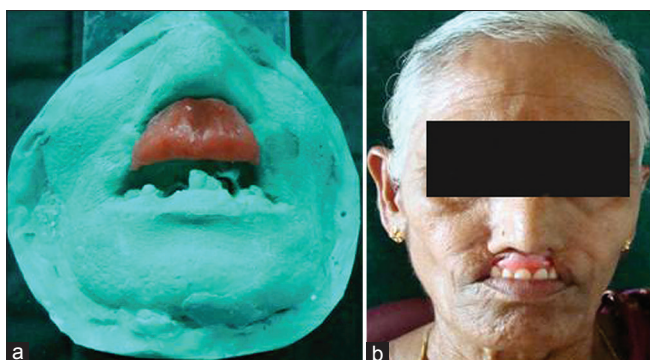


Figure 3: (a) Sculpting of the wax pattern. (b) Interim prosthesis at tryin stage

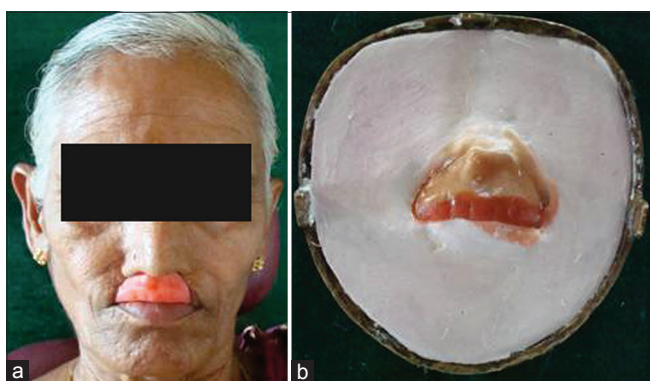

Figure 4: (a) The waxed lip prosthesis at the tryin stage. (b) The processed lip prosthesis

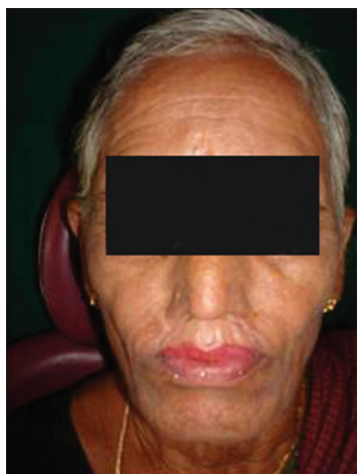

Figure 5: Insertion of Lip prosthesis retained with removable partial denture

agents. With improved material strength, it was easier for the patient to wear or remove the prosthesis.

DISCUSSION

Creating prosthesis, having realistic skin surface and seamless visual integration with the surrounding tissues, requires both artistic and technical skill.^[5] Prosthesis is especially useful in

case of lost body parts, as reconstructive surgery cannot fully restore aesthetics.^[6] Various materials such as wood, clay, leather, enameled porcelain, acrylic resin and silicone elastomers are used in the fabrication of extraoral prosthesis. Among these acrylic resin and silicone are the most commonly used materials for rehabilitation.^[7] Maxillofacial prostheses require frequent replacement because the elastomers and its coloring agents undergo changes.^[8] Acrylic resin can be easily characterized and presents great durability. Creating facial prostheses to restore midfacial defects involves many challenges, including the achievement of proper retention and marginal fit. Adhesives, mechanical devices, tissue undercuts, and implants all have been used to retain facial prostheses.^[1,2,9] Soft tissues around midfacial defects may not be ideal for adhesive retention.^[1] Movement and range of motion of tissues adjacent to the defect inhibits the marginal adaptation of the prosthesis.^[10] If surgeons prepare the residual soft tissues to create it might provide retention to prosthesis.^[11] Undercuts often provide insufficient retention, however, and they may cause soft tissue irritation. Maxillofacial prostheses retained by osseointegrated implants are esthetic and functional.^[9] To gain a more stable and retentive prosthesis without the benefit of osseointegrated implants, the attachment of facial prostheses to maxillary obturators has been reported. However, the connection of facial and intraoral prostheses often results in movement of the facial prosthesis during mastication, especially when edentulous patients are treated with maxillary obturators.^[10]

Birnbach and Herman^[11] described the use of intraoral and extraoral devices to rehabilitate orofacial cancer patients. Cheng *et al.*^[2] restored a mandibular lip defect with retentive elements bonded to anterior mandibular teeth and an extraoral lower lip. Oki *et al.*^[3] described a case report, where mechanical retention was obtained through ball attachments fixed on the obturator prosthesis. Zeno *et al.*^[12] described combination lower lip prosthesis retained by two Micro-ERA attachments as an intraoral component. Retentive elements beyond what conventional adhesives offer often are required.^[1] For this reason the prosthesis given to patient describe in this case report was retained with mechanical retention through magnet.^[10] This prove to be successful as the prostheses could be easily inserted and removed, there was good retention, which gives a psychological advantage and confidence to patient to wear the prosthesis. Disadvantage of magnets are their detachability from the resin denture bases, so care was taken to overcome that by air abrasion of magnet with alumina and application of primer to increase the bonding with autopolymerizing resin.^[13]

CONCLUSION

Use of retention magnets simplify the clinical and laboratory phase retains the denture and makes it stable and comfortable

for the patient. This treatment is one successful approval to the restoration of oral function and increases the patients quality of life.

REFERENCES

1. Beumer J, Curtis T, Marunick M. Maxillofacial Rehabilitation: Prosthodontic and Surgical Considerations. Tokyo: Ishiyaku EuroAmerica Inc.; 1996. p. 377-454.
2. Cheng AC, Morrison D, Maxymiw WG, Archibald D. 1997 Judson C. Hickey Scientific Writing Awards. Lip prosthesis retained with resin-bonded retentive elements as an option for the restoration of labial defects: A clinical report. J Prosthet Dent 1998;80:143-7.
3. Oki M, Ozawa S, Taniguchi H. A maxillary lip prosthesis retained by an obturator with attachments: A clinical report. J Prosthet Dent 2002;88:135-8.
4. Mukohyama H, Kadota C, Ohyama T, Taniguchi H. Lip plumper prosthesis for a patient with a marginal mandibulectomy: A clinical report. J Prosthet Dent 2004;92:23-6.
5. Gary JJ, Smith CT. Pigments and their application in maxillofacial elastomers: A literature review. J Prosthet Dent 1998;80:204-8.
6. Pillet J. Esthetic hand prostheses. J Hand Surg Am 1983;8:778-81.
7. Aziz T, Waters M, Jagger R. Surface modification of an experimental silicone rubber maxillofacial material to improve wettability. J Dent 2003;31:213-6.
8. Chen MS, Udagama A, Drane JB. Evaluation of facial prostheses for head and neck cancer patients. J Prosthet Dent 1981;46:538-44.
9. Parel SM, Branemark PI, Tjellstrom A, Gion G. Osseointegration in maxillofacial prosthetics. Part II: Extraoral applications. J Prosthet Dent 1986;55:600-6.
10. Dumbrigue HB, Fyler A. Minimizing prosthesis movement in a midfacial defect: A clinical report. J Prosthet Dent 1997;78:341-5.
11. Birnbach S, Herman GL. Coordinated intraoral and extraoral prostheses in the rehabilitation of the orofacial cancer patient. J Prosthet Dent 1987;58:343-8.
12. Zeno HA, Sternberger SS, Tuminelli FJ, Billotte M, Kurtz KS. Combination lower lip prosthesis retained by an intraoral component. J Prosthodont 2013;22:397-401.
13. Chen J, Oka K, Hua W, Ichikawa T. Effect of surface treatment with commercial primers on tensile bond strength of autopolymerising resin to magnetic stainless steel. Int Chin J Dent 2005;5:7-11.

How to cite this article: Rao SB, Gurram SK, Mishra SK, Chowdhary R. Magnet retained lip prosthesis in a geriatric patient. J Indian Prosthodont Soc 2015;15:187-90.

Source of Support: Nil, **Conflict of Interest:** None declared.