

## Case Report

# Multidisciplinary approach for reconstruction of cranial defect with polymethyl methacrylate resin reinforced with titanium mesh

Vikrant Dilip Sane, Pankaj Kadam<sup>1</sup>, Aniket Jadhav<sup>2</sup>, Rashmi Saddiwal<sup>3</sup>, Yash Merchant<sup>4</sup>

Departments of OMFS, <sup>1</sup>Prosthodontics, <sup>2</sup>Endodontics, <sup>3</sup>Oral Medicine and Radiology and <sup>4</sup>Oral and Maxillofacial Surgery, Bharati Vidyapeeth University Dental College and Hospital, Pune, Maharashtra, India

### Abstract

Cranial defects occur most commonly as a sequelae to trauma, the incidence being as high as 70%. The successful management of a case of trauma in an emergency situation requires quick evacuation of the hematoma, repair of the dura, and the scalp but not necessarily the integrity of the calvarial segment as an immediate measure. So the reconstruction of the calvarial defect in these cases is mostly carried out as a secondary procedure. Various materials are used for reconstruction of cranial defects, polymethyl methacrylate (PMMA) resin being one of them. In this article, we report a case which was successfully treated by PMMA resin in combination with a titanium mesh for reconstruction of the cranial defect as a secondary procedure.

**Key Words:** Cranial defect, polymethyl methacrylate, reconstruction, titanium mesh

### Address for correspondence:

Dr. Vikrant Sane, Department of Oral and Maxillofacial Surgery, Bharati Vidyapeeth University Dental College and Hospital, Katraj-Dhankwadi Educational Complex, Satara Road, Pune - 411 043, Maharashtra, India. E-mail: [vikrantsane@gmail.com](mailto:vikrantsane@gmail.com)

**Received:** 12<sup>th</sup> January, 2015, **Accepted:** 2<sup>nd</sup> September, 2015

### INTRODUCTION

Cranial vault defects can arise as a result of congenital deformities, trauma, decompressive craniectomies, and bone flap loss due to infection.<sup>[1-3]</sup> In addition to compromising the patient's esthetics, these defects also expose a significant area of the brain.<sup>[4,5]</sup> Reconstruction of the large cranial vault defects thus still continues to be a challenge to craniofacial surgeons and neurosurgeons. Various types of materials are now available for reconstruction of cranial defects so as to construct the rigid framework of the skull. However, the selection of implant for reconstruction of defects still remains controversial.<sup>[5]</sup> In

this article, we present a case report where an interdisciplinary approach was used for successful reconstruction of the large frontal bone defect using a combination of heat cured polymethyl methacrylate (PMMA) resin and titanium mesh.

### CASE REPORT

A 38-year-old patient reported to our department with a chief complaint of depression and defect in right side frontal region. He gave a history of road traffic accident 18 months back. The patient also gave a history of being operated earlier for

This is an open access article distributed under the terms of the Creative Commons Attribution-NonCommercial-ShareAlike 3.0 License, which allows others to remix, tweak, and build upon the work non-commercially, as long as the author is credited and the new creations are licensed under the identical terms.

**For reprints contact:** [reprints@medknow.com](mailto:reprints@medknow.com)

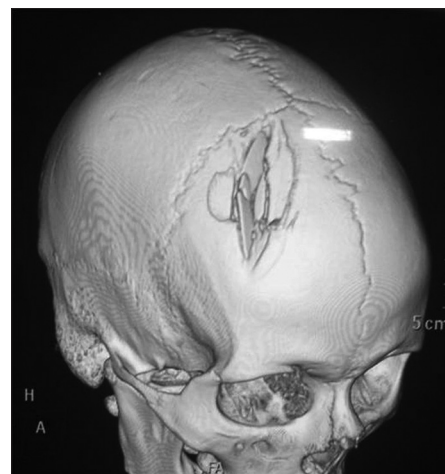
**How to cite this article:** Sane VD, Kadam P, Jadhav A, Saddiwal R, Merchant Y. Multidisciplinary approach for reconstruction of cranial defect with polymethyl methacrylate resin reinforced with titanium mesh. *J Indian Prosthodont Soc* 2016;16:294-7.

Access this article online	
Quick Response Code: 	Website: <a href="http://www.j-ips.org">www.j-ips.org</a>
	DOI: 10.4103/0972-4052.167942

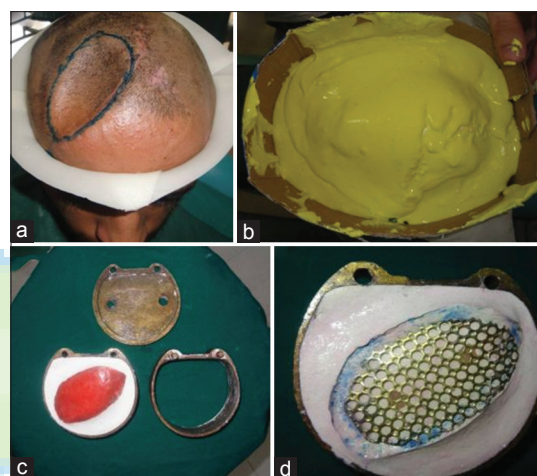
removal of crushed bone pieces. The patient was evaluated both clinically and radiographically. The radiological investigations included X-ray of the skull (anteroposterior view) and lateral view supplemented with computed tomography scan for defining the site and size of the defect [Figure 1]. All the necessary preoperative investigations were carried out. In spite of today's era being one of computer aided biomanufacturing, a computer-aided design/computer-aided manufacturing prototype was deemed unfeasible as the patient desired an economically viable and cost-effective solution. We thus decided to fabricate the PMMA resin prosthesis reinforced with titanium mesh (1.5 mm mesh, SK Surgicals, Pune) with the help of a prosthodontist. A patch test was carried out in the patient planned for reconstruction with polymethacrylate resin plate to rule out any hypersensitivity reaction. The defect was marked on the scalp [Figure 2a] and an impression of the defect was made [Figure 2b]. A cast was made with the help of dental stone. This was followed by making a wax-up of the defect and reinforcing it with a titanium mesh [Figure 2c]. Fabrication of acrylic cranial plate prosthesis the processing was carried out in a water bath at 168°F for 12 h and boiled for 30 min to ensure a complete cure and maximum reduction of free monomer [Figure 2d]. The prosthesis was then sterilized by soaking for 48 h in 2% glutaraldehyde solution. The patient's head was clean shaven prior to surgery. The frontal defect was exposed through the existing scar [Figure 3a]. Hemostasis was achieved. The PMMA resin implant reinforced with titanium mesh was then fixed to the defect with 2 mm titanium mini plates [Figure 3b and c]. The wound was closed in layers [Figure 3d]. The patient was followed up for a period of 6 months during which no complications were seen.

## DISCUSSION

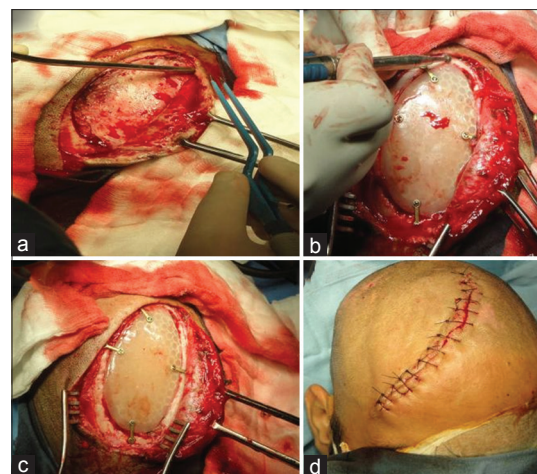
Reconstruction of skull defects is technically challenging, but can be achieved with the use of biological tissue, such as the split calvarial bone graft, bone harvested from the iliac crest/posterior wall of the sinus, or with artificial materials such as the three-dimensional titanium mesh.<sup>[6-8]</sup> The advantages of reconstruction with autologous bone include a lower incidence of graft loss than occurs with alloplastic material. Also, exposure and infection of the autologous bone can sometimes be managed without complete graft loss, whereas, when alloplastic materials become exposed or infected, often the only choice is removal of the foreign material<sup>[9,10]</sup> (exceptions are porous polyethylene sheet [Medpor] allografts, as their infection can be managed by intravenous antibiotics). Although, calvarial bone grafts are used today with great success for reconstructions of skull defects there are certain limitations for their use such as the limited size of graft availability and damage to the inner table or dura during harvest. Correction



**Figure 1:** Preoperative computed tomography scan showing the defect



**Figure 2:** Prosthetic work-up of the patient (a) Marking of defect on scalp, (b) impression of defect being taken by alginate, (c) wax-up of the defect and reinforcing it with titanium mesh, and (d) fabrication of acrylic prosthesis for cranial defect



**Figure 3:** Intraoperative procedure (a) Exposure of the cranial defect through existing scar, (b and c) fixation of the cranial prosthesis to the defect with titanium miniplates and screws, and (d) wound closure in layers

of large calvarial defects with autografts may also be quite time consuming.<sup>[9]</sup> The ideal substitute for undertaking cranioplasty must be biocompatible, strong, and lightweight; it must be malleable, to precisely fit even complicated cranial defects, nonmagnetic, chemically inert; radiolucent; nonferromagnetic; readily available; inexpensive and easily secured, and must have long-term stability. Alloplastic implants have the advantage of being readily available, easy to handle and shape and undergo minimal resorption; however, alloplastic implants are permanent foreign bodies that are susceptible to infection and exposure over time. In our case, we used a customized PMMA implant which was impregnated with titanium mesh for reconstruction of the cranial defect. A customized PMMA implant is preferred as there is no heat on polymerization and no excess liquid monomer which might irritate and damage the underlying structures.<sup>[11]</sup> Despite the increase in the number of biomaterials available for replacing areas of bone absence, the high cost continues to be a factor to consider. As a result, today, PMMA is still the cheapest and easiest material to obtain in addition to being easy to use.<sup>[12]</sup> It is the most commonly used alloplastic material for cosmetic and reconstructive surgeries as it is a poor conductor of heat and is highly resistant to compressive and torsional forces. PMMA is also radiolucent and noncarcinogenic.<sup>[13]</sup> In recent literature, Goyal and Goyal demonstrated the posttraumatic restoration of the large cranial defect with alloplastic heat-cure PMMA resin material in the Indian subcontinent albeit without the use of titanium mesh.<sup>[14]</sup> Disadvantages of PMMA include:<sup>[15,16]</sup>

- Higher rate of infection than autogenous bone
- Low composite tensile displacement profile
- Smooth surface characteristics that prevent tissue ingrowth
- Contraindicated in children as they do not accompany the growth of cranial skeleton.

The PMMA resin prosthesis imparted a suitable contour and was reinforced with a titanium mesh to impart rigidity and stability. Titanium mesh was used in conjunction with PMMA because we believe the PMMA prosthesis restores the contour of the frontal bone more esthetically and appropriately as opposed to titanium mesh alone. A titanium cranioplasty alone would not have given adequate bulk and contour to the cranium and takes 1–2 months to make compared with the modified acrylic cranioplasty which is cheap and immediately available.<sup>[17]</sup> The advantages of the titanium mesh are that it is malleable, biocompatible, thin, and involves no donor site morbidity, unlike autogenous bone grafts. Another advantage of titanium is its nonferromagnetic capacity which permits the safe examination in magnetic resonance imaging high field, useful for long-term follow-up of the patients. The disadvantages of employing a titanium mesh for reinforcement are an increased cost as opposed to using PMMA alone and the risk of infection. However, in our review of the literature, titanium mesh when

employed in craniofacial repair demonstrated to have a low rate of graft infection when compared with alternatives such as autogenous bone, autoclaved bone, and PMMA.<sup>[5,18]</sup> By way of example, Matsuno *et al.* found the rate of infection in delayed cranioplastias to be 25.9% for autogenous bone and only 2.6% for titanium mesh.<sup>[19]</sup>

## CONCLUSION

PMMA resin reinforced with titanium mesh remains a useful alternative to autogenous bone grafts for reconstruction of cranial defects. Appropriate case selection and the risk to benefit ratio should be taken into consideration before selecting any material for complex cranial reconstruction. This was a joint effort involving coordination between the Departments of Maxillo-Facial Surgery, Anesthesiology, Neurosurgery, and Maxillofacial Prosthodontics. The surgery was planned and executed by the Neurosurgeon and Maxillofacial Surgeon under hypotensive anesthesia while the prosthodontist was instrumental in the successful fabrication of a well contoured prosthesis. This coordination is a must for tackling such cases.

## Financial support and sponsorship

Nil.


## Conflicts of interest

There are no conflicts of interest.

## REFERENCES

1. Haug RH, Adams JM, Conforti PJ, Likavec MJ. Cranial fractures associated with facial fractures: A review of mechanism, type, and severity of injury. *J Oral Maxillofac Surg* 1994;52:729-33.
2. Bandyopadhyay CT, Thapliyal CG, Dubey CA. Reconstruction of cranial defects in armed forces personnel – Our experience. *MJAFI* 2005;61:36-40.
3. Eppley BL, Kilgo M, Coleman JJ 3<sup>rd</sup>. Cranial reconstruction with computer-generated hard-tissue replacement patient-matched implants: Indications, surgical technique, and long-term follow-up. *Plast Reconstr Surg* 2002;109:864-71.
4. Schwabegger AH, Rainer C, Laimer I, Huemer GM. Hemispheric brain volume replacement with free latissimus dorsi flap as first step in skull reconstruction. *Microsurgery* 2005;25:325-8.
5. Kuttenger JJ, Hardt N. Long-term results following reconstruction of craniofacial defects with titanium micro-mesh systems. *J Craniomaxillofac Surg* 2001;29:75-81.
6. Gil Z, Abergel A, Leider-Trejo L, Khaff A, Margalit N, Amir A, *et al.* A comprehensive algorithm for anterior skull base reconstruction after oncological resections. *Skull Base* 2007;17:25-37.
7. Ilankovan V, Jackson IT. Experience in the use of calvarial bone grafts in orbital reconstruction. *Br J Oral Maxillofac Surg* 1992;30:92-6.
8. Ducic Y. Titanium mesh and hydroxyapatite cement cranioplasty: A report of 20 cases. *J Oral Maxillofac Surg* 2002;60:272-6.
9. Sanan A, Haines SJ. Repairing holes in the head: A history of cranioplasty. *Neurosurgery* 1997;40:588-603.
10. Earley MJ, Green MF, Milling MA. A critical appraisal of the use of free flaps in primary reconstruction of combined scalp and calvarial cancer defects. *Br J Plast Surg* 1990;43:283-9.
11. van Gool AV. Prefomed polymethylmethacrylate cranioplasties: Report of 45 cases. *J Maxillofac Surg* 1985;13:2-8.

12. Marchac D, Greensmith A. Long-term experience with methylmethacrylate cranioplasty in craniofacial surgery. *J Plast Reconstr Aesthet Surg* 2008;61:744-52.
13. Moreira-Gonzalez A, Jackson IT, Miyawaki T, Barakat K, DiNick V. Clinical outcome in cranioplasty: Critical review in long-term follow-up. *J Craniofac Surg* 2003;14:144-53.
14. Goyal S, Goyal MK. Restoration of large cranial defect for cranioplasty with alloplastic cranial implant material: A case report. *J Indian Prosthodont Soc* 2014;14:191-4.
15. Cho YR, Gosain AK. Biomaterials in craniofacial reconstruction. *Clin Plast Surg* 2004;31:377-85, v.
16. Gosain AK; Plastic Surgery Educational Foundation DATA Committee. Biomaterials for reconstruction of the cranial vault. *Plast Reconstr Surg* 2005;116:663-6.
17. Werndle MC, Crocker M, Zoumprouli A, Papadopoulos MC. Modified acrylic cranioplasty for large cranial defects. *Clin Neurol Neurosurg* 2012;114:962-4.
18. Gear AJ, Lokeh A, Aldridge JH, Migliori MR, Benjamin CI, Schubert W. Safety of titanium mesh for orbital reconstruction. *Ann Plast Surg* 2002;48:1-7.
19. Matsuno A, Tanaka H, Iwamuro H, Takanashi S, Miyawaki S, Nakashima M, *et al.* Analyses of the factors influencing bone graft infection after delayed cranioplasty. *Acta Neurochir (Wien)* 2006;148:535-40.



### “Quick Response Code” link for full text articles

The journal issue has a unique new feature for reaching to the journal’s website without typing a single letter. Each article on its first page has a “Quick Response Code”. Using any mobile or other hand-held device with camera and GPRS/other internet source, one can reach to the full text of that particular article on the journal’s website. Start a QR-code reading software (see list of free applications from <http://tinyurl.com/yzlh2tc>) and point the camera to the QR-code printed in the journal. It will automatically take you to the HTML full text of that article. One can also use a desktop or laptop with web camera for similar functionality. See <http://tinyurl.com/2bw7fn3> or <http://tinyurl.com/3ysr3me> for the free applications.