

## Case Report

# Managing maxillary proclination with novel designed angulated implants

Swati Ahuja, Nicholas Egbert<sup>1</sup>, Vinay Jain, David Cagna

Department of Prosthodontics, College of Dentistry, University of Tennessee Health Science Center, Memphis, Tennessee, <sup>1</sup>Private Practice, Salt Lake City, Utah, USA

### Abstract

Implant-supported removable dental prostheses may be supported by a variety of splinted (bar and clip) attachment systems or nonsplinted abutment-based attachments (ball, magnets, and resilient stud attachments such as locators [Zest Anchors], ERA [Sterngold], and nonresilient-stud attachments such as ANKYLOS SynCone [Dentsply Implants]). Nonsplinted attachments are preferred as they are more economical, less technique sensitive, easier to clean, repair, and maintain than splinted (bar and clip) attachment systems, but they work favorably only when implants in the arch are placed parallel to each other. Often implants in the anterior maxilla have to be placed with a labial inclination (due to the proclination of the premaxilla), resulting in lack of parallelism between the anterior and posterior implants, making it challenging to fabricate a removable dental prostheses supported by nonsplinted attachments, and necessitating the use of angled abutments. Recently, a novel implant design with a 12° restorative platform angulation has been introduced by Southern Implants (Co-axis, Keystone Dental, Inc., Burlington, MA, USA). These new angulated implants aid in minimizing the divergence between the anterior and posterior maxillary implants without using angled abutments. The purpose of this article was to report a case utilizing the novel angulated implants (Co-axis, Keystone Dental, Inc., Burlington, MA, USA) in the premaxilla for fabrication of maxillary removable dental prostheses supported and retained by nonsplinted attachments.

**Key Words:** Angle correction, angled abutment, Co-axis, divergent, implants, novel design

### Address for correspondence:

Dr. Swati Ahuja, 875, Union Ave, Memphis, Tennessee 38103, USA. E-mail: sahuja@uthsc.edu

**Received:** 27<sup>th</sup> January, 2015, **Accepted:** 09<sup>th</sup> August, 2016

### INTRODUCTION

Nonsplinted attachments (such as ERA or locators) are preferred as attachments for removable dental prostheses as they are more economical, less technique sensitive, easier to clean, repair, and maintain than splinted (bar and clip) attachment systems, but they work favorably only when implants in the arch are placed parallel to each other.<sup>[1-3]</sup>

However, implants in the anterior maxilla may have to be placed with a labial inclination (tilted) owing to the proclination of the premaxilla making it challenging to achieve parallelism between anterior and posterior implants, and thereby necessitating the use of angled abutments.<sup>[4]</sup>

A novel implant design, with 12° and 24° (available in US and Europe) prosthetic axis correction, has been introduced

Access this article online	
Quick Response Code:	Website: <a href="http://www.j-ips.org">www.j-ips.org</a>
	DOI: 10.4103/0972-4052.203196

This is an open access article distributed under the terms of the Creative Commons Attribution-NonCommercial-ShareAlike 3.0 License, which allows others to remix, tweak, and build upon the work non-commercially, as long as the author is credited and the new creations are licensed under the identical terms.

**For reprints contact:** [reprints@medknow.com](mailto:reprints@medknow.com)

**How to cite this article:** Ahuja S, Egbert N, Jain V, Cagna D. Managing maxillary proclination with novel designed angulated implants. J Indian Prosthodont Soc 2017;17:203-6.

recently by Southern Implants (Co-axis, Keystone Dental, Inc., Burlington, MA, USA). These implants permit correction of the restorative trajectory of the tilted implant without the use of angled abutments.<sup>15-71</sup> The purpose of this article was to report a case utilizing the novel implants in the premaxilla for fabricating a nonsplinted attachment-supported maxillary removable dental prostheses.

### CASE REPORT

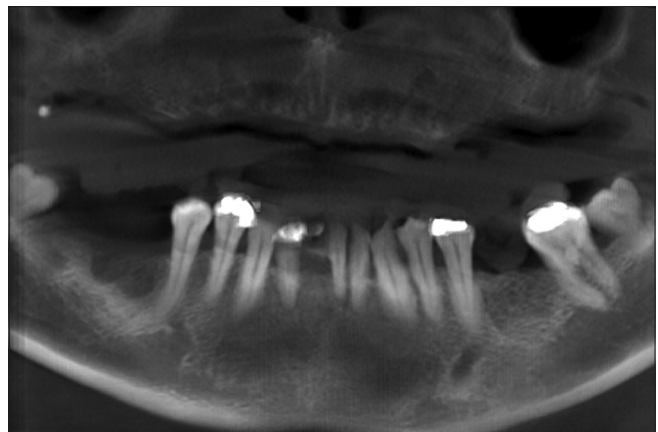
A 45-year-old Hispanic male presented to our clinic with a chief complaint of difficulty in chewing food and discomfort associated with increased palatal coverage of existing maxillary restoration. The patient had a noncontributory medical history and was edentulous in the maxillary arch and partially edentulous in the mandibular arch, missing tooth #17, #18, #19, and #32 (lost 2 years ago due to caries and periodontal disease) [Figure 1]. The patient had received a complete denture in the maxillary arch and a serviceable cast partial denture in the mandibular arch. The oral hygiene of the patient was fair, and he desired a new and an “easy to maintain” maxillary restoration. The following treatment plan was presented to the patient after a thorough consideration of his clinical condition and oral hygiene compliance, and his preferences were:

- Planning and placement of 5–6 implants in the maxilla with optimal anteroposterior spread and
- Fabrication of an open palate maxillary removable dental prostheses supported by nonsplinted attachments.

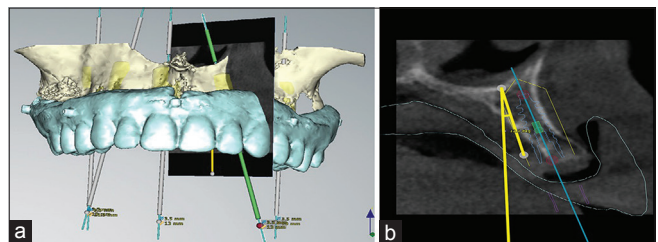
The treatment was initiated on receipt of the patient consent. The procedural steps are described below:

#### Acquiring cone-beam computed tomography scan and planning implant placement

The cone-beam computed tomography (CBCT) scan revealed the proclination of the premaxilla which would require the anterior implants to be placed with a labial inclination, resulting in divergence between anterior and posterior implants of approximately 12° [Figure 2a and b]. This would necessitate the use of bar and clip attachment system or angled abutments, resulting in insufficient restorative space available for the definitive prosthesis (as depicted by the CBCT). Hence, novel-designed angulated implants (Co-axis, Keystone Dental, Inc., Burlington, MA, USA) were planned for the anterior maxilla [Figure 3]. A total of five implants were planned, of which three implants in the anterior maxilla (#6-Keystone 12° Co-Axis, 4.0 × 13 ex-hex, #8-Keystone 12° Co-Axis, 4.0 × 13 ex-hex, and #11-Keystone 12° Co-Axis, 4.0 × 13 ex-hex) and two in the posterior maxilla (#3 and #14 Nobel Active 4.3 × 11.5, Nobel Biocare, Yorba Linda, CA, USA).



**Figure 1:** Panoramic radiograph depicting edentulous maxillary arch and partially edentulous mandibular arch



**Figure 2:** (a) Cone beam computed tomography scan demonstrating maxilla, radiographic guide and divergent anterior and posterior implants, (b) premaxilla with 12° facial inclination, demonstrated with yellow lines



**Figure 3:** Novel designed angulated implant demonstrating 12° angle correction at implant platform

#### Implant surgery

It is critical to time the rotation of the novel angulated implants accurately so that the angle correction occurs at the desired depth. A dimple on the facial aspect of the implant mount is provided by the manufacturers to guide the orientation of the implant.

Under moderate, intravenous sedation and local anesthesia, the implants were placed in the planned locations using a

three-dimensional surgical guide (NobelProcera, Mahwah, NJ, USA) [Figures 4-6]. The existing maxillary denture was adjusted, relieved and relined with a soft reline material (MucoSoft, Parkell, Inc., Edgewood, NY, USA).

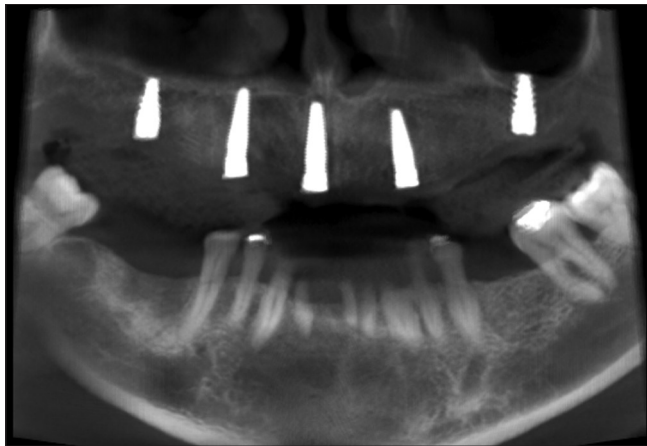
### Definitive prostheses placement

The implants were allowed to heal for 4 months. Restoration of the novel designed implants follows standard prosthetic fabrication procedures as the prosthetic platform is treated as a standard implant. Definitive maxillary removable dental prosthesis with a metal framework<sup>[8]</sup> [Figure 7] and open palate design (supported by nonsplinted attachments) was fabricated for the patient following current best-practice procedures. Locator abutments were attached to the implants intraorally and torqued as per the manufacturer's recommendations [Figure 8]. The prosthesis was tried, its

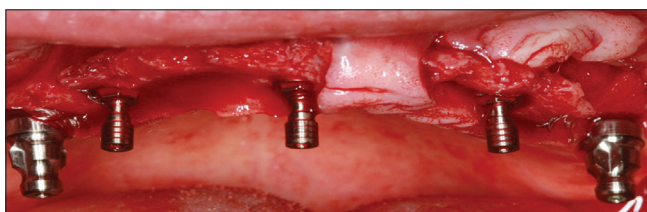
fit and the occlusion were evaluated and adjusted, and it was then finished, polished, and delivered to the patient. The patient was given detailed home care instructions to maintain the prostheses and oral hygiene and placed on a biannual recall schedule.<sup>[2]</sup> [Figure 9].

### DISCUSSION

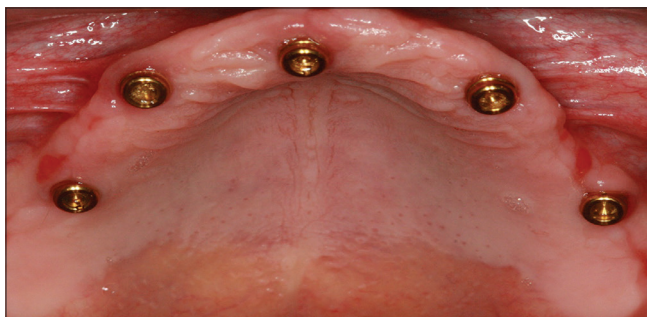In this patient, the CBCT scan confirmed the proclination of the premaxillary bone which would result in divergence between anterior and posterior implants. However, the divergence between anterior and posterior implants affects the retention and the longevity of all nonsplinted attachments (including locators).<sup>[9]</sup> Hence, to avoid the use of nonsplinted attachments on diverging implants and resulting frequent maintenance and recall visits, angulated implants were used to first correct the implant divergence



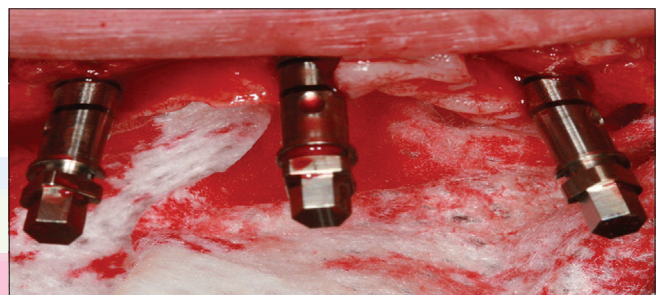
**Figure 4:** Panoramic radiograph depicting placement of five maxillary implants



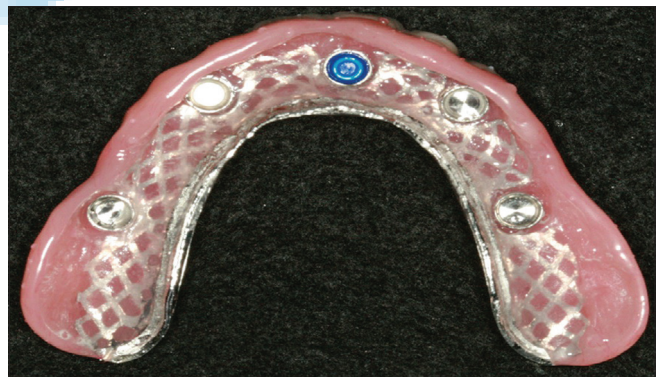**Figure 6:** Abutment screws depict the correction of restoration trajectory of three angulated anterior implants



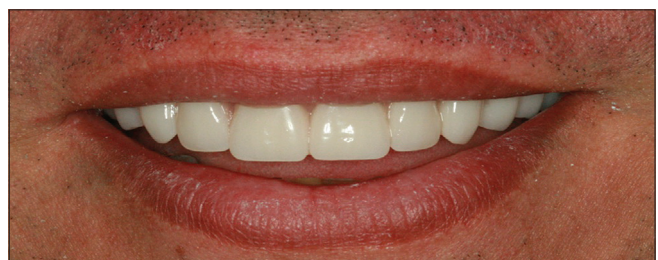**Figure 8:** Locator abutments attached to implants



**Figure 5:** Implant mount-implant assembly (demonstrating proclination of premaxilla) with dimples oriented facially



**Figure 7:** Metal framework incorporated in maxillary implant-supported removable dental prostheses



**Figure 9:** Patient's smile with definitive prostheses

and then locator attachments were used for retaining and supporting the prosthesis.

Eger *et al.*<sup>[10]</sup> have stated that good function and esthetics can be achieved by restoring tilted implants with angled abutments. However, angled abutments increase the cost of the prosthesis and are technique sensitive and space intensive.<sup>[10]</sup> Use of angled abutments when there is insufficient restorative space may lead to physiologically inappropriate contours, structurally weak prostheses, poor esthetics, encroachment into freeway space, and/or suboptimal retention and stability of the prosthesis.<sup>[10]</sup> To overcome these issues, the novel designed angulated implants were planned in the anterior maxillary region for this patient. These implants aided in achieving multi-implant parallelism and optimizing the anteroposterior spread, without the need to use angled abutments. Studies conducted by Brown and Payne<sup>[6]</sup> and Vandeweghe *et al.*<sup>[7]</sup> report the successful use of these novel implants for immediate replacement and immediate restoration of single teeth in the esthetic zone, but they are short-term studies with only 1 year of follow-up time. These implants are currently being used for both single and multiunit fixed and removable implant restorations. More randomized controlled studies and long-term clinical trials are necessary to evaluate the durability of these implants and their restoration.

#### Declaration of patient consent

The authors certify that they have obtained all appropriate patient consent forms. In the form the patient(s) has/have given his/her/their consent for his/her/their images and other clinical information to be reported in the journal. The patients understand that their names and initials will not

be published and due efforts will be made to conceal their identity, but anonymity cannot be guaranteed.

#### Financial support and sponsorship

Nil.

#### Conflicts of interest

There are no conflicts of interest.

#### REFERENCES

1. Ahuja S, Cagna DR. Classification and management of restorative space in edentulous implant overdenture patients. *J Prosthet Dent* 2011;105:332-7.
2. Ahuja SA, Wicks R, Selecman A. Fabrication of new restorations with a consideration of oral hygiene. *J Indian Prosthodont Soc* 2016;16:307-10.
3. Sadowsky SJ. The implant-supported prosthesis for the edentulous arch: Design considerations. *J Prosthet Dent* 1997;78:28-33.
4. Schneider AL, Kurtzman GM. Restoration of divergent free-standing implants in the maxilla. *J Oral Implantol* 2002;28:113-6.
5. Kurtzman GM, Dompkowski DF, Mahler BA, Howes DG. Off-axis implant placement for anatomical considerations using the co-axis implant. *Inside Dent* 2008;12:96-102.
6. Brown SD, Payne AG. Immediately restored single implants in the aesthetic zone of the maxilla using a novel design: 1-year report. *Clin Oral Implants Res* 2011;22:445-54.
7. Vandeweghe S, Cosyn J, Thevissen E, Van den Berghe L, De Bruyn H. A 1-year prospective study on Co-Axis implants immediately loaded with a full ceramic crown. *Clin Implant Dent Relat Res* 2012;14 Suppl 1:e126-38.
8. Ahuja S, Jain V, Cagna D, Wicks R. Fabricating a mandibular implant supported overdenture with a suspended framework. *J Indian Prosthodont Soc* 2013;13:132-6.
9. Al-Ghaffi SA, Michalakis KX, Hirayama H, Kang K. The *in vitro* effect of different implant angulations and cyclic dislodgement on the retentive properties of an overdenture attachment system. *J Prosthet Dent* 2009;102:140-7.
10. Eger DE, Gunsolley JC, Feldman S. Comparison of angled and standard abutments and their effect on clinical outcomes: A preliminary report. *Int J Oral Maxillofac Implants* 2000;15:819-23.