

## Case Report

# Assessment of implant stability during various stages of healing placed immediately following extraction in an overdenture situation

Ashwin Thomas Koshy, T. Aby Mathew, Nicholas Mathew, Angel Mary Joseph

Department of Prosthodontics and Crown and Bridges and Implantology, Pushpagiri College of Dental Sciences, Thiruvalla, Pathanamthitta, Kerala, India

### Abstract

To assess the implant stability during different stages of healing in an immediate loaded implant soon after extraction. A 73-year-old female came with a chief complaint of bad smell and irritation in her lower front gum region. On examination, she was found to be completely edentulous in the maxillary arch and partially edentulous in the mandibular arch with only the canines present bilaterally. The posterior mandibular ridge was severely resorbed and hence could not be treated with a conventional mandibular complete denture. Considering the age of the patient and the preference of only a single surgical visit, we decided to plan for a conventional maxillary denture against an implant supported mandibular overdenture with two implants placed immediately after extraction of canines. The stability of these implants was assessed during the early phases of healing with the help of a resonance frequency analysis method (RFA) using Osstell ISQ™. During the healing phase, implant stability quotient (ISQ) values decrease by 4–5 values after installation with the lowest values at the 1<sup>st</sup> week postplacement. Following this, the ISQ values increased steadily for all implants up to 16 weeks. No significant differences were noted over time. At placement, the mean ISQ values at 33 and 43 regions were 74 and 75.2, respectively. The mean lowest ISQ values recorded at the 1<sup>st</sup> week were 58.8 and 65.4, respectively. At 16 weeks, the mean ISQ values were 70.5 and 67.9, respectively. The survival of such immediately placed implants, which are later used as overdenture supported implants, are highly predictable when the surgical and prosthetic part is done meticulously. However, there needs future studies oriented to understand better the healing pattern of immediately placed implants in extraction sockets, which would guide the clinician with the optimal loading time.

**Key Words:** Immediately placed implants, implant supported overdenture, resonance frequency analysis (RFA)

### Address for correspondence:

Dr. Ashwin Thomas Koshy, Pushpagiri College of Dental Sciences, Thiruvalla, Pathanamthitta - 689 107, Kerala, India. E-mail: [thomashwin@gmail.com](mailto:thomashwin@gmail.com)

**Received:** 02<sup>nd</sup> September, 2015, **Accepted:** 19<sup>th</sup> September, 2015

## INTRODUCTION

According to the WHO, edentulous patients are considered as “physically impaired.” The classic treatment for such patients

would be to fabricate conventional complete dentures. Patients who are treated with such dentures often complain of the instability of their lower dentures. These dentures are fully

Access this article online	
Quick Response Code:	Website: <a href="http://www.j-ips.org">www.j-ips.org</a>
	DOI: 10.4103/0972-4052.176530

This is an open access article distributed under the terms of the Creative Commons Attribution-NonCommercial-ShareAlike 3.0 License, which allows others to remix, tweak, and build upon the work non-commercially, as long as the author is credited and the new creations are licensed under the identical terms.

**For reprints contact:** [reprints@medknow.com](mailto:reprints@medknow.com)

**How to cite this article:** Koshy AT, Mathew TA, Mathew N, Joseph AM. Assessment of implant stability during various stages of healing placed immediately following extraction in an overdenture situation. *J Indian Prosthodont Soc* 2017;17:74-9.

tissue borne and transmit all of the functional forces onto the residual ridge thereby resulting in rapid loss of the remaining alveolar ridge.<sup>[1]</sup> To counteract this problem, denture adhesives came into the market these adhesives offered a temporary solution for the poor retention of these dentures with underlying etiology remaining unsolved.

An implant supported overdenture is a simple and an excellent treatment alternative to the problem of a loose, unstable denture thereby restoring masticatory function, speech, and the confidence level of the patient. Although the initial expense for an overdenture is high when compared to conventional denture, on a long run, an implant overdenture using ball attachments have proved to be more retentive and cost-effective.<sup>[2]</sup> These dentures receive their support from the mucosa as well as from the implants. Implants placed immediately after extraction carries the advantages of reduced treatment time and reduced number of surgical experiences. The success of such implants depends on the underlying physiologic changes that occur at the bone-implant interface.<sup>[3]</sup> A sound understanding of these biological changes that takes place at the bone-implant contact interface during the early phases of healing would guide the clinician from premature loading, which may result in implant failure.

Different methods have been used to measure implant stability and bone quality, namely percussion testing, histological analysis, radiographs, insertion torque, cutting resistance, periometer, and resonance frequency analyzer. One of the main limitations of some of these methods were its invasive nature during the assessment of implant stability. If an implant is subjected to micromovement during the healing phase, normal healing would be disrupted resulting in the formation of a fibrous capsule around this interface and subsequent implant failure.<sup>[4,5]</sup> The RFA method is a noninvasive technique and uses the principle of “tuning fork.” It is a bending test of the bone implant system, in which a microscopic bending force is applied by exciting a transducer (Smart Peg), that is fixed rigidly onto the implant fixture.<sup>[6]</sup> The RFA has shown to correlate with clinical assessments and the osseous changes reflective of the metabolic activity following implant placement.<sup>[3]</sup>

This article involves the stability assessment of immediately placed implants in the extraction sockets during the early phases of healing with the help of the resonance frequency analysis (RFA) Osstell ISQ™ followed by a detailed description of a simple way to fabricate an implant-supported overdenture using ball attachments.

## CASE REPORT

A female patient aged 73 years visited the Department of Prosthodontics and Implantology, Pushpagiri College of Dental Science, Kerala, India with a chief complaint of bad

smell and irritation in her lower front gum region [Figure 1]. She gave a history of hypertension and hypothyroidism and was under medication for the same. The patient was wearing a maxillary conventional denture for the past 15 years. In the mandibular anterior region, she had a fixed bridge receiving its support from the right and left canine teeth. Posteriorly, she had a removable acrylic temporary denture with clasps extending onto the canines bilaterally [Figure 2]. Anterior and posterior teeth presented in cross bite relation. The panoramic view revealed a severe bone resorption on the mandibular molar area and a combination syndrome-like appearance on the mandibular anterior area [Figure 3]. The two canines revealed poor radicular bone support and hence could not be retained for a tooth-supported overdenture. Therefore, a simple, cost-effective treatment was to go for a conventional denture in the maxilla, and an implant-supported overdenture in the mandible supported by ball attachments. Informed consent was obtained from the patient.

## Clinical procedure

The acrylic bridge, which did not follow the ridge contour, had to be removed first [Figure 4] as it harbored plaque and food debris resulting in gingival inflammation. Fabrication of an interim denture: Primary impression was made using alginate impression material (Imprint, 3M ESPE, India). Special trays were fabricated with self-cure acrylic (Orthoplast, India) on the mandibular cast using the Campagna technique relieving space for the canines.<sup>[7]</sup> Border molding was done with green stick compound (DPI, Pinnacle Tracing Sticks, India), and stone casts were poured. Occlusal rims were constructed on the temporary denture base, and jaw relation was recorded retaining the canines. In the following visits, try in was completed. The dentures were fabricated and kept ready for the insertion after implant placement.

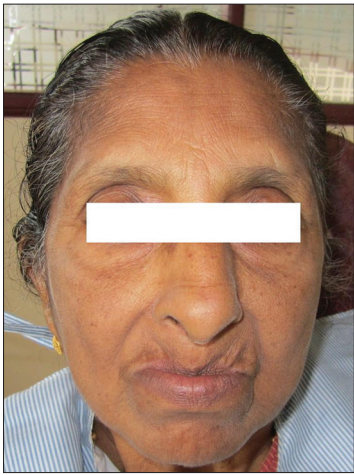## Extraction and placement of implant

After administering local anesthesia, atraumatic extraction of the canines was done. Following strict aseptic measures, two implants of 4.2 mm × 10 mm (Touareg S, Adin, Israel) were placed immediately after extraction of the two canines into the socket. The implant stability was assessed using the resonance frequency analysis (Osstell implant stability quotient [ISQ], Gothenburg, Sweden) [Figure 5].

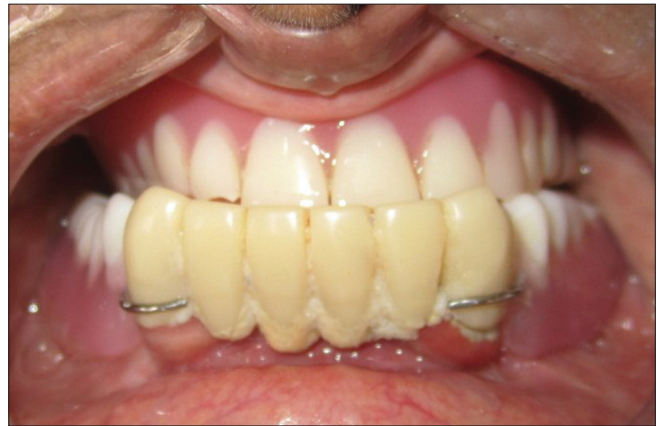Healing abutments were placed to facilitate the subsequent ISQ reading during the various stages of healing and to keep the implants transgingival [Figure 6].

## Placing of provisional dentures

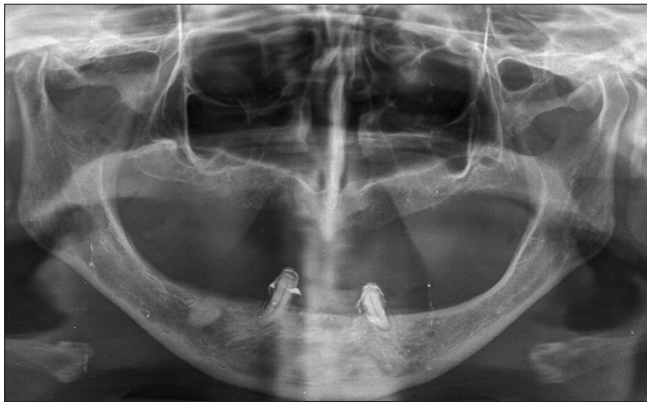Before placing the provisional dentures, it was made sure that there was adequate relief given such that there was no direct contact between the healing abutment and the acrylic denture base. This was done with the aim of preventing a direct impact onto the fixtures.



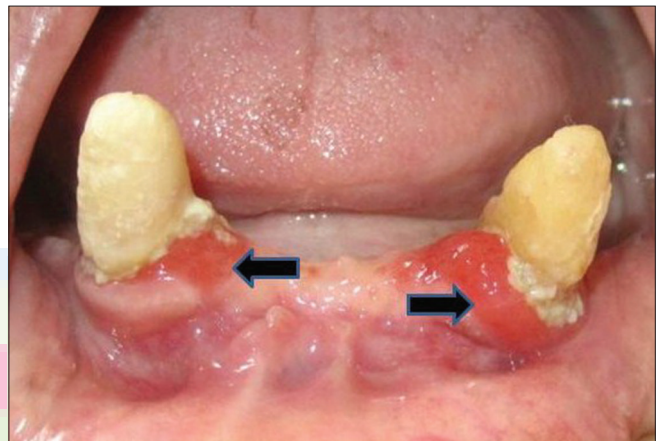
**Figure 1:** Pretreatment photograph - Note the lack of fullness of the upper lips and sunken cheeks



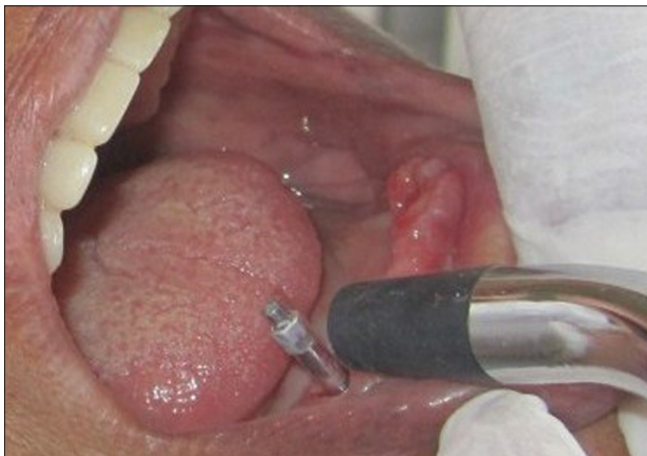**Figure 2:** Initial photo - Combination syndrome-like situation. Artificial teeth in cross bite relation



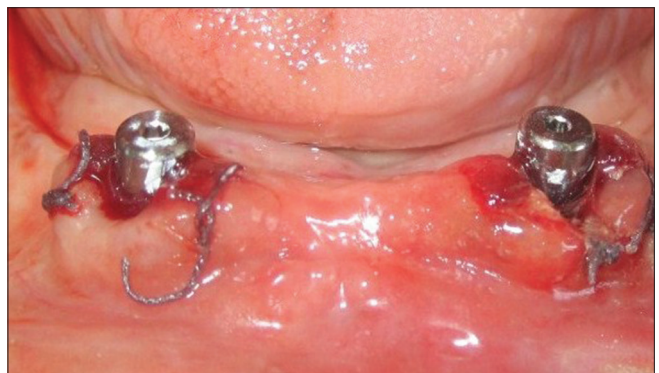**Figure 3:** Initial panoramic view - Lone standing mandibular canines with severe periodontitis and severe resorption in the mandibular molar region



**Figure 4:** After the acrylic bridge removal - The arrows indicate severe inflammation gingival inflammation in response to the ill-fitting bridge



**Figure 5:** Implant stability assessment using RFA, Osstell ISQ™ (resonance frequency analysis). During each assessment, the healing abutment has to be removed, and the smart peg mounted directly onto the fixture to facilitate the reading



**Figure 6:** Healing abutments are placed

the intaglio surface in relation to the canines was done with an intention to minimize any possibility of direct impact on to the implant fixtures. The patient was advised to follow the normal precautions following extraction of a tooth, and to keep the healing abutments clean with the help of a soft bristle brush.

*Implant stability assessment protocol*

The patient was recalled after the 1<sup>st</sup>, 2<sup>nd</sup>, 3<sup>rd</sup>, 4<sup>th</sup>, 6<sup>th</sup> week, and

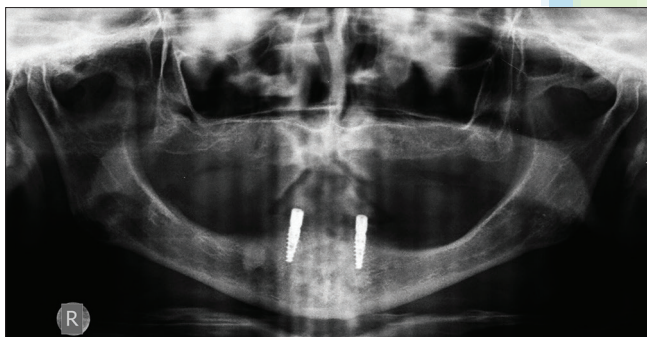
The denture occlusion was kept balanced with least pressure on the canine region. Gross reduction of denture base material on

at the end of 4 months. Each visit required the removal of the healing abutment and placement of the transducer (Smart Peg) to assess implant stability. The hand-held probe was directed onto the peg in three directions (labially, lingually, and mesially) and readings that appeared on the digital monitor were systematically recorded. The averages of these three values were noted, and the mean value was calculated at each interval. The soft tissue response and gingival health around the implant fixtures were found to be satisfactory.

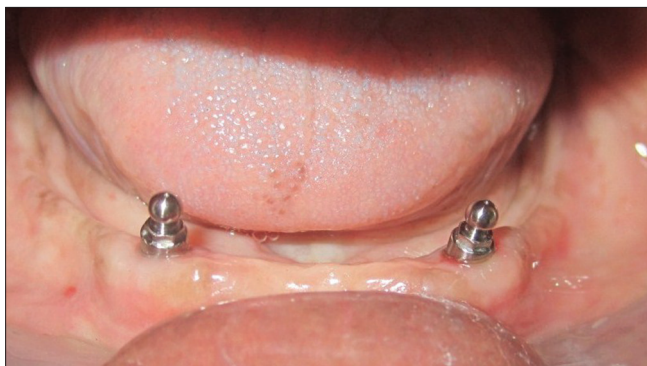*Final prosthesis*

At the end of 4 months, implant stability was assessed and found to be adequate for loading. Postoperative panoramic and intraoral periapical view [Figures 7 and 8] of the implants suggested the predictable levels of osseointegration. The final prosthesis was fabricated similar to the fabrication of the interim denture except for the fact that, instead of canines, it was the healing abutments in place.

Healing abutments were replaced with ball abutments [Figure 9]. The male portion of the attachment was placed into the denture base through the direct technique sequential placement of the attachment and is described using [Figures 10-14]. Table 1 reveals the ISQ values obtained during each interval. Occlusion was assessed in centric and protrusive movement and any deflective contact was eliminated. The patient was completely satisfied with her new dentures in terms of function and esthetics [Figures 15 and 16].



**Figure 7:** Postoperative panoramic view after 3 months




**Figure 9:** Healing abutments replaced with ball abutments. The gingival health restored

**DISCUSSION**

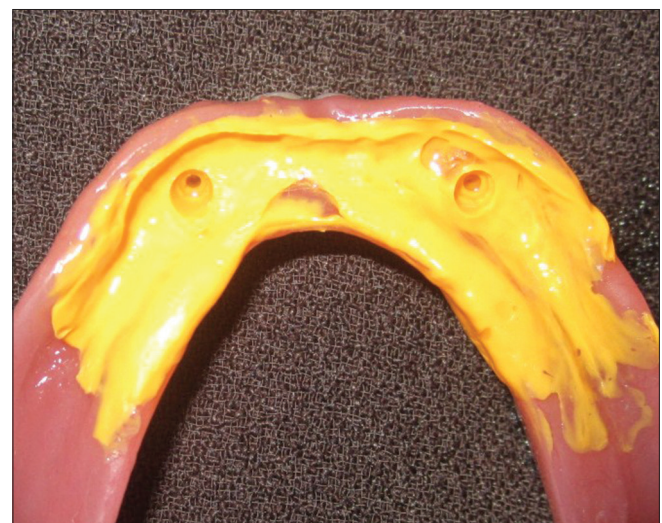The resonance frequency analysis (RFA) has proven to be a reliable indicator to assess the implant stability during the various stages of healing following implant placement.<sup>[1,8]</sup> The variation in ISQ values is reflective of the biologic changes at the bone implant interface. As there are not many clinical studies on stability assessment of implants placed in fresh

**Table 1: Mean implant stability quotient values of the two implants at a given time point**

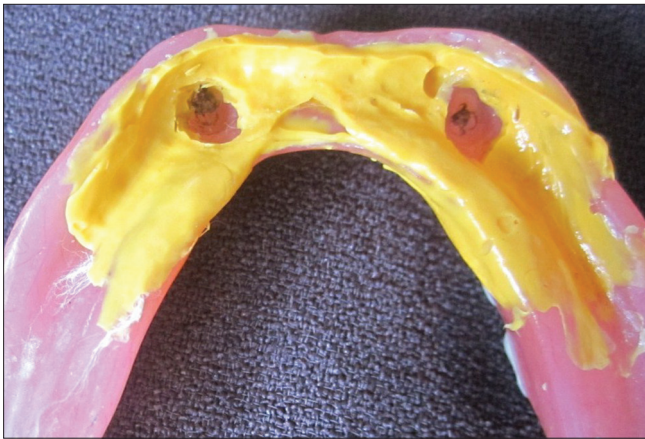
Time	Implant location	
	33 region (Touareg OS)	43 region (Touareg S)
Baseline	74	76
First week	58.75	69.5
Second week	64	65.75
Third week	63.75	65.5
Fourth week	66.5	64.5
Sixth week	68	67.5
Loading	70.5	67.9



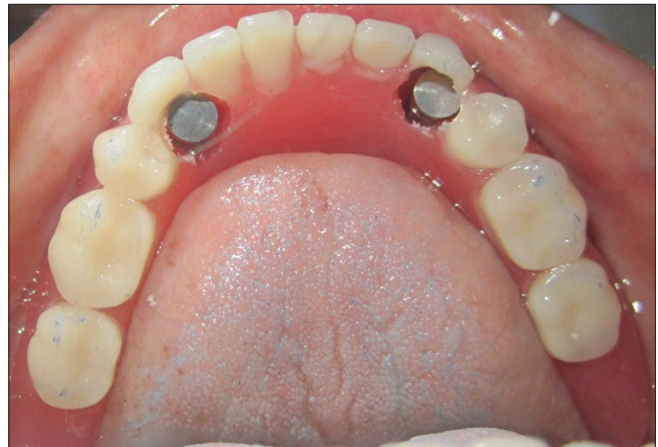**Figure 8:** Intraoral periapical view after 4 months. (a) 33 region and (b) 43 region



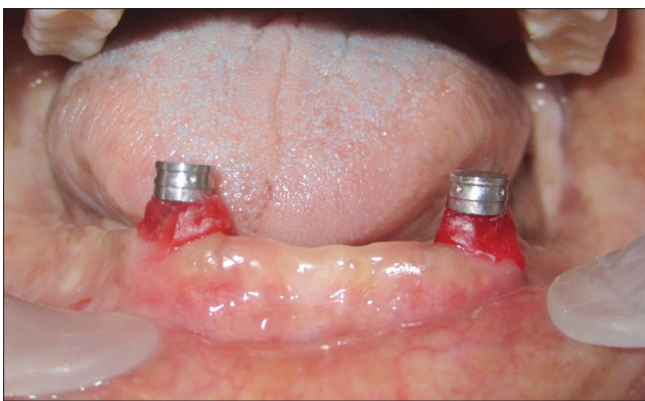**Figure 10:** A light body polyvinyl siloxane impression (Aqausil, Dentsply, India) was made to delineate the location of the ball abutments



**Figure 11:** A through pencil mark was made on the denture base



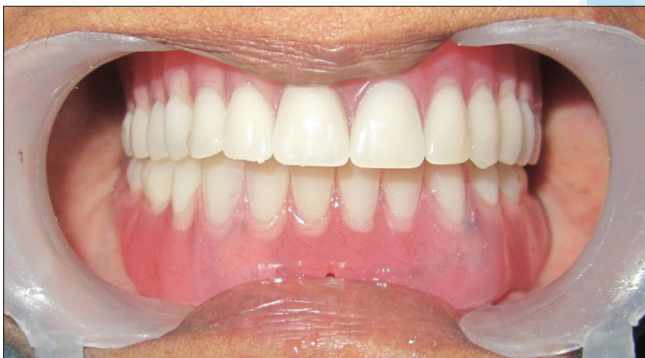**Figure 12:** Adequate relief given with the help of a straight bur was given such that there is no contact with the male component and the denture base during centric occlusion



**Figure 13:** The undercut created between the lower edge of the matrix and the retentive anchor abutment is blocked out with modeling wax

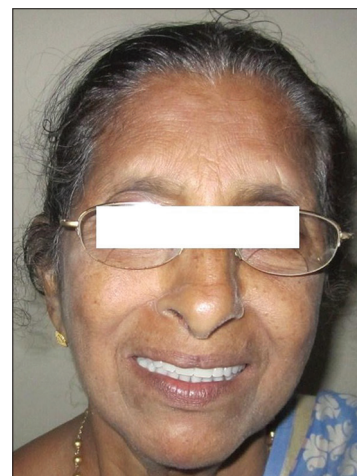

**Figure 14:** After incorporating the male portion into the denture base with self-cure acrylic. Voids existing between the matrix and the denture base are filled with acrylic, and the denture is finished and polished



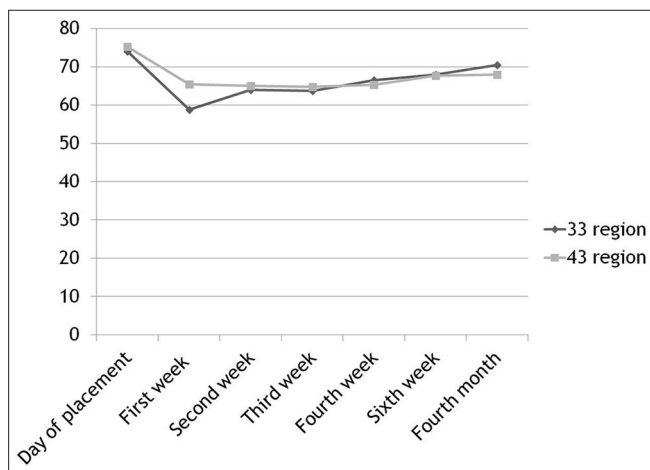
**Figure 15:** Postdenture insertion (frontal view)

extraction sockets, one of the intentions of this study was to assess the stability curve obtained in immediately placed implants during the early phases of healing. We observed a dip in the ISQ values in the 1<sup>st</sup> week following implant placement that later began to rise in the following weeks and reached a maximum at the end of 4 months [Figure 17]. These results, however, varied with the study conducted by West and Oates in 2007 in which he compared the stability of implants placed in native bone with that of differently designed implants (straight and tapered) placed immediately after extraction.<sup>[3]</sup> From this



**Figure 16:** Posttreatment photograph

study, they observed a maximum dip in the ISQ values in 4 weeks. This decrease in ISQ values represents the activity of osteoclasts during this phase. Understanding the pattern of



**Figure 17:** Diagram visualizing the mean implant stability quotient values obtained during the early phases of healing of implants placed directly into the extraction socket. Black line - 33 region and light gray line - 43 region

bone healing in such situation will prevent the dental surgeon from premature loading, which may end up in failure of the implants. The reason for such variations needs to be studied in depth with the help of randomized controlled trials directed in this aspect. One possible cause for this discrepancy between the two studies could be difference in the bone quality and the primary stability thus obtained, provided the procedure being done by an experienced prosthodontist.

Implants placed in fresh extraction sockets have a high rate of survival ranging between 93.9% and 100%.<sup>[9]</sup> The advantages of placing implants in fresh extraction sockets are a reduction in the overall treatment time, require fewer surgical procedures, reduced treatment cost, and prevention of initial bone loss. However, the placement of dental implants directly into the extraction sockets also poses certain challenges because of the diametrical discrepancy that may arise between the implant design and the extraction socket. Therefore, to achieve primary stability in such situations is more difficult as most of the retention would be from the bone apical region than the lateral walls of the socket. The implants placed in this case were about 3–5 mm beyond the apex, and the collar was placed close to the crestal bone, which ensured minimal bone loss (0–3 mm). This procedure was in line with the criteria for success of immediately placed implants enlisted by Arad and Chaushu in 1997.<sup>[9]</sup>

## CONCLUSION

After 4 months recall, it was concluded that an implant placed in an atraumatic extraction site with good initial stability has a survival chance of above 94%. The high RFA readings obtained in this case indicate the fact that if the provisional

denture is placed with proper relief on the implant site with a balanced occlusion, the chances of survival are more. This case report to assess the stability pattern of implants placed in fresh extraction sockets with the help of the resonance frequency analysis (RFA) during the early phases of healing indicates high success rates. The survival of such immediately placed implants, which are later used as overdenture supported implants, are highly predictable when the surgical and prosthetic part are done meticulously.

## Declaration of patient consent

The authors certify that they have obtained all appropriate patient consent forms. In the form the patient(s) has/have given his/her/their consent for his/her/their images and other clinical information to be reported in the journal. The patients understand that their names and initials will not be published and due efforts will be made to conceal their identity, but anonymity cannot be guaranteed. The RFA is an efficient method to test the implant stability during the early phases of healing in delayed and immediate implant placement situations.<sup>[10]</sup>

## Financial support and sponsorship

Nil.

## Conflicts of interest

There are no conflicts of interest.

## REFERENCES

- Shafie HR. Clinical and Laboratory Manual of Implant Overdentures. Oxford: Blackwell; 2007. p. 206-9.
- Feine JS, Carlsson GE. Implant Overdentures: The Standard of Care for Edentulous Patients. Illinois: Quintessence; 2003.
- West JD, Oates TW. Identification of stability changes for immediately placed dental implants. *Int J Oral Maxillofac Implants* 2007;22:623-30.
- Heller JG, Estes BT, Zaouali M, Diop A. Biomechanical study of screws in the lateral masses: Variables affecting pull-out resistance. *J Bone Joint Surg Am* 1996;78:1315-21.
- Meredith N. Assessment of implant stability as a prognostic determinant. *Int J Prosthodont* 1998;11:491-501.
- Ramakrishna R, Nayar S. Clinical assessment of primary stability of endosseous implants placed in the incisor region, using resonance frequency analysis methodology: An *in vivo* study. *Indian J Dent Res* 2007;18:168-72.
- Campagna SJ. An impression technique for immediate dentures. *J Prosthet Dent* 1968;20:196-203.
- Schwartz-Arad D, Laviv A, Levin L. Survival of immediately provisionalized dental implants placed immediately into fresh extraction sockets. *J Periodontol* 2007;78:219-23.
- Schwartz-Arad D, Chaushu G. The ways and wherefores of immediate placement of implants into fresh extraction sites: A literature review. *J Periodontol* 1997;68:915-23.
- Atieh MA, Alsabeeha NH, Payne AG, de Silva RK, Schwass DS, Duncan WJ. The prognostic accuracy of resonance frequency analysis in predicting failure risk of immediately restored implants. *Clin Oral Implants Res* 2014;25:29-35.