

## Case Report

# Rehabilitation of long-span Kennedy class IV partially edentulous patient with a custom attachment-retained prosthesis

Pavithra Kumar Shetty, Bharath Y Shetty<sup>1</sup>, Mayur Hegde<sup>1</sup>, Bharath M Prabhu<sup>1</sup>

Department of Prosthodontics, KLE Viswanath Katti Institute of Dental Sciences, Belgaum, <sup>1</sup>Department of Prosthodontics, A. J. Institute of Dental Sciences, Mangalore, Karnataka, India

### Abstract

The rehabilitation of a patient in the Kennedy class IV situation demands biomechanical balance and aesthetic improvement. The long-span condition complicates the problem because of the unavailability of sufficient number of abutments to support the prosthesis. Conventional removable prosthesis and fixed partial denture are not advised for the same reason. This report describes a novel technique for the fabrication of a custom attachment to retain prosthesis. An acrylic resin removable partial denture (RPD) is retained by a custom attachment. The matrix part of the custom attachment is fabricated using molar bands, prefabricated circumferential clasp, and straight die pins. The matrix part of the attachment is constituted by the plastic sleeves of the straight die pins, which are embedded inside the tissue-fitting surface of the prosthesis. This article describes an inexpensive custom attachment for rehabilitating the long-span Kennedy class IV situation. The entire technique is reversible, inexpensive, and demands less skill compared to semi-precision and precision attachments.

**Key Words:** Custom attachment, Kennedy class IV, long-span, rehabilitation

### Address for correspondence:

Dr. Pavithra Kumar Shetty, Department of Prosthodontics, KLE Viswanath Katti Institute of Dental Sciences, Nehru Nagar, Belgaum - 590 010, Karnataka, India. E-mail: [docpavithrakshetty@gmail.com](mailto:docpavithrakshetty@gmail.com)

**Received:** 16<sup>th</sup> January, 2015, **Accepted:** 18<sup>th</sup> February, 2015

## INTRODUCTION

Rehabilitation options for the partially edentulous patient with a single tooth or multiple missing teeth include interim acrylic resin removable partial denture (RPD), conventional cast partial denture, partial denture with attachment, fixed partial denture, or implant-retained prosthesis. Clinical decision-making is critical in deciding the most suitable treatment option for a particular patient.<sup>[1]</sup>

RPDs are considered a widely acceptable means of replacing missing natural teeth for restoring aesthetics and function in partially edentulous patients.<sup>[2]</sup> Among the two major types of RPDs, the acrylic resin partial dentures are more commonly used than the cast partial dentures. It is true for all the Kennedy classes and class IV is not an exception. The widespread use of acrylic partial denture is attributed to advantages, such as its low cost and relatively ease of fabrication and modification.<sup>[3]</sup> Along with its advantages, it has many shortcomings, such as the undue load placed on abutment teeth, plaque accumulation that can cause periodontal damage, enamel wear, and damage to soft tissue due to the clasps.<sup>[3-8]</sup>

Even though the incidence of Kennedy class IV edentulism is reduced mainly because of seat belt legislation and an increasing concern for oral protection in contact sports, it is still frequently encountered. Kennedy class IV edentulous

Access this article online	
Quick Response Code:	Website: <a href="http://www.j-ips.org">www.j-ips.org</a>
	DOI: 10.4103/0972-4052.155045

space may be short-span, where only incisors are missing or long-span, where anterior teeth and some premolars are missing. Later, even if the abutments are periodontally sound, a fixed prosthesis would result in an unacceptable cantilever effect.<sup>[9]</sup>

Schwartz *et al.* reported that RPD is an advised treatment option for the rehabilitation of Kennedy class IV situations where there are a) long-span edentulous space that requires tooth- and tissue-supported designs, b) markedly resorbed ridge, where it is necessary to support the middle and the lower third of the face by denture flange, c) exposure of the gingival tissues during lip function, d) cleft palate and other maxillofacial defects, and e) young patients with large pulp horns for whom preparing the teeth is contraindicated for fixed prosthesis.<sup>[10]</sup>

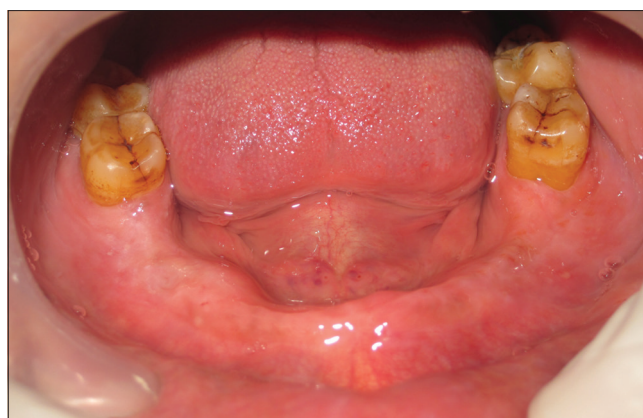For the rehabilitation of a Kennedy class IV partially edentulous arch, precision and semi-precision attachments have been widely used with the RPDs to mainly improve the retention and to overcome the detrimental effects of the clasps on the abutments.<sup>[2]</sup> These attachments are expensive, demand more laboratory and clinical skills, and need irreversible teeth reduction. In long-span Kennedy class IV situations where only one or two distal molars remain on both the sides, precision and semi-precision attachments have limited application, mainly because of the detrimental effect of the cantilever on the abutments through attachments.

The purpose of this report is to present the technique for the fabrication of cost-effective custom attachment with stress-breaking effect for the rehabilitation of long-span Kennedy class IV patients.

## CASE REPORT

A 48-year-old male patient reported to the Department of Prosthodontics, KLE Viswanath Katti Institute of Dental Sciences, Belgaum, Karnataka with a complaint of unaesthetic appearance and difficulty in chewing and swallowing food because of the multiple missing lower front teeth due to decay. On examination of the maxillary arch, all the teeth were intact. In the mandibular arch, there was a long-span Kennedy class IV partially edentulous space with only the second and the third molars remaining on both the sides. The edentulous part of the mandibular arch was well-formed and the remaining molars were clinically sound [Figure 1]. A custom attachment-retained removable prosthesis was planned for the rehabilitation of the long-span Kennedy class IV partially edentulous space.

The diagnostic impressions were made using irreversible hydrocolloid impression material (tropicalgin; Zhermack,



**Figure 1:** Intraoral view showing the mandibular long-span Kennedy class IV partially edentulous arch

Italy). The casts were prepared using type III dental stone (kalstone; Kalabhai Karson Pvt. Ltd., Mumbai, Maharashtra, India). The tentative jaw relation was recorded to assess the interarch space, which was found to be satisfactory.

The teeth separators (dental orthodontic separators; Zhejiang Protect Medical Equipment Co., Ltd, Zhejiang, China) were placed between the mandibular second and third molars on both the sides for 1 week. After a week, the teeth were separated by a distance of at least 1 mm. The teeth separators were removed. The final impression was made with medium body polyvinyl siloxane impression material (Aquasil Ultra Monophase; DENTSPLY, Germany). The cast was poured with die stone (ultrarock; Kalabhai Karson Pvt. Ltd., Mumbai, Maharashtra, India).

On the cast, the molar bands (dental material orthodontic molar band; Hangzhou Nuoke Medical Instrument Co. Ltd, Zhejiang, China) were adapted around the remaining molars, then spot welding was done to join the bands of the two molars on both the sides. Prefabricated circumferential clasps (performed wire clasps; Dentaaurum, Germany) were selected for the mesial molars on both the sides. The occlusal rest was trimmed and adapted around the mesial molar band, followed by soldering on the buccal and lingual sides to attach it to the molar band assembly [Figure 2]. Two straight die pins and their sleeves (Crosspin; Nordin, Switzerland) were cut to a length of 8 mm and 6 mm, respectively. The butt ends of the die pins were soldered on to the horizontal extensions of the prefabricated clasp, the first die pin at a distance of around 8 mm from the mesial end of the proximal molar band and the second one around 8 mm from the first. This constitutes the patrix part of the attachment [Figure 3]. The entire assembly was tried in the patient's mouth to assess its fit and the availability of the interarch space; it was then placed back onto the cast.

The components extending onto the ridge on the cast were blocked out with putty (Aquasil; DENTSPLY, Germany), then the temporary denture base and the occlusal rim were fabricated. The jaw relation was recorded followed by articulation and teeth arrangement. Try-in was done followed by acrylization with heat-polymerized acrylic resin (Trevalon; DENTSPLY India Pvt Ltd., Gurgaon, Haryana, India). Laboratory remounting, and finishing and polishing of the prosthesis were done. Cementation of the molar bands with the patrix part of the attachment was done using type I glass ionomer cement (GC Luting and Lining Cement; GC Corporation, Tokyo, Japan) on both the sides. The tissue-fitting surface of the acrylic resin prosthesis in the area of the patrix part of the attachments was trimmed till the denture was stably seated with the predetermined occlusion. The space created on the tissue-fitting surface of the denture was widened to accommodate the plastic sleeves (matrix) of the die pin. The matrix was inserted onto the patrix [Figure 4]. The matrix was picked up in the prosthesis by putting the

autopolymerizing acrylic resin in the space created on the tissue-fitting surface of the prosthesis [Figure 5].

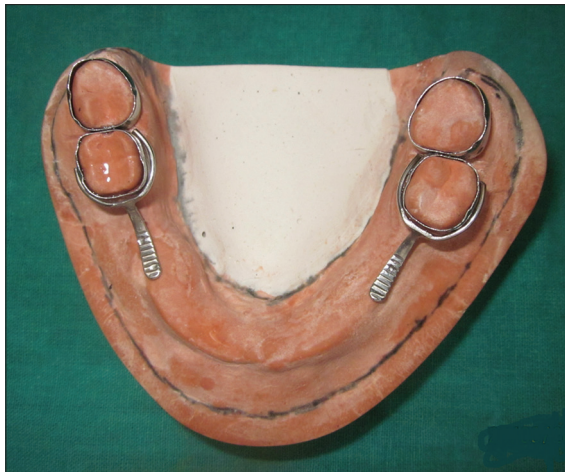The prosthesis was removed. The excess was trimmed off from the tissue-fitting surface of the prosthesis. The prosthesis was delivered [Figure 6] with oral hygiene instructions and the patient was intimated about the importance of periodic checkups.

## DISCUSSION

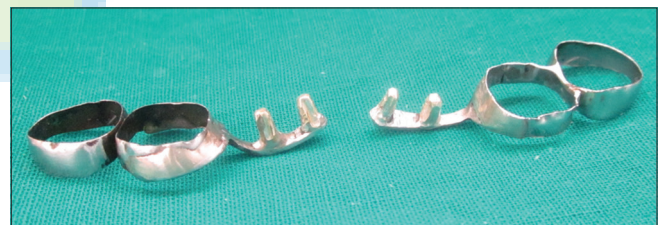This custom attachment-retained RPD can be used as a transitional prosthesis when the remaining teeth are expected to be lost in the near future or when more definitive treatment options like implant-supported prosthesis are going to be adopted shortly.

An RPD rehabilitating Kennedy class IV edentulous span can be considered successful if a) it does not cause gingival irritation and subsequent periodontal damage, b) the clasp arms are inconspicuous, and c) it is retentive.<sup>[9]</sup> All three criteria are satisfied with this technique.

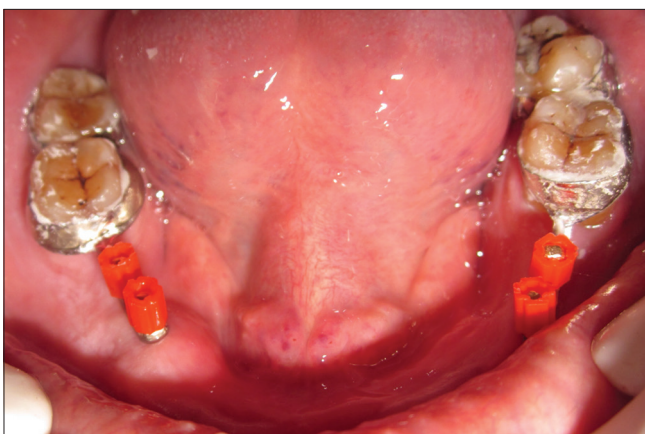
Occlusal load exerted by the long-span RPD is partly dissipated because of the flexible components of the attachment, such as molar bands, horizontal extension, and plastic sleeves. In other words, this custom attachment acts as a stress breaker. This technique is highly cost-effective as it uses inexpensive materials like straight die pins, molar bands, and prefabricated



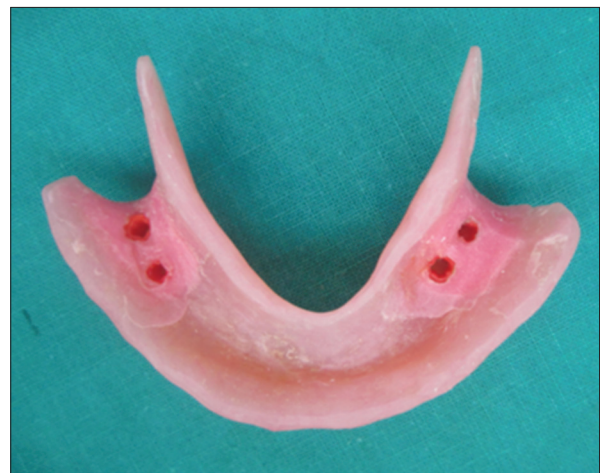**Figure 2:** Molar bands adapted on the remaining molars and circumferential clasps adapted around the mesial molar bands



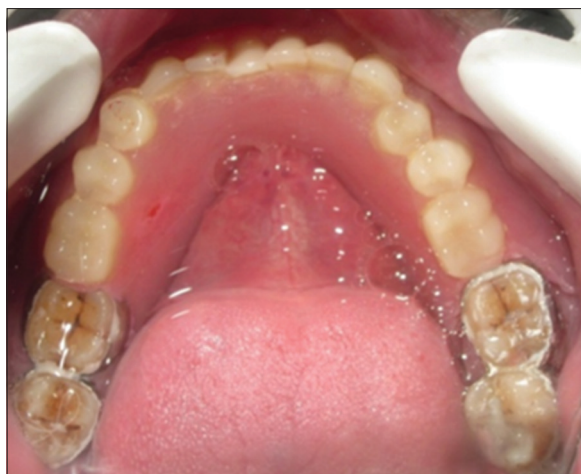**Figure 3:** Splinted molar bands with the patrix part of the attachment



**Figure 4:** Intraoral picture showing the patrix part of the attachment with plastic sleeves in place



**Figure 5:** Tissue-fitting surface of the prosthesis showing embedded plastic sleeves



**Figure 6:** Intraoral view showing the prosthesis retained by custom attachment

clasps. No irreversible damage is caused to the teeth. Teeth separators were used rather than grinding the teeth to create space for inserting the molar bands.

This technique has some disadvantages, such as difficulties in maintenance of hygiene. There are chances of dislodgement of molar bands if they are not adapted properly or because of the unavailability of undercuts on the abutments.

## CONCLUSION

This article describes an inexpensive custom attachment for rehabilitating a long-span Kennedy class IV situation. The entire technique is reversible, inexpensive, and demands less

skill from the dentist and the laboratory technician, compared to semi-precision and precision attachments.

## REFERENCES

1. Owall B, Kayser AF, Carlsson GE. *Prosthodontics-Principles and Management Strategies*. 2<sup>nd</sup> ed.2004.
2. Wöstmann B, Budtz-Jørgensen E, Jepson N, Mushimoto E, Palmqvist S, Sofou A, *et al.* Indications for removable partial dentures: A literature review. *Int J Prosthodont* 2005;18:139-45.
3. Walmsley AD. Acrylic partial dentures. *Dent Update* 2003;30:424-9.
4. Bergman B. Periodontal reactions related to removable partial dentures: A literature review. *J Prosthet Dent* 1987;58:454-8.
5. Drake CW, Beck JD. The oral status of elderly removable partial denture wearers. *J Oral Rehabil* 1993;20:53-60.
6. Schwalm CA, Smith DE, Erickson JD. A clinical study of patients 1 to 2 years after placement of removable partial dentures. *J Prosthet Dent* 1977;38:380-91.
7. Gomes BC, Renner RP, Bauer PN. Periodontal considerations in removable partial dentures. *J Am Dent Assoc* 1980;101:496-8.
8. Yusof Z, Isa Z. Periodontal status of teeth in contact with denture in removable partial denture wearers. *J Oral Rehabil* 1994;21:77-86.
9. Zarb GA, MacKay HF. Cosmetics and removable partial denture—the class IV partially edentulous patient. *J Prosthet Dent* 1981;46:360-8.
10. Schwartz NL, Whitsett LD, Berry TG, Stewart JL. Unserviceable crowns and fixed partial dentures: Life-span and causes for loss of serviceability. *J Am Dent Assoc* 1970;81:1395-401.

**How to cite this article:** Shetty PK, Shetty BY, Hegde M, Prabhu BM. Rehabilitation of long-span Kennedy class IV partially edentulous patient with a custom attachment-retained prosthesis. *J Indian Prosthodont Soc* 2016;16:83-6.

**Source of Support:** Nil, **Conflict of Interest:** We, Dr. Pavithra Kumar Shetty, Dr. Bharath Y Shetty, Dr. Mayur Hegde, and Dr. Bharath M Prabhu, the authors of this scientific report, hereby declare that there is no conflict of interest with other people or organizations that could inappropriately influence or bias the work.