

Case Report

Rehabilitation of post-traumatic total nasal defect using silicone and acrylic resin

Vikas Aggarwal, Kusum Datta, Sukhjit Kaur

Department of Prosthodontics, Crown and Bridge, Punjab Government Dental College and Hospital, Amritsar, Punjab, India

Abstract

Facial defects resulting from neoplasms, congenital abnormalities or trauma can affect the patient esthetically, psychologically, and even financially. Surgical reconstruction of large facial defects is sometimes not possible and frequently demands prosthetic rehabilitation. For success of such prosthesis, adequate replication of natural anatomy, color matching and blending with tissue interface are important criteria. Variety of materials and retention methods are advocated to achieve a functionally and esthetically acceptable restoration. Silicones are the most commonly used materials because of flexibility, lifelike appearance and ability to be used in combination with acrylic resin which is hard, provides body and helps in achieving retention to the prosthesis by engaging mechanical undercuts. Furthermore, the acrylic portion can be relined easily, thus helping comfortable wear and removal of the prosthesis by patient without traumatizing nasal mucosa. This case report describes time saving and cost effective prosthetic rehabilitation of a patient with total nasal defect using custom sculpted nasal prosthesis made up of silicone elastomer and acrylic resin, which is retained by engaging mechanical undercut and use of biocompatible silicone adhesive.

Key Words: Esthetics, defect, prosthesis, rehabilitation, relining, retention

Address for correspondence:

Dr. Vikas Aggarwal, Department of Prosthodontics, Crown and Bridge, Punjab Government Dental College and Hospital, Amritsar - 143 001, Punjab, India.
E-mail: vikasaggarwal1984@gmail.com

Received: 12th February, 2015, **Accepted:** 18th July, 2015

INTRODUCTION

A face represents the identity and personality of an individual. Any disfigurement to facial esthetics can lead to ones "inferiority complex."^[1] Facial defect, be it congenital, traumatic or postsurgical, affects the patient esthetically, psychologically, and even financially.^[2,3] Treatment of such defects requires a multidisciplinary approach involving a maxillofacial plastic surgeon, a maxillofacial prosthodontist and a psychologist. Prosthodontic results are often limited by the physical and mechanical properties of the materials used in the fabrication

of such prosthesis.^[1] A variety of materials commonly used are: Acrylic resins, copolymers, vinyl polymers, polyurethane elastomers, and silicone elastomers. Silicones are most commonly used materials and can be used in combination with acrylic.^[4,5]

Retention of the facial prosthesis can be achieved by biocompatible adhesives, engaging a mechanical undercut, osseointegrated implants or attaching the prosthesis to patient's eyeglasses.^[6-9]

Access this article online	
Quick Response Code: 	Website: www.j-ips.org
	DOI: 10.4103/0972-4052.164902

This is an open access article distributed under the terms of the Creative Commons Attribution-NonCommercial-ShareAlike 3.0 License, which allows others to remix, tweak, and build upon the work non-commercially, as long as the author is credited and the new creations are licensed under the identical terms.

For reprints contact: reprints@medknow.com

How to cite this article: Aggarwal V, Datta K, Kaur S. Rehabilitation of post-traumatic total nasal defect using silicone and acrylic resin. J Indian Prosthodont Soc 2016;16:87-90.

This case report describes prosthetic rehabilitation of total nasal defect using custom sculpted nasal prosthesis made up of silicone elastomer and acrylic resin, which is retained by engaging mechanical undercut and use of biocompatible silicone adhesive.

CASE REPORT

Patient history

A 60-year-old male patient reported to the Department of Prosthodontics and Crown and Bridge, Punjab Government Dental College and Hospital, Amritsar with a history of animal attack 2 years ago. The accident resulted in severe facial disfigurement with the loss of nose, left eye and anterior maxillary teeth. Since then the patient had been operated thrice for reconstruction of the defect, with the last procedure performed 7 months earlier. Due to old age and financial constraints, the patient was unable to undergo further reconstructive procedure. The traumatic loss of nose and anterior maxillary teeth had a huge psychological impact on the patient. The patient had low self-esteem as he had to keep his face covered with a face-mask always.

Clinical examination

Extra-oral examination of the patient revealed healthy boundaries of the defect with entire nasal septum and alae missing and only minimal nasal bridge was present. There was considerable asymmetry of the face with depressed right malar region [Figure 1].

Intra-oral examination revealed missing anterior maxillary ridge from canine to canine along with obliteration of labial sulcus, but there was no communication with the extra-oral defect. The patient was explained about the treatment procedure in detail.

Treatment plan

Within the limitations of the patient's chief complaint, cost and time, it was decided to rehabilitate the patient with an extra-oral nasal prosthesis and intra-oral flexible removable partial denture. The patient was also advised to get an orbital prosthesis later after consulting an ophthalmologist.

Clinical procedure

Before the impression, petroleum jelly was applied over the eye-lashes and eye brows. Deep undesirable undercuts were blocked with the help of moist gauge. Facial moulage was prepared using irreversible hydrocolloid impression material (Tropicalgin, Zhermack, Italy) [Figure 2].

Airway patency was maintained through a plastic tube held passively by the patient.^[10] Another alginate impression was made of the nose of patient's son, which acted as a scaffold for fabrication of wax pattern. This wax pattern was further refined using patient's old photograph and its margins were

extended over the depressed area of the right zygoma to create harmony between two sides of the face [Figure 3].

A separate scaffold was fabricated directly over the facial moulage with autopolymerizing resin by selectively utilizing

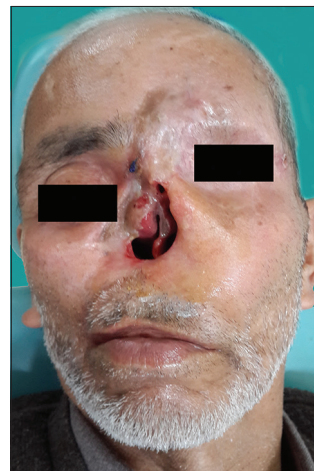

Figure 1: Pre-treatment photograph showing nasal defect

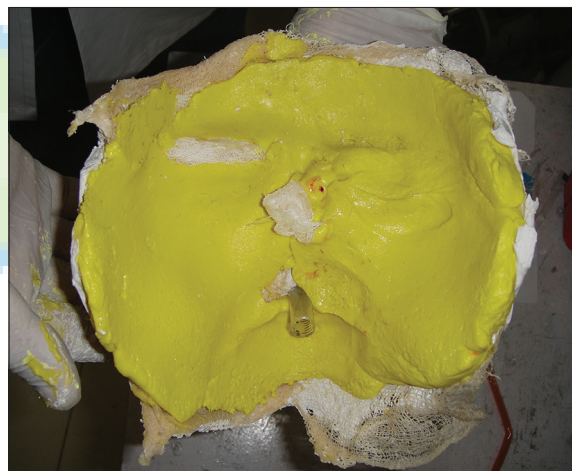


Figure 2: Facial moulage



Figure 3: Wax pattern fabricated over acrylic scaffold

undercuts for retention. The scaffold was cured under 20 psi pressure pot for 10 min. Two separate holes were made for airway patency divided by an acrylic nasal septum.^[11] This perforated acrylic scaffold provided body, support and mechanical retention to silicone. The acrylic scaffold was finished and polished and the wax pattern was seated over it, and adapted to facial cast. Wax pattern along with scaffold was tried on the patient. In the meantime, maxillary and mandibular arch impressions were made using alginate and poured with gypsum type III (Gypstone, Prevest Denpro, Jammu and Kashmir, India). Jaw relations and try-in of the trial dentures were done for an intra-oral prosthesis and flexible removable partial dentures were inserted.

After final try-in, flasking and dewaxing of extra-oral prosthesis was carried out [Figure 4] and separating media was applied. Room temperature vulcanizing silicone (RTV silicone, M.P Sai Enterprises, Mumbai, Maharashtra, India) was used along with compatible stains provided by manufacturer to pack the mold after chair side shade matching [Figure 5]. Flasks were left at room temperature for 48 hr for curing. Prosthesis was removed from flasks and edges were finished with sharp surgical scissors. Silicone gloss was applied over the external surface to give more lifelike appearance [Figure 5].

Nasal prosthesis was tried on patient and relining of tissue surface of acrylic scaffold was done with help of acrylic based soft reliner (GC-softliner GC Dental, India) [Figure 6] A medical grade silicone skin adhesive (Cosmesil™ Technovent

Ltd, South Wales, UK) was used for additional retention. The patient was advised to get an orbital prosthesis to improve his facial esthetics, and to wear spectacle to conceal the margins of prosthesis [Figure 7]. Improved esthetics and appearance of the patient coupled with speech and self-esteem were observed after insertion of the nasal prosthesis and removable partial denture.

DISCUSSION

Restoration of the facial defect is usually done by plastic and reconstructive surgeries. However, in certain cases presenting extensive loss of anatomic tissues, as in this case, prosthetic rehabilitation is definitely an alternative.^[2] Two most commonly used materials for maxillofacial prosthesis are acrylic and silicones. Acrylic resin prostheses are cost effective, but they are inflexible and have esthetic limitations. Silicone is most commonly used for restoring facial defects. It is biocompatible, durable, lightweight, flexible, has the lifelike appearance, adequate working time and can be stained both intrinsically and extrinsically. Yet silicones have their own disadvantages

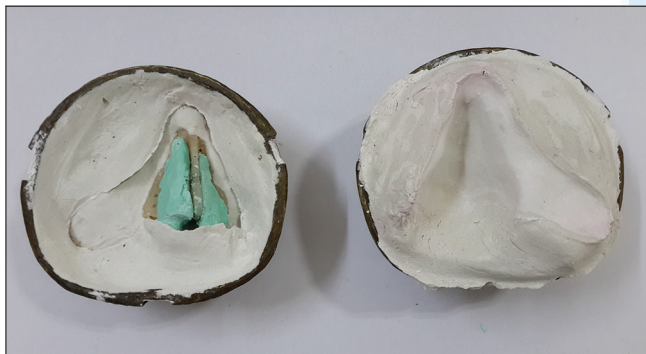

Figure 4: Flasking and dewaxing of wax pattern along with acrylic scaffold

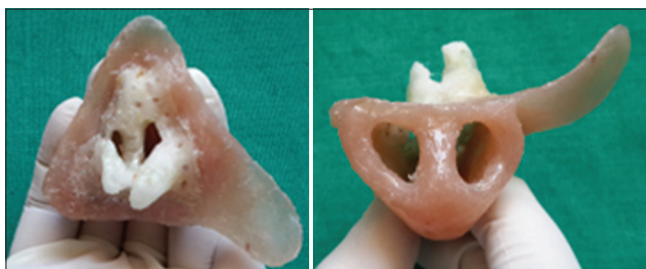


Figure 6: Acrylic portion relined with acrylic based tissue conditioner

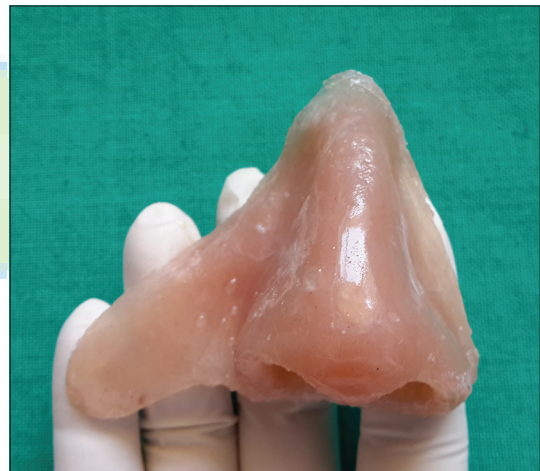

Figure 5: Finished nasal prosthesis

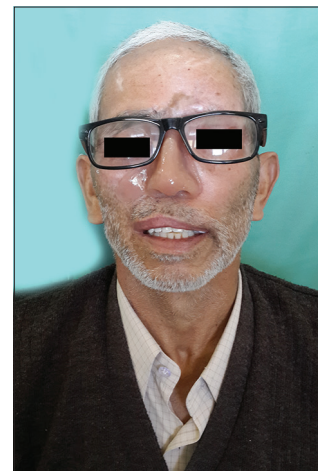

Figure 7: Post-treatment photograph with nasal prosthesis

such as they undergo wear and degradation, start discoloring within 6–14 months and harden with time. They can tear easily if not handled carefully and are difficult to maintain clean.^[12]

Retention of the facial prosthesis is very crucial for psychological acceptance by the patient. The nasal prosthesis can be retained by means of a spectacle, mechanical undercut, bioadhesives, and implants or double sided tape. In this case, since the prosthesis was large and involved a lateral projection covering malar region, both mechanical undercuts and adhesives were used for obtaining retention. Acrylic scaffold projected into the desirable undercut of the nasal cavity to aid in mechanical retention.

The nasal mucosa can be easily traumatized by the mechanically retained prosthesis due to repeated movements. Relining the tissue surface of the acrylic scaffold with acrylic based soft reliner helped in comfortable wearing and removal of the prosthesis by patient without traumatizing nasal mucosa. For additional retention, biocompatible moisture-resistant skin adhesive was used to provide sufficient retention for longer duration without dissolving in sweat.

Considering the size of the nasal defect, fabrication of implant retained nasal prosthesis would have been a better choice, but treatment in this case had its limitations. The use of RTV silicone with bioadhesive provided economic rehabilitation to the patient, improving his self-confidence, quality of life and helped him to reintegrate back into society. The procedure also involved less clinical chair time, improving the compliance of the patient too.

CONCLUSION

A combination of acrylic and silicone was used to restore a large nasal defect, within all the constraints. The soft reliner provided a less traumatic intra-nasal surface to the prosthesis. A time and cost effective, sufficiently retentive nasal prosthesis, along with oral rehabilitation with flexible removable partial denture was done. Both extra-oral and intra-oral prosthesis were esthetically and functionally acceptable to the patient.

Declaration of patient consent

The authors certify that they have obtained all appropriate patient consent forms. In the form the patient(s) has/have given his/her/their consent for his/her/their images and other clinical information to be reported in the journal. The patients understand that their names and initials will not be published and due efforts will be made to conceal their identity, but anonymity cannot be guaranteed.

Financial support and sponsorship

Nil.

Conflicts of interest

There are no conflicts of interest.

REFERENCES

1. Fonseca EP. The importance of form, characterization, and retention in facial prosthesis. *J Prosthet Dent* 1966;16:338-43.
2. Miglani DC, Drane JB. Maxillofacial prosthesis and its role as a healing art. *J Prosthet Dent* 1959;9:159-68.
3. Ahmed B, Butt AM, Hussain M, Amin M, Yazdanie N. Rehabilitation of nose using silicone based maxillofacial prosthesis. *J Coll Physicians Surg Pak* 2010;20:65-7.
4. Marion LR, Rothenberger SL, Minsley GE, Judson C. Hickey scientific writing award winner. A method of fabrication of a facial prosthesis that improves retention and durability: A clinical report. *J Prosthet Dent* 1997;77:457-60.
5. Mortellaro C, Garagiola U, Lucchina AG, Grivetto F, Milone G, Pappalardo S, *et al.* The use of silicon elastomer in maxillofacial rehabilitation as a substitute for or in conjunction with resins. *J Craniofac Surg* 2006;17:152-62.
6. Gurbuz A, Kalkan M, Ozturk AN, Eskitascioglu G. Nasal prosthesis rehabilitation: A case report. *Quintessence Int* 2004;35:655-6.
7. Seçilims A, Oztürk AN. Nasal prosthesis rehabilitation after partial rhinectomy: A clinical report. *Eur J Dent* 2007;1:115-8.
8. Guttal SS, Vohra P, Pillai LK, Nadiger RK. Interim prosthetic rehabilitation of a patient following partial rhinectomy: A clinical report. *Eur J Dent* 2010;4:482-6.
9. Jain S, Maru K, Shukla J, Vyas A, Pillai R, Jain P. Nasal prosthesis rehabilitation: A case report. *J Indian Prosthodont Soc* 2011;11:265-9.
10. Andres CJ, Haugh SP. Facial prosthesis fabrication: Technical aspects. In: Taylor TD, editor. *Clinical Maxillofacial Prosthetics*. Illinois: Quintessence Publishing Co. Inc.; 2000. p. 233-44.
11. Brown KE. Fabrication of a nose prosthesis. *J Prosthet Dent* 1971;26:543-54.
12. Lemon JC, Kiat-amnuay S, Gettleman L, Martin JW, Chambers MS. Facial prosthetic rehabilitation: Preprosthetic surgical techniques and biomaterials. *Curr Opin Otolaryngol Head Neck Surg* 2005;13:255-62.