

Multidisciplinary approach for improving esthetics in cleft palate and alveolus patient: A clinical report

S. Doddamani, R. A. Patil, S. Nerli

Department of Prosthodontics, K.L.E.S's Institute of Dental Sciences, Belgaum, Karnataka, Bangalore, India

For correspondence

Dr. S. Doddamani, Department of Prosthodontics, K.L.E.S's Institute of Dental Sciences, Belgaum, Karnataka, Bangalore, India.
E-mail: santoshdoddamani@rediffmail.com

This clinical report describes an interdisciplinary (oral surgery, orthodontics, and prosthodontics) approach for the coordinated treatment of a patient diagnosed with operated cleft palate and lip. On intra oral examination - gingival cleft, missing maxillary left central and lateral incisors and maxillary right premolars and orthodontic malocclusion were present. The patients' specific esthetic expectations for the anterior maxilla were successfully met through phased treatment, which included orthodontic tooth movement, distraction osteogenesis, surgical closure of the cleft, full upper arch rehabilitation with porcelain fused to metal and pink porcelain in the cleft region. Such coordinated interdisciplinary evaluation and treatment are necessary for improved esthetics, functional results in maxillary anterior areas for esthetically compromised patients in several aspects.

Key words: Interdisciplinary approach, upper arch rehabilitation

Cleft lip and palate represents the second most frequently occurring congenital deformity (after club foot deformity), it affects 1:750 births.

Ideally, aim of medical profession is to provide a state of total health to the patient, which is not merely a treatment of the disease but a physical and psychological well being of the patient.

But, in this era of superspecialization with the boon of advanced knowledge and modern technology, there is a ban of developing a tunnel vision to our fields.

The increasing demand for esthetic restorations can be met with any of ceramic restoration systems currently available. However, the esthetic value of a cosmetic restoration may be compromised by other factors contributing to the composition of a pleasant smile, such as amount of gingival display, gingival architecture, clinical crown dimensions and tooth position.^[1]

The major prosthetic treatments to close the soft tissue defect were removable flange prostheses, Andrew's bridge and surgical bone augmentation, but in this case a fixed prostheses with pink porcelain is used to mask the soft tissue defect, which improved speech and esthetics.

It is a well-established fact that multidisciplinary approach is definitely the most ideal way of treating

cleft lip and palate patients and prosthodontist is an important and integral part of this team.

CLINICAL PROCEDURE

A 26-year-old patient by name Devikumar came to KLES's Institute of Dental Sciences, Belgaum, with set of problems like nasal regurgitation of fluids, change in phonetics, difficulty in mastication and poor esthetics; his medical history revealed no contraindication for dental treatment.

Extra-oral examination indicated slight asymmetry in upper lip, straight profile, exposure of gingival cleft while smiling, intra-oral examination revealed migrated central incisor (11) and canine (23) into the edentulous site, collapsed bite, crossbite and midline was not coinciding with mid-sagittal plane [Figure 1].

Preoperative radiograph

Revealed retained deciduous maxillary right first molar and maxillary left lateral incisor before orthodontic treatment these teeth were advised for extraction [Figure 2].

Relevant dental history revealed previous surgical treatment for closure of cleft palate at the age of 1 and 12 years.

Because of the range of conditions that had to be addressed for optimal esthetic results, an interdisciplinary approach was followed.

Orthodontic and surgical treatment

Proposed treatment plan was to move the canine (23) and central incisor (11) distally, correction of cross bite/palatal expansion by distraction osteogenes which included labial corticotomy and quad helix fixed orthodontic treatment [Figure 3].

After orthodontic and surgical treatments, the cleft was almost closed and cross bite along with migrated teeth were corrected.

Then diagnostic cast was prepared with alginate impressions and mounted to semiadjustable articulator with face bow record. Protrusive record was used to set the condylar guidance.

Prosthetic treatment

The tooth in relation to 11, 12, 13, 23 and 24 were prepared with shoulder finish line for ceramic restoration [Figure 4] 15, 16 and 18 were prepared with chamfer finish line for full metal restoration.

The wax pattern, castings, finishing, metal try in, shade selection and ceramic facing with pink porcelain were done.

This pink porcelain improves the speech and esthetics, at last the patient was very happy with this

multidisciplinary approach. Meticulous oral hygiene instructions were given for maintenance [Figure 5-6]. Totally the treatment took about 2.5 years to complete all the procedures.

DISCUSSION

Cleft lips are repaired at about 10 weeks of age at most of the institutions. Lip adhesions can be performed at 2 weeks of age. Cleft palate is treated at 1 year of age. For this patient surgical closure of the cleft at first year and 10th year was done but still a very small oro-antral fistula measuring about 1.5 mm in diameter was remaining, again bone grafting was done to close this defect, but this surgery was failed. Hence oral surgeon decided to treat it with an innovative surgery that is distraction osteogenesis.

Distraction Osteogenesis is an innovative treatment option in craniofacial surgery. It was first used in orthopedic medicine in the early 1900s, but the current concepts evolved from the ideas of Dr. Gavriel Ilizarov, who practiced medicine in Kurgan, Siberia. Dr. Ilizarov, who had great understanding of the biophysiology of bone, developed techniques to move bone fragments in controlled vectors using a system of wires and fixed rings joined together with threaded rods and hinges.^[2] It has also been established that in addition to bone formation, there are histogenetic

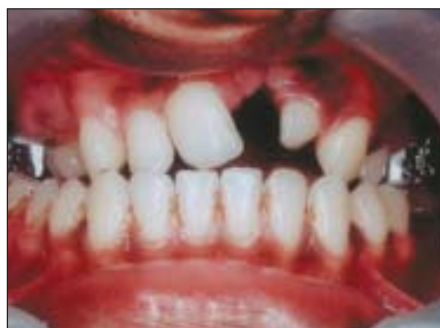

Figure 1: Before treatment. Cleft alveolus and cross bite can be seen

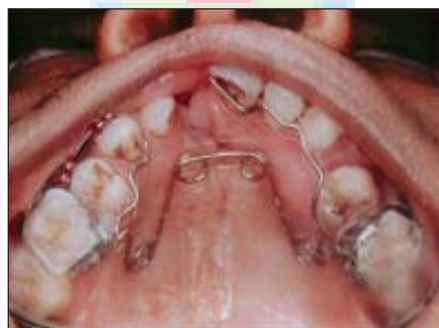

Figure 3: Photograph showing orthodontic treatment with fixed appliance, palatal quad helix fixed appliance

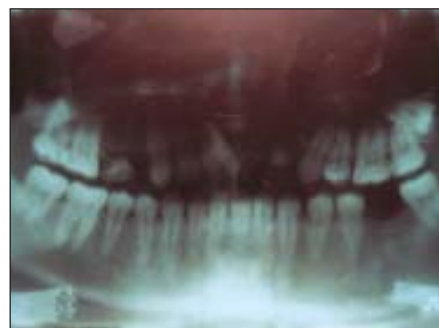


Figure 2: Preoperative OPG

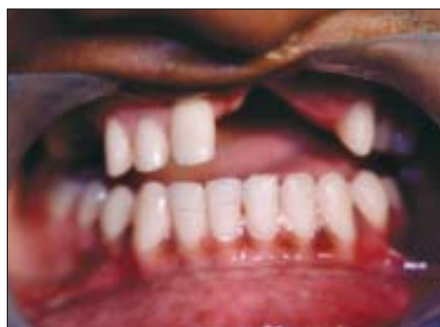

Figure 4: After crown preparations

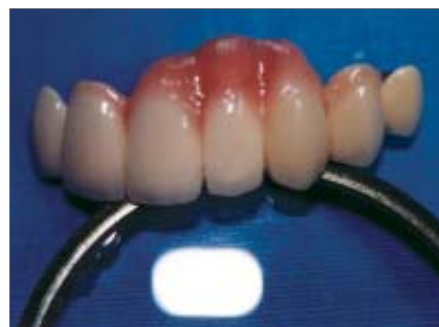

Figure 5: Finished fixed prosthesis with pink porcelain

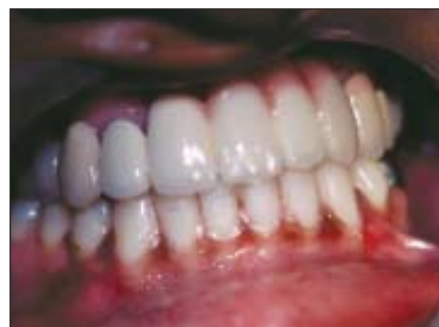

Figure 6: After cementation

effects on the adjacent soft tissues that respond by proliferating parallel to bony distraction, thus offering a distinct advantage for several anomalies with concurrent soft-tissue hypoplasia.^[3,4] As a result, distraction osteogenesis can be successfully applied to congenital deficiencies, in which soft-tissue defects coexist with bony deficiencies.^[5-7] This technique allowed alveolar ridge augmentation in atrophic mandible cases.^[8]

Advantages of distraction osteogenesis

- Little relapse.
- Bigger movements possible.
- Ability to mold for regeneration.
- Outpatient surgery.
- No need to extract teeth.
- Generation of soft tissue.
- Less likelihood of nerve injury.
- Less likelihood of idiopathic condylar resorption.

Disadvantages of distraction osteogenesis

- Technique sensitive surgery.
- Equipment sensitive surgery.
- Possible need of second surgery to remove distraction devices.
- Patient compliance.

When using unidirectional intraoral distraction devices, it is desirable to be able to determine the final position of the bone fragment after the distraction procedure. However, additional constraining forces from adjacent tissues render the prediction of the distraction direction difficult.

Watzinger et al.^[9] found that the distraction procedure led to a satisfactory result in cleft palate patients. Computer-aided surgery is helpful in assessing the vector of distraction intraoperatively, making the result of the distraction procedure more predictable and allowing instant correction by adequate reapplication of the device.

Cohen et al.^[10] used a miniature system of distraction devices for maxillary-midface advancement in two children with cleft lip and palate, class III malocclusion, and associated mid-facial hypoplasia. The devices are made with commercially available palatal expansion screws linked to rigid fixation plates. About 11 mm of distraction was carried out in the vertical and sagittal direction. Without any complications, maxillary-mid-facial distraction osteogenesis to correct severe maxillary-mid-facial hypoplasia in children with clefts and other craniofacial disorders permits early intervention with potentially less invasive techniques than are currently available.

Various devices used for distraction

1. Quad helix appliance.
2. Haas palatal expander.

3. Mandibular ramus distractor.
4. Mandibular body distractor.
5. RFD craniofacial distractor.
6. Mandibular bone transport (V-distractor).
7. Alveolar distractor.

First, the patient with a surgically repaired cleft lip will likely to have a very high lip line, leading to the residual soft tissue defect in the cleft visible and less amenable to conventional FPD.

Treatment options are as follows.^[14]

- RPD with flange to mask the defect.
- Andrew's bridge
- Ridge augmentation with bone graft.

In this case, we planned a fixed prosthesis with elongated pontic design and pink porcelain, which improved the speech and esthetics.

Following factors should be considered while fabricating this kind of prosthesis to close the soft tissue defect:

1. The design of the pontic region and porcelain contour should contribute to hygiene complications.
2. The location of the prosthetic margin, the design of metal substructure, contour, and emergence profile are critical variables in designing esthetics, gingival health and maintenance of oral hygiene.
3. The combination of porcelain and metal should be in such a way that it should maintain the gingival health.

Exposed metal margins, bulky prosthetic design, obstruction of embrasure space will compromise esthetics and influence the adjacent soft tissue response. The interpriaxial tissue location, ridge contour and emergence profile of the soft tissue must be respected and factored in the final porcelain contour.

CONCLUSION

Prosthodontist plays a very important role in complete rehabilitation of cleft lip and palate patients. For successful rehabilitation of such patients, a team approach of concerned specialities with phase-wise, unanimous and systematic treatment plan is essential. Aim of the team of consultants should be rehabilitation of the patient 'as a whole' and not just success of individual speciality. Team approach will help to extend their knowledge and services to the medical field for betterment of the cleft lip and palate patients to enter the mainstream of the society.

REFERENCES

1. Claman L, Alfaro MA, Mercado A. "An interdisciplinary approach for improved esthetic results in the anterior maxilla" J Prosthet Dent 2003;89:1-5.
2. Ilizarov GA. The principles of the Ilizarov method.

- Bull Hosp Joint Dis Orthop Inst 1988;48:1-11.
3. Toth BA, Kim JW, Chin M. Distraction osteogenesis and its application to the midface and bony orbit in craniosynostosis syndromes. *J Craniofac Surg* 1998;9:100-13.
 4. Meyer U, Wiesmann HP, Kruse-Losler B, Handschel J, Stratmann U, Joos J. Strain-related bone remodeling in distraction osteogenesis of the mandible. *Plast Reconstr Surg* 1999;103:800-7.
 5. Chin M, Toth BA. Distraction osteogenesis in maxillofacial surgery using internal devices: Review of five cases. *J Oral Maxillofac Surg* 1996;54:45-53.
 6. Chin M, Toth BA. Le Fort III advancement with gradual distraction using internal devices. *Plast Reconstr Surg* 1997;100:819-30.
 7. Polley JW, Figueroa AA. Management of severe maxillary deficiency in childhood and adolescence through distraction osteogenesis with an external, adjustable, rigid distraction device. *J Craniofac Surg* 1997;8:181-5.
 8. Reddy CHS, Baliga M, Shetty P, Shenoy V. "Alveolar ridge augmentation by vertical distraction osteogenesis". *J Indian Prosthodont Society* 2003;3:39-43.
 9. Watzinger F, et al. "Computer-aided surgery in distraction osteogenesis of the maxilla and mandible"). *Int J Oral Maxillofac Surg* 1999;28:171-5.
 10. Cohen SR, Burstein FD, Stewart MB, Rathburn MA. "Maxillary-midface distraction in children with cleft lip and palate: A preliminary report". *Plast Reconstr Surg* 1997;99:1421-8.
 11. Rahn & Boucher "Textbook of Maxillofacial Prosthetic Principles and Concepts". Chapter VII.

