

Implant Prosthodontics: An in-vitro photoelastic stress analysis

Srinivasan M.¹, Padmanabhan T. V.²

¹Head of Department of Dentistry and Implantology, Atlas Star Medical Center, Dubai, U.A.E., ²Head of Department of Prosthodontics, Sri Ramachandra Dental College and Research Institute, Chennai, India

For correspondence

Murali Srinivasan, P.O. Box - 49207, Dubai, UAE. E-mail: murali@prodent.com

Arguably the greatest controversy in implant dentistry is that of linking a natural tooth and an implant together in a fixed restoration. Some researchers have absolutely contradicted the inclusion of the two, while others have suggested different options such as design considerations in the restoration or in the implant itself. Further more an outcome of a situation in linking a periodontally compromised abutment with an implant in a restoration itself lacks investigation. The study was designed to evaluate stresses transmitted to supporting structures by a fixed partial restoration under different abutment situations using a rigid / movable connector in the prosthesis. Also to evaluate stresses transmitted and the outcome of linking a periodontally compromised abutment with the implant in a fixed restoration. Photoelastic models were fabricated depicting a partially edentulous posterior mandible. The situations depicted were of a completely tooth supported, tooth implant supported and a completely implant supported situations. 20% and 35 % periodontal damages were also incorporated in the anterior abutment in the models. The fixed restorations were fabricated with movable and rigid type connectors. Vertical point loads were applied on fixed points on the restoration and the transmitted stresses under different simulated situations of the study were then recorded and analyzed. The fringe orders were recorded photographically and the fringe orders were tabulated for interpretation. After thorough analysis of the results obtained the study concluded that it is indeed beneficial to connect natural tooth to implants in a fixed partial restoration and that the type of connector advocated is a rigid one. Also conclusive is the fact that periodontally compromised teeth can be integrated in the restoration in combination with an implant as a conservative treatment option. The use of non rigid connectors in any situation may be erroneous.

Key words: Abutments, tooth implant connection, photoelastic stress analysis, Intrusion phenomenon, Implant prosthodontics, periodontally compromised abutments, rigid connector, non rigid connector

INTRODUCTION

The present day rationale for treating partially edentulous conditions, are greatly influenced by the various milestones achieved in the field of Osseointegration. Osseointegration has been successfully employed in patient treatment and over the past two decades implantology has changed the treatment options for the partially edentulous patient.^[1]

Arguably the greatest controversial issue in implant dentistry would be that of connecting implants and natural teeth in the same prosthesis. It has been suggested that the disparity between the relatively immobile Implant and the physiologically mobile tooth make the prosthesis to behave like a cantilever generating maximum resultant load as much as twice the load applied, in the implant.^[2] Other concepts such as '*Intrusion Phenomenon*' have also underscored the connecting of an implant with a natural tooth with a fixed partial denture and a definite need for '*Stress*

breaking' arises.^[3]

Major implant researchers have advocated various contrasting solutions. The Branemark System chose not to join single natural teeth with implants; the Core Vent System originally had a plastic coping insert available for splinting an implant to a natural tooth where stress breaking was deemed necessary.^[4] IMZ Implant System on the other hand uniquely imitated the stress distribution function through the use of an Intramobile Element (IME) made of Polyoxymethylene.^[5] Others suggested the use of a movable connector in the fixed partial denture design. Furthermore, the ailing periodontal condition of the abutment tooth attached to the implant in a fixed partial denture or the ailing periodontal condition of the implant itself over a period of years of service lacks investigation. The utilization of an abutment with compromised periodontium is surely unwarranted, but to what extent and why not are questions with definite differed opinions. Further, a movable connector incorporated in the

fixed partial denture design also gives the abutment the freedom of mobility while the rigid implant supposedly stays unaffected.

To Summarize, the study undertakes

1. To assess and evaluate the stresses transmitted by a fixed partial denture to the supporting structures under different abutment situations such as-Tooth supported, Tooth-Implant supported and totally Implant-supported.
2. To compare these with a rigid type and non-rigid type design incorporated in the fixed partial denture.
3. To further evaluate this stress transfer when varying degrees of periodontal damage is present on the anterior natural/implant abutment, so as to ascertain whether linking implants with compromised natural abutment is beneficial.

MATERIALS AND METHODS

Partially edentulous photo-elastic models simulating an edentulous situation of missing mandibular left first molar tooth were constructed for two dimensional Photoelastic testing and analysis.

The first sets of models consisted of natural abutments of mandibular left second premolar and second molar. For simplicity a single root configuration was chosen for the molar and the furcation space was eliminated.^[6] In the second sets of models, the second molar was replaced by a cylindrical press fit implant of 4mm diameter and 13 mm length (EZ Implant system); in the third there were only implants, where in, the premolar was also replaced by implant. A 9 mm separation was to be the standardized pontic space uniform in all the models for all the testing conditions in this study.^[4]

The first set depicted a natural teeth supported situation; the second, an implant-tooth supported situation; and the third, a totally implant supported situation. Also incorporated in the sets of models were conditions of varying degrees of periodontal damage pertaining to the anterior abutment. The degrees of periodontal damage were simulated as follows:

1. Normal - 0% periodontal loss,
2. Grade I - 20% periodontal loss,
3. Grade II - 35% periodontal loss.

Teeth with periodontal condition greater than Miller's Grade II, are usually not utilized as abutments in fixed partial restoration therapy.^[7] Hence not considered in the study parameters and the study restricts it self to only clinical feasible situations of periodontal damage of up to 35%.

The premolar root length was 12 mm. The criterion for normal attachment was simulated at 2 mm below the cemento-enamel junction.^[8] 20 and 35% periodon-

tal losses were assigned at 4.0 and 5.5 mm below the cemento-enamel junction respectively. The normal attachment in the case of the implant placed in the anterior region, in the totally implant supported situation models was at the level of the cover screw, 2 and 3.5 mm below the cover screw for 20 and 35% periodontal damage respectively.

The periodontal ligament (P.L.) of 0.3 mm thickness was simulated on the teeth, to be used in the photoelastic models, using polyvinyl siloxane impression material (Speedex, Coltene) of light body consistency.^[9] Tray adhesive (Kettenbach, Germany) was applied evenly over the root portions of the teeth to help facilitate adherence of the siloxane material to the photoelastic teeth simulants. The thickness of the P.L. was maintained by measuring the Labio-lingual and Mesio-distal diameters prior and post fabrication in three different confirmed locations of the root to ascertain uniformity [Figure 1].

The photoelastic simulants used for the teeth with tooth colored epoxy resin (Araldite, CIBA), periodontal ligament with polyvinyl siloxane impression material of light body consistency (Speedex, Coltene) and bone with transparent epoxy resin (Araldite, CIBA). A cylindrical press fit type Implant (EZ Implant System) was included in the second sets of models at the position of the second molar (posterior abutment); and in the third set at both positions of anterior and posterior abutments [Figure 2]. The condition representing complete integration was obtained by pouring the material slowly along the walls of the container until it covered the entire root portions. The resin was allowed to cure for 24 hours.

The teeth were prepared in accordance to the fundamentals of tooth preparation for a fixed partial restorative therapy. Conventional restorative techniques were used to fabricate fixed prosthetic restorations. Restorative procedures were accomplished by using transfer type copings with poly-vinyl siloxane impression material, addition type (Reprosil, Dentsply) and custom trays. All restorations were fabricated on stone casts. Restorative dimensions were consistent with the base parameters of occlusal plane and form. The dimensions of the restorations were kept constant with the use of a silicone putty index. The occlusal surfaces were made flat as recommended for similar types of two dimensional photoelastic studies.

All restorations were fabricated with a Ni-Cr alloy (Nickel chrome alloy, Yamahachi Dental Mfg. Co.). Two types of restorations were fabricated for each of the test conditions. The restorations differed among them only in the type of connection. The first type was fabricated with a rigid type connector, while the other with a custom semi-precision type movable connector. The semi -precision type connector was placed between the anterior abutment and the pontic. The semi

precision movable connector had a key and a keyway. The key was placed in the distal aspect of the anterior retainer while the keyway was placed in the mesial aspect of the pontic.

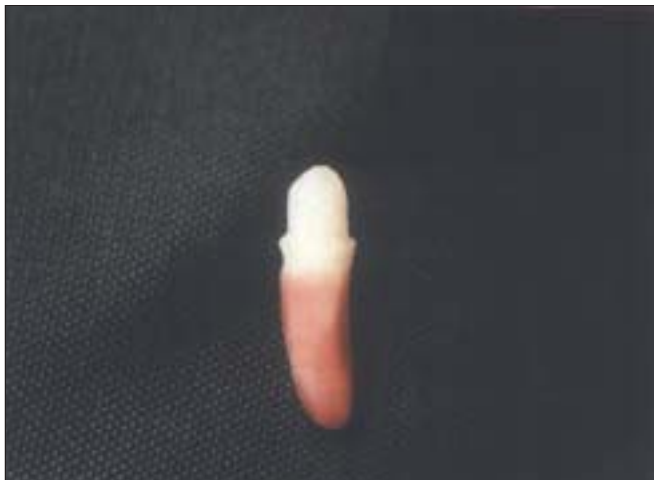

Figure 1: Simulated P. L. On Test Tooth




Figure 2: Fabricated Photoelastic Models



Figure 3: Simulated P.L. Test Tooth




Figure 4a: Fringe Orders During Loading. Loading being carried out on the anterior abutment in totally implant supported situation, using rigid connector and 0% periodontal damage



Figure 4b: Fringe Orders During Loading. Loading being carried out on the posterior abutment in totally implant supported situation, using rigid connector and 0% periodontal damage



Figure 4c: Fringe Orders During Loading. Loading being carried out on the pontic in totally implant supported situation, using rigid connector and 0% periodontal damage

Interchangeability of the restorations was verified on the models. The restoration was cemented with Zinc Phosphate cement (Harvard) on the photoelastic models and loading was carried out. Loads were applied in a straining frame, vertical point loads were applied at fixed identified locations on the occlusal surface of the tooth/Implant restorations. The loading Point locations were identified as follows:

1. Over center of Premolar/Implant,
2. Over center of Pontic, and
3. Over center of Molar/Implant.

These points were marked with a straight fissure bur for reproducibility and facilitate point load placement. Loads placed were 0, 50 and 100 lbs over each of the loading point locations.

These loads were selected, as they are realistic functional load levels and also provided a satisfactory optical response within the model. A record of residual stresses were noted and monitored prior to loading. The resultant stresses in all areas of the supporting structure were monitored and recorded photographically in the field of a transmission type polariscope. Each loading and observation sequence was repeated at least two times to ensure reproducibility of the results.

The fringe pattern findings and data were collected for the loading subjected to each situation of restorative connection and loading positions.

RESULTS

Vertical point loads were applied on fixed identified locations on the occlusal surfaces of the restoration. Observations for each loading for the different situations in the study were photographically recorded. The fringe orders were then calculated from the photographs and were tabulated in [Table 1] [Figures 3, 4a, 4b, 4c].

During loading the anterior abutment

Loading on the anterior abutment site on the prosthesis with rigid type connector, showed that the fringe orders clearly increased in the anterior abutment region as the degree of periodontal support deteriorated. The fringe orders were however constant on the posterior abutment region. The fringe orders depicted the same change when loads were applied for a non-rigid type of restoration, i.e, the orders increased as the periodontal support decreased. There also appeared a slight difference between that of the restorations with rigid and non-rigid type of connection. The non-rigid type showed slightly increased fringe orders on the anterior abutment, while the stresses transmitted by the posterior abutment were constant and were minimal compared to the stresses exerted in the anterior

region even with a non rigid connection. The increase in the fringe orders was directly dependent on the increase in applied loads.

During loading the pontic region

The fringe orders observed in the anterior abutment and the posterior abutment regions showed no changes for restorations with the rigid type and the non-rigid type connectors. However, the fringe orders increased with a decrease in the periodontal support on the anterior abutment, while the fringe orders in the posterior abutment decreased; showing an increased stress transmission to the compromised abutment. The magnitude of the fringe orders increased with increase in load as seen similar in premolar loading.

During loading the posterior abutment

The fringe orders showed a constant increase at the anterior abutment site with deteriorating periodontal support irrespective of the type of connection. The fringe orders at the posterior remained unchanged. The fringe orders increased with the increase in loads applied as seen with the other two loading conditions.

The fringe orders observed showed a consistent similarity between the tooth-supported, tooth-implant supported and totally implant supported situations. The magnitudes, however, increased with tooth implant-supported and totally implant supported situations when compared with tooth-supported situation and also in compromised periodontal conditions in the tooth supported situation.

DISCUSSION

The treatment of partial edentulism with fixed partial prostheses has always been a highly recommended form of treatment plan. The absence of key abutments have however been substituted presently by the use of osseointegrated fixtures.

Every restoration must be able to withstand the constant occlusal forces to which it is subjected. This is of particular significance when designing and fabricating fixed bridges, as the forces which are normally absorbed by the missing tooth are transmitted, through the pontic, connector, and retainers, to the abutment teeth.^[10] This criteria though related to other factors involved in the abutment evaluation, depends to a very large extent on the presence of sound periodontium and the area of periodontal ligament attachment of the root to bone. It is advocated that when supporting bone has been lost because of periodontal disease the teeth involved may have a lessened capacity to serve as abutments. This may be attributed to the well advocated physical functions of the periodontal ligament complex, resistance to the impact of occlusal

Table 1: Fringe orders under different loads for different parameters

Type of Support	Degree of Periodontal Damage %	Load in lbs.	On Anterior Abutment		Loading		On Pontic		Loading		On Posterior Abutment		Loading	
			Rigid connector	Movable connector	Rigid connector	Movable Connector	Rigid Connector	Movable Connector	Rigid Connector	Movable Connector				
Totally Tooth Supported	0	50	3 2	3 1	4 3	4 3	2 2	2 2	2 2	2 2	2 2	2 2	2 2	2 2
		100	9 3	9 2	8 4	8 4	3 4	3 4	3 4	3 4	3 4	3 4	3 4	3 4
	20	50	5 2	6 1	5 2	5 2	3 2	3 2	2 2	2 2	2 2	2 2	2 2	2 2
		100	10 3	10 2	9 3	9 3	4 4	4 4	3 4	3 4	3 4	3 4	3 4	3 4
	35	50	6 2	7 1	5 2	5 2	3 2	3 2	2 2	2 2	2 2	2 2	2 2	2 2
		100	11 3	11 2	9 3	9 3	4 4	4 4	3 4	3 4	3 4	3 4	3 4	3 4
Tooth - Implant Supported	0	50	5 1	6 0	3 2	3 2	1 2	1 2	1 2	1 2	1 2	1 2	1 2	1 2
		100	8 2	9 1	5 3	5 3	2 4	2 4	2 4	2 4	2 4	2 4	2 4	2 4
	20	50	6 1	6 0	4 1	4 1	2 2	2 2	1 2	1 2	1 2	1 2	1 2	1 2
		100	9 2	10 1	7 2	7 2	3 4	3 4	2 4	2 4	2 4	2 4	2 4	2 4
	35	50	6 1	7 0	5 1	5 1	3 2	3 2	2 2	2 2	2 2	2 2	2 2	2 2
		100	10 2	11 1	8 2	8 2	4 4	4 4	3 4	3 4	3 4	3 4	3 4	3 4
Totally Implant Supported	0	50	6 2	6 1	9 5	9 5	4 11	4 11	4 9	4 9	4 9	4 9	4 9	4 9
		100	13 3	13 2	15 9	15 9	6 18	6 18	6 14	6 14	6 14	6 14	6 14	6 14
	20	50	9 2	10 1	10 4	9 4	5 11	5 11	5 9	5 9	5 9	5 9	5 9	5 9
		100	17 3	18 2	16 8	12 8	7 18	7 18	7 14	7 14	7 14	7 14	7 14	7 14
	35	50	12 2	13 1	10 4	11 4	6 11	6 11	5 9	5 9	5 9	5 9	5 9	5 9
		100	20 3	21 2	17 8	18 8	8 18	8 18	7 14	7 14	7 14	7 14	7 14	7 14

forces - 'Shock Absorber Effect' as documented by Caranza and Newman.^[8] On the contrary, there is evidence that teeth with compromised periodontal support can serve successfully as fixed bridge abutments.^[10]

The degree of periodontal compromise in an abutment tooth to be utilized in a fixed prosthesis is however restricted, to grade +1 or +2 mobility. This is evidenced by Balshi, who cites that only those teeth with +1 or +2 mobility should be considered for connected stabilization.^[11] Though, these teeth are utilized only in a status quo to prevent a further increase in mobility, the redistribution of forces to these teeth through the prosthesis to the underlying structure needs evaluation. The evaluation of the anterior abutment is undertaken in this study as during the placement of the implant the bone margin would be considered normal and only the anterior tooth in question would have compromised periodontal support.

Early researchers have advocated the marginal bone loss around the implant after loading and subsequent marginal bone losses annually as 1.5mm and 0.1mm respectively.^[12] While recent researchers make it clear that the annual bone loss observed during the first year was 0.8mm and decreased to 0.1mm during the following years which is within the range.^[13] This however illustrates that though the procedures followed during the placement of the implant may be under controlled conditions bone loss associated with an osseointegrated fixture is inevitable and must be accounted for in the treatment planning as a foresight. Hence a consideration in the ongoing bone loss associated with the osseointegrated fixtures was evaluated

by studying the stress distribution in a totally implant supported condition with a compromised bone levels of 20 and 35% on the implant placed at the premolar region, and compared it with a tooth-supported, and tooth - implant supported situations with the use of rigid and non - rigid connectors incorporated in fixed partial denture design.

Based on theoretical assumptions, an integrated implant connected to a natural tooth in a fixed prosthesis would take up more of the load. This has been documented by Misch *et al* in their finite element analysis of tooth - to - implant fixed partial denture design.^[14] Integration of natural teeth into a restoration remains a point of discussion because of the differential mobility between teeth and implants. The Branemark system have strongly recommended against linking natural teeth with osseointegrated fixtures due to movement of the natural abutment with in the limits of its periodontal ligament.^[15] Van Steenberghe, Balshi, Gunne *et al*, Cavicchia/Bravi conclude that direct connection between abutments and natural teeth causes no periodontal or mechanical problems.^[11,16-18] Balshi further concludes that osseointegrated fixtures can also be used to stabilize teeth when the natural dentition has suffered from diminished periodontal support.^[11] Furthermore, linking osseointegrated fixtures to natural teeth may be useful in helping patient to perceive better proprioception. This hypothesis is well documented by Cavicchia and Bravi.^[18] The use of non - rigid design has been advocated in fixed partial dentures, which link natural teeth with implants. The disparities in the mobility of the natural teeth and implant logically warrant some sort of stress breaking

or stress equalizing when both these are combined together in a fixed partial denture. But controversies exist. Schlumberger though have advocated the use of non-rigid connection in the fixed partial denture design, Mirsch *et al*^[7] conclude that a non-rigid connection may be erroneous because of a biomechanical disadvantage.^[14,19]

This was elucidated by Mirsch *et al* where they documented that - A rigid restorative condition resolves more stress internally before it can reach the supporting tissues. However, a non-rigid connection between a pontic and an abutment would alter this load distribution.^[14] With a non rigid design the stress may be directed through the tooth abutment to the supporting bone rather than being concentrated in the connector or tooth root,^[14] hence a redirection of stress was found in the bone simulant of the photoelastic model surrounding the tooth root supporting the non-rigid prosthesis.

The findings were consistent in all three parameters of tooth-supported, tooth-implant supported and totally implant supported fixed partial dentures. Although similar conclusions can be drawn in favor of tooth-supported and tooth-implant supported situations. The similar findings demonstrated in totally implant-supported bring to light the effect of simulated decrease in bone levels around the implant in stress distribution and transfer. These findings are however congruent with those of the tooth-supported and tooth-implant supported situations in spite of the fact the absence of periodontal ligament complex around an osseointegrated fixture. This concludes that the stress transferred to the supporting structures by the implant is directly dependent on the load applied and the bone height around the fixture. The increased transmitted stresses due to decreased bone support were further accentuated with the incorporation of a movable connector for similar reasons explained earlier. However the study demonstrated no significant changes in the stress transfer when loading was carried out on the pontic and molar regions, be it a rigid type of connection or a non-rigid type of connection in the fixed prosthesis. This could be explained by the design of the non-rigid type of connection which employed a key and a key way type of connection placed between the anterior abutment and the pontic with the key situated within the anterior abutment retainer and the key way within the pontic. This design is in accordance with the design advocated by Schlumberger. The fringe orders however showed similar consistent increase in the anterior abutment sites as was for reasons explained above. Furthermore, the fringe patterns showed a decrease in the posterior abutment site when the loading was carried on the pontic region, indicating a definite transfer more to the compromised abutment. The findings suggest that there are no signifi-

cant differences between the stress transfer patterns with either a rigid or non-rigid type of connection. A non-rigid type only further increases stress transfer on the compromised abutment. A rigid type connection however has demonstrated a well-distributed stress pattern in the study. The study further demonstrated, in the tooth-implant supported situation, where the fringe orders recorded at the implant site were similar to that of the molar site in the other parameter. This may be explained by the transfer of stress to the physiologically mobile tooth, which has the capacity to absorb and redistribute through the function of the periodontal ligament complex thus minimizing the load transfer by the implant.

CONCLUSION

After careful analysis of the obtained results of this in-vitro two dimensional photoelastic study, the conclusions drawn are as follows:

1. It is beneficial to connect Implants to natural teeth in a fixed partial prosthesis rather than freestanding totally implant assisted fixed partial denture.
2. The use of a non - rigid connector does not play a remarkable role in the stress transfer when compared to the rigid connection type. On the contrary, a rigid connector distributes stresses more uniformly through the abutments in a combination or a free standing situation and help in stabilizing a periodontally-compromised situation.
3. The non-rigid type connection should never be advocated in cases of abutments with compromised periodontium, as it only deteriorates the situation further.
4. The connection of periodontally compromised teeth, with implants may be beneficial for a limited period of time and may be a conservative mode of treatment option.

ACKNOWLEDGEMENTS

Dr. V. Bhaskar, PhD, Asst. Professor, Dept. of Aeronautical Engineering, MIT, Chennai, for providing his expertise in the field of photo-elastics and Dr. Bell Raj Eapen, MD, DNB, MSc, for his invaluable help in manuscript preparation.

REFERENCES

1. Misch CE. Contemporary Implant Dentistry. 2nd edn. Mosby, 1999.
2. Lundgren D, Laurell L, Falk H, Bergendal T. Occlusal Force Pattern During Mastication in Dentitions with Mandibular Fixed Partial Dentures Supported on Osseointegrated Implants. J Prosthet Dent 1987;58:197-

- 203.
3. Pesun IJ. Intrusion of Teeth in the Combination Implant - to - Natural - Tooth Fixed Partial Denture: A review of Theories. *J Prosthodont* 1997;6:268-77.
4. Nishimura RD, Ochiai KT, Caputo AA, Jeong CM. Photoelastic Stress Analysis of Load Transfer to Implants and Natural Teeth Comparing Rigid and Semi - Rigid Connectors. *J Prosthet Dent* 1999;81:696-703.
5. Uysal H. An Experimental Analysis of the Stresses on the Implant in an Implant - Tooth - Supported Prosthesis: A technical Note. *Int J Oral Maxillofac Implants* 1997;12:118-24.
6. Kuroe T, Itoh H, Caputo AA, Nakahara H. Potential For Load - Induced Cervical Stress Concentration as a Function of Periodontal Support. *J Esthet Dent* 1999;11:215-22.
7. Schilenburg, Hobo, Whitsett. *Fundamentals of Fixed Prosthodontics*. 2nd edn. Quintessence Books, 1981.
8. Newman, Caranza. *Clinical Periodontology*. 8th edn. W. B. Saunders Company; 1996.
9. Breeding LC, Dixon DL, Sadler JP, McKay ML. Mechanical Considerations for the Implant Tooth - Supported Fixed Partial Denture. *J Prosthet Dent* 1995;74:487-92.
10. Schilenburg, Hobo, Whitsett. *Fundamentals of Fixed Prosthodontics*. 2nd edn. Quintessence Books; 1981.
11. Balshi TJ. Advantages and Disadvantages of Linking Implants to the Natural Dentition. *Oral Maxillofac Surg Clin North Am* 1991;3:945-63.
12. Adell. Clinical Results Of Osseointegrated Implants Supporting Fixed Prosthesis In Edentulous Jaws. *J Prosthet Dent* 1983;50:251-4.
13. Quirynen M, Van Steenberghe D. A Study of 589 Consecutive Implants Supporting Complete Fixed Prostheses: Periodontal Aspects. *J Prosthet Dent* 1992;68:655-63.
14. Misch CM, Ismail YH. Finite Element Stress Analysis of Tooth - to - Implant fixed partial denture design. *J Prosthodont* 1993;2:83-92.
15. McGlumphy EA. A Comparison of the Stress Transfer Characteristics of a Dental Implant with a Rigid or a Resilient Internal Element. *J Prosthet Dent* 1989;62:586-93.
16. Van Steenberghe D. Retrospective Multi-Centre Evaluation of the Survival Rate Osseointegrated Fixtures Supporting Fixed Partial Prostheses in the Treatment of Partial Edentulism. *J Prosthet Dent* 1989;61:217-23.
17. Gunne J. Tooth - Implant and Implant supported fixed partial dentures: A 10- Year Report. *Int J Prosthodont* 1999;12:216-22.
18. Cavicchia F, Bravi F. Free Standing vs. Tooth - Connected Implant Supported Fixed Partial Restorations: A Comparative Retrospective Clinical Study of the Prosthetic Results. *Int J Oral Maxillofac Implants* 1994;9:711-8.
19. Schlumberger T, Bowley, Maze. Intrusion Phenomenon in Combination Tooth - Implant Restorations: A Review Of literature. *J Prosthet Dent* 1998;80:199-203.

