

Case Report

Prosthetic rehabilitation of hemi-mandibulectomy patient

Rajni Dable, P. Balaji, Smita Athavale

Department of Prosthodontics, Dr. D. Y. Patil Dental College and Hospital, Pimpri, Pune, Maharashtra, India

For correspondence

Dable Rajni, Flat No.1, Devki Ashish Apartment, Devki Nagar, Borivali (W), Mumbai - 400 103, India. E-mail: rajnidable@hotmail.com

Maxillofacial prosthodontics is an art and science which provides life-like appearance to the disfigured person. Even if this person is left out and considers himself inferior in the society, a prosthodontist helps him out and provides a better place in the society. Here, we are presenting a case of hemimandibulectomy, where the economical replacement was needed. Cheek prosthesis is fabricated by using a thermoplastic material to provide and improve adhesive qualities to the prosthesis.

Key words: Maxillofacial prosthesis, cheek prosthesis, use of thermoplastics as adhesive

INTRODUCTION

Maxillofacial Prosthodontics is the world of art and science, which is full of challenges. Here there are no limitations to your imaginations and one can not apply the inferences drawn while treating a patient to another. It is true that one has to strive for getting the natural function and lifelike appearance of the prosthesis. As we know-“Every human has the divine right to look human”.

Keeping this philosophy in mind, a prosthodontist has to work to return the affected individual back to the society. Advances in techniques and materials have been remarkable in the past several years. But the realization of the full potential and the utilization of maxillofacial prosthetics is still lagging behind.

There is a well known quote given by a German surgeon about the patient with facial disfigurement. He quotes “at the sight of whom all men turn in disgust and abhorrence and at whose presence children cry and dogs bark”.

This statement proves to be true in today’s modern world as well. The manner of looking at such people has not changed much. Sometimes, even if the disfigurement is slight, the psychological wound is so great, that the disfigured person himself avoids social contacts. It is very important to give special consideration to such patients. Here, presenting a Prosthetic rehabilitation of hemimandibulectomy patient A 38 years old male patient was referred to our institution, for prosthetic rehabilitation.

Extra oral examination:

The patient’s mandible on the left side was resected, leading to hollowness of mouth and punched out face, disturbing the profile.

PAST DENTAL AND MEDICAL HISTORY

The patient gave a history of eating Gutka for about 15 years before surgery. When he reported to the hospital, it was seen that an ulcerative growth in the retromolar trigone was present, which measured 4x3 cm and extended to the buccal sulcus. The angle of mouth was totally destroyed. As he underwent total extraction before surgery, he needed complete dentures to restore the lost function and aesthetics.

Intraoral examination

- Because of resection of affected mandible, there was no alveolar ridge present on the left side [Figure 2].
- The oral mucosa in this region was too inelastic due to the reconstruction of the resected region which was done with the help of PMMC flap.
- Severe trismus was present.
- No teeth were present in the mouth.
- On the right side, the alveolar ridge had collapsed because of surgery.

Extremities of mandibular denture

On the right side, normal bone and tissue was available, but on the left side, the denture extremities were limited – medially by base of the tongue, laterally by

buccal tissues of the cheek, anteriorly by the resected end of other half of the mandible and posteriorly by the posterior area contributing the sulcus and vestibule.

Clinical approach

Patient's Interview

As it is always advisable to interview the patient efficiently in pleasant surroundings before starting the actual procedure, so as to take out full information of his mental and physical status. After thorough history, a clinical plan was scheduled for providing the intra-oral prosthesis first.

Prosthodontic approach

Pre-definitive treatment

- As mentioned before, the alveolar ridge on the other side had collapsed, which needed to be taken care of first. We planned to correct this by giving him a guiding plane in the maxillary denture and a centric stop along with an occlusal ramp in the mandibular denture.
- The dentures were fabricated by conventional method and the dentures were processed.
- Full bulb was provided in the mandibular denture.
- A guiding plane was constructed on the palatal aspect in the posterior region of the maxillary denture to guide the lateral movements, while a ramp was built with autopolymerising resin in the posterior occlusal region of the mandibular denture with a prominent mount, holding and stabilizing both maxillary and mandibular teeth. These dentures were inserted in the patient's mouth and he was asked to use them at least for 6 months. The patient was scheduled for a recall every fortnight.

Definitive phase

- As the patient was constantly under observation, after about 8 months, it was noticed that he was occluding in centric relation without much effort.
- At this stage, the conditions were favorable for receiving the definitive treatment.
- The master casts fabricated from the previous impressions were used here to make custom trays. His dentures were not used for any purpose, as it was necessary to make the patient wear those dentures till the final prosthesis was ready, to avoid collapsing of the remaining alveolar ridge again. Another final impression was made using elastomeric impression material and dentures were fabricated by conventional method again.
- Maxillomandibular jaw relation record was made.
- Artificial teeth were selected and arranged.
- Dentures were fabricated in heat activated denture

base acrylic resin.

- Dentures were seated in the mouth and evaluated accuracy.

Extraoral cheek prosthesis

After inserting the dentures in the patients' mouth, the next step was the reconstruction of the face on the affected side to provide it a proper contour. In this case, the biggest problem was the cost factor, as the patient was from the lower income group. An effort was made to provide a prosthesis that was economical, yet satisfactory.

The step-by-step procedure done is as follows:

- Facial impression to receive moulage.
- A thermoplastic material was used here to improve the adhesion between the prosthesis and the underlying skin [Figures 1-6].

Thermoplastics

- These are the thermoplastics used by orthotists and prosthetists for splint applications in rehabilitation.
- These very safe and easy to handle.
- This material has got extreme elasticity (1000%) without tearing.
- Elastic memory: It is completely reproducible.
- Reliable adhesion: It is self adhesive and accessories can be applied with ease.

It has excellent adhesive qualities without any glue or technical solvents.

- It becomes transparent on reaching activation temperature, (melting temperature of 60°C), so the underlying anatomy is constantly monitored.
- It has maximum precision in following the anatomical contours.
- It is lighter than water and does not add to the weight of the prosthesis.
- Low shrinkage, resulting in a stable shape and dimension.
- * The thermoplastic material (available in sheet form) is used here, to provide a tight contact of the prosthesis with the skin, to improve it's adhering qualities.
- * This material is available as a thin sheet, with or without perforations.
- * The required amount of sheet is cut easily with the help of a hot knife and kept in a bowl of hot water (temp. between 60-80°C)
- * When the material was soft enough, it was adapted over the model. The borders were flushed properly to get merged with the skin.
- * This was then tried on the patient's face to check




Figure 1: Thermoplastic material available in sheet form

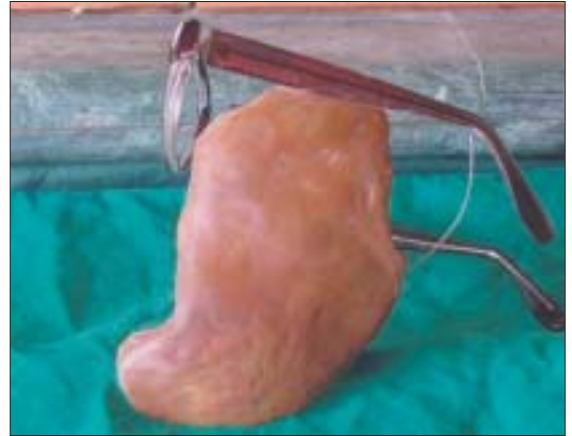

Figure 4: Prosthesis with retentive AIDS. (Facial side)



Figure 2: Perforated and nonperforated thermoplastics

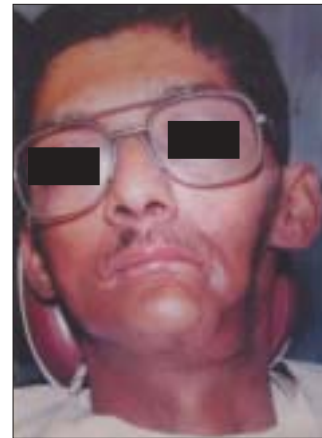

Figure 5: Patient before facial rehabilitation

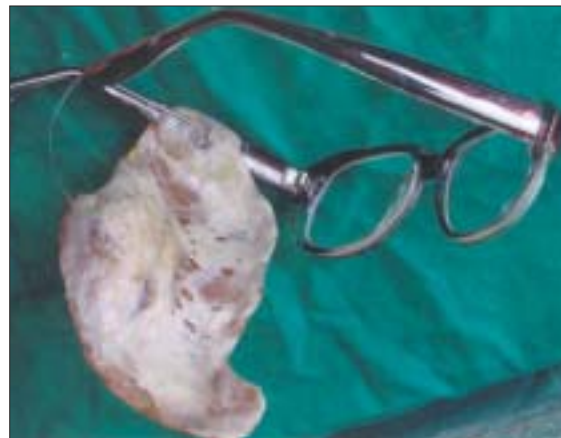

Figure 3: Prosthesis with retentive AIDS. (Tissue side)



Figure 6: Patient after facial rehabilitation

- the adaptation.
- * Auto polymerizing acrylic resin was used to construct the final prosthesis.
 - * Thickness and contour was maintained as per the other side.

- * After the polymerization, the prosthesis was finished and polished properly

Coloring the prosthesis

- Coloring and final featuring was planned to be done directly on the face, in the laboratory, in presence of sunlight.
- For coloring the prosthesis, oil based dyes were

used. Standard brown and skin colors were mixed and blended uniformly in clear autopolymerising acrylic resin and applied layer by layer on the prosthesis, by repeatedly checking on the patient and comparing with the natural skin color.

- Retaining aids planned were; a wire part encircling the ear to support laterally and spectacles attached to support superiorly.
- A 19 gauge wire was molded and attached to the prosthesis with the help of acrylic.
- The spectacle (selected as per his eyesight) was attached to the prosthesis again by cutting a groove on its side arm.

CONCLUSION

The patient's intra-oral and extra-oral defects were successfully restored and he was rehabilitated in society by using simple, economical yet satisfactory means and materials. It is now ten months after the definitive prosthesis was provided. Regular recall

protocol is maintained.

ACKNOWLEDGMENTS

Dr. Mukesh M. Doshi, Prosthetist and Orthotist, Director, P.O.C.L. Mumbai.

REFERENCES

1. Brown KE. Complete Denture Treatment in patients with resect mandibles., JPD 1969;21:443.
2. Swoope CC. Prosthetic Management of the resected edentulous mandibles. JPD 1969;21:197.
3. Oral reconstruction of the edentulous partial mandibulectomy patient, JPD 1976;36:292.
4. McKinstry RE. Fundamentals of Facial Prosthetics, ABI Professional Publications, Arlington; 1995. p. 22-3, 33-40.
5. Chalian VA, Drane JB, Standish SM, Maxillofacial Prosthetic Baltimore, Williams and Wilkins Co.; 1972. p. 127.
6. Arthur O. Rahn, Maxillofacial Prosthetics Principles and Concepts, W. B. Saunders Co. Toronto; 1970. p. 127.

Abstract

Distribution around maxillary implants in anatomic photoelastic models of varying geometry. Part I

Martin D. Gross, Joseph Nissan, Rellu Samuel

The Maurice and Gabriela Goldschleger School of Dental Medicine, Tel Aviv University, Tel Aviv, Israel

Statement of Problem: It is unclear which implant inclination and position are most favorable in relation to the supporting anatomy and loading direction in the maxilla. **Purpose:** This study was designed to examine stress distribution around implants in a 2-dimensional photoelastic anatomic model. **Materials and Methods:** Two 2-dimensional photoelastic models were prepared with opposing 8-degree cylinder metal implant and molar teeth analogues. A frontal anatomic sectional plate model based on a CT section at the first molar was symmetrically loaded through its long axis. A midfacial rectangular model based on the same section was loaded in a different direction with varying supporting geometries. **Results:** Stress distribution around the maxillary implant was highest in the buccal concavity at the apical buccal third and in the lingual concavity on intercuspal loading. No stress concentration occurred at the implant apex under the sinus for axial and nonaxial loading in both anatomic model geometries. On lateral loading, stress concentration was observed at the buccal concavity and at the implant neck. In the midfacial block model, principal stresses were concentrated at the maxillary implant neck on nonaxial loading and at the apex on axial loading. **Conclusion:** This 2-dimensional skull model showed different patterns of stress distribution among the maxillary implant, mandibular implant, and teeth. The highest principal stress concentration was seen at the buccal concavity of the maxillary implant; this may play a role in osseointegration with highly angled implants in the posterior.