

## Case Report

# Rehabilitation and assessment of speech and mastication in bilateral total maxillectomy patient

**Kanchan P. Dholam, Ghazwan A. Quazi\*, Gurmit K. Bachher\*\***

Departments of Dental and Prosthetic Surgery, \*Surgery (Plastic) and \*\*Head and Neck Services, Tata Memorial Hospital, Dr. E. Borges Road, Parel, Mumbai - 400 012, India

### For correspondence

Kanchan P. Dholam, Dept. of Dental and Prosthetics Surgery, Tata Memorial Hospital, Dr. E. Borges Road, Parel, Mumbai - 400 012, India. E-mail: [kdholam@hotmail.com](mailto:kdholam@hotmail.com)

The clinical management of a patient with bilateral maxillectomy is reported. Reconstruction of the hard palate, nasal wall, maxillectomy site and cheek skin was done with free fibular osteomyocutaneous flap. Prosthetic rehabilitation with secondary insertion of osseointegrated implant was planned for this patient. This patient was assessed for speech and mastication with altered oral anatomy after rehabilitation.

**Key words:** Mastication, maxillectomy, prosthesis, rehabilitation, speech

Bilateral maxillary resection presents unique challenges in prosthetic rehabilitation. Inadequate retention, support and stability are common prosthodontic challenges for a patient with bilateral complete maxillectomy. A successful rehabilitation should include the re-creation of the partition between the oral and nasal cavities.<sup>[1]</sup> Successful replacement of such a partition improves deglutition, enhances speech intelligibility and restores esthetics. Available options include flap reconstruction, prosthetic restoration and combinations of the two. Prosthetic stability and retention is highly questionable for bilateral maxillectomy defects leading to oronasal fistula, inability to eat and speak. Restoration of the upper alveolar arch and closure of the oronasal fistula are important steps in rehabilitating masticatory function and facial appearance. Functional reconstruction is recommended to resolve these problems. The goals of midface or bilateral maxillectomy reconstruction include separation of oral and nasal cavities to allow adequate articulation and deglutition, support of the orbital contents to prevent enophthalmos and diplopia, support of the soft tissues to restore the midfacial contour and replacement of skin surface defects to provide an acceptable cosmetic result.<sup>[2]</sup> Reconstruction with fibular osteocutaneous flap with osseointegrated implants provides a favorable foundation for prosthodontic treatment. Assessment of speech and masticatory function following rehabilitation with fibular osteomyocutaneous flap reconstruction with osseointegrated implants is reported.

## MATERIALS AND METHODS

A 17-year-old boy reported with recurrent mucoepidermoid carcinoma of intermediate grade involving the left maxillary sinus, left lateral wall of the nose, left alveolus, hard palate and underlying bone extending up to the soft lesions of the cheek [Figures 1 and 2]. Left maxillectomy with total excision of palate and reconstruction was done in March 2002. For optimal functional reconstruction and subsequent dental rehabilitation, free fibular osteomyocutaneous flap was used for reconstruction followed by radiotherapy. Bone with pedicle flap was obtained from the fibula. Three osteotomies were required for proper shaping of the fibula in the form of the maxillary arch. Fixation of the flap was done to the zygoma. Titanium miniplates and screws were used for fixation. Vascular anastomosis of the facial artery and lingual facial trunk was performed. All cut margins were free of tumor. All nodes in the neck were negative for tumor. The radiation dose delivered was 50Gy. After completion of one year of radiotherapy the patient was assessed for dental rehabilitation with osseointegrated implant retained upper complete denture. [Figure 3]. Three threaded implants, (one of 4.2 x 8.0 mm and two of 3.7 x 8.0 mm) [EZ Hi-Tec from Israel] were surgically inserted into the reconstructed fibular bone [Figures 4 and 5]. One implant was exposed after two months, hence the cover screw was removed and healing cap attached. After six months the other two implants were exposed and healing cap

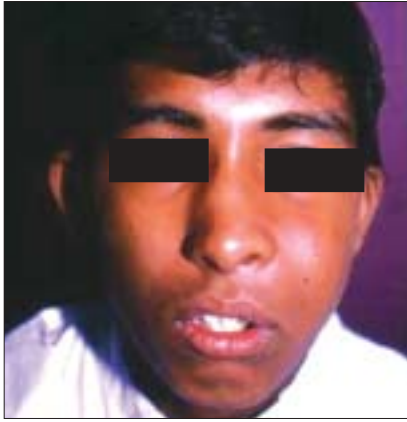

Figure 1: Preoperative - extra oral

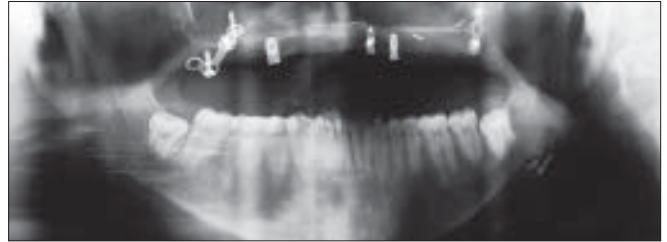


Figure 5: OPG - showing 3 implants in the grafted bone

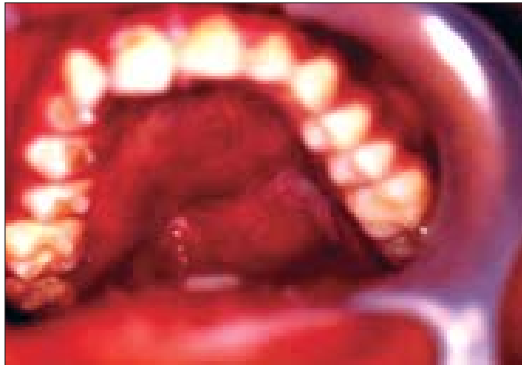

Figure 2: Intra oral - palatal lesion

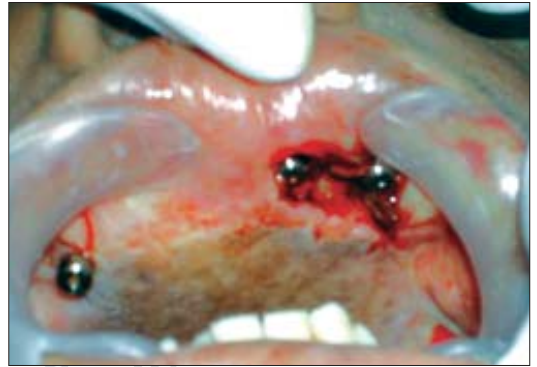

Figure 6: Second Stage - Implant surgery

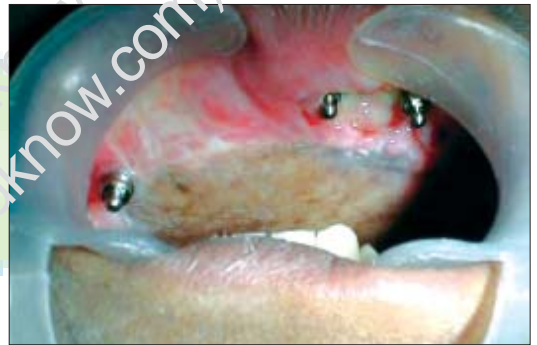

Figure 7: Postoperative view shows dallabona attachments

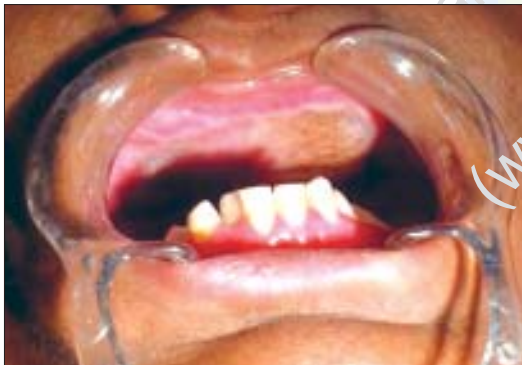

Figure 3: Postoperative - intra oral

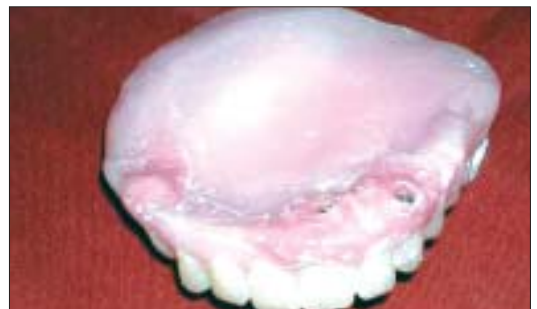

Figure 8: Dentures - tissue surface showing female component of the dallabona attachments

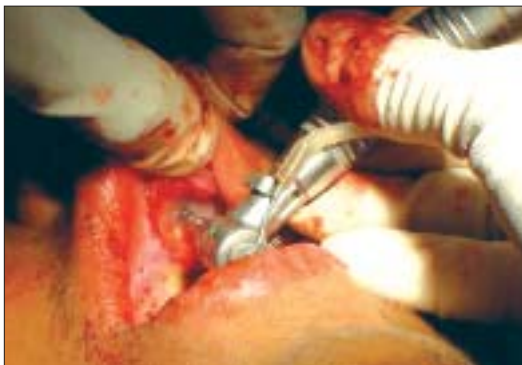

Figure 4: Surgical insertion of implant

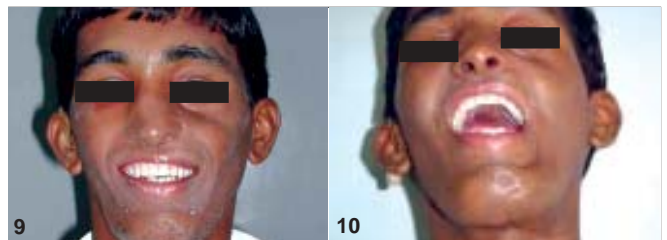

Figure 9 and 10: Posttreatment - extra oral view

attached [Figure 6]. Dallabona abutments were placed on the implants [Figure 7]. The female part of the dallabona attachments were inserted into the tissue surface of the dentures [Figure 8]. An acrylic complete denture was fabricated and retained on the implants with dallabona attachments [Figures 9 and 10]. Postoperative evaluation of the patient after one year of dental rehabilitation with implant-retained prosthesis was done.

1. Mastication to variety of foods: Mastication and swallowing were assessed. A questionnaire for assessing deglutition based on dietary habits of Indians designed by Bachher was utilized in this study.<sup>[3]</sup> The questionnaire consisted of information on evaluation of deglutition, salivation, status of mandible and teeth in relation to pre-rehabilitation status.
2. Speech: Patient was given therapy three times a week for the period of three months. Duration of each session was 30-40 min. He was shown the placement of every consonant and asked to practice it in a proper way. The single syllable was followed by training to speak small words, phrases, sentences and then in conversation. Initially, the patient had difficulty in swallowing. He was shown how to swallow liquids drop by drop to improve the coordination of the oral musculature. After improvement in liquid swallowing he was demonstrated how to eat soft food slowly to avoid regurgitation. This way he was able to consume his normal diet within two months. After three months the patient was asked to come for therapy once a week for next three months to find out the efficiency of articulation and deglutition. Objective evaluation with three selected syllables namely 'kaap', 'keep', 'kuup' pre and post treatment was done. It was analyzed using Dr. Speech software (Version 4.0) from Tigers Inc, U.S.A. for selected parameters viz. fundamental, habitual frequency, maximum, minimum frequency and intensity, frequency range, jitter, shimmer, s/z ratio and maximum phonation time (MPT). Student's 't' test was used to analyze the data with the statistical software SPSS version 10.0.

## RESULT

Following surgery the patient was suffering from bilateral severe mixed hearing loss leading to hypernasal and unintelligible speech. He was using behind-the-ear type hearing aid. Articulation of alveolar and dental sounds were affected. After insertion of the implant retained prosthesis exercises were shown to improve deglutition and articulation. A year later it

was noted that the patient's nasality was remarkably reduced. After fitting the dentures, speech training was given to improve articulation. He was able to pronounce all the syllables correctly in isolation as well as during conversation. Before speech therapy sessions he was not able to pronounce alveolar and dental sounds. He was able to sustain air and continue phonation up to 16.26 sec. (pre-treatment MPT was 12.40 secs.). No noted difference was found in other speech parameters except maximum intensity (54dB to 73.20dB). Now the patient is able to eat solid food without any difficulty, but requires more time to eat his meals. Patient has good quality of speech with better articulation and phonation. Masticatory function was restored to its optimum efficiency. Facial appearance too is highly appreciable when compared to preoperative status as is seen in photograph. Thus functional reconstruction and rehabilitation was achieved after bilateral maxillectomy.

## DISCUSSION

The standard treatment for reconstruction of a bilateral lower maxillectomy defect is a prosthesis without any tissue transfer; this procedure can cause problems with speaking and eating due to the instability of the prosthesis and oronasal fistula. Restoration of the upper alveolar arch and closure of the oronasal fistula with fibular osteocutaneous flap and osseointegrated implants were important steps in rehabilitating masticatory function and facial appearance.<sup>[4]</sup> This procedure provides a favorable foundation for prosthodontic treatment and contributes to improved quality of life without any complications.

## REFERENCES

1. Cheng AC, Somerville DA, Wee AG. Altered prosthodontic treatment approach for bilateral complete maxillectomy: A clinical report. *J Prosthet Dent* 2004;92:120-4.
2. Panje WR, Hetherington HE, Toljanic J, La Velle WE, Fyler A. Bilateral maxillectomy and midfacial reconstruction. *Ann Otol Rhinol Laryngol* 1995;104:845-9.
3. Bachher GK. Effective speech and psychotherapeutic programme for head and neck cancer patients. Unpublished doctoral thesis. SNDT University, India.
4. Nakayama B, Matsuura H, Ishihara O, Hasegawa H, Mataga I, Torii S. Functional reconstruction of a bilateral maxillectomy defect using a fibula osteocutaneous flap with osseointegrated implants. *Plast Reconstr Surg* 1995;96:1201-4.

Source of Support: Nil, Conflict of Interest: None declared.