

The Journal of Indian Prosthodontic Society is indexed/listed with DOAJ, Health and Wellness Research Center, Health Reference Center Academic, InfoTrac One File, Expanded Academic ASAP, ProQuest Databases, Genamics JournalSeek, and Ulrich's International Periodical Directory.

The journal is official publication of the **Indian Prosthodontic Society**, and issues are published quarterly in the last week of March, June, September and December.

All the rights are reserved. Apart from any fair dealing for the purposes of research or private study, or criticism or review, no part of the publication can be reproduced, stored, or transmitted, in any form or by any means, without the prior permission of the Editor.

The Journal and/or its publisher cannot be held responsible for errors or for any consequences arising from the use of the information contained in this journal.

The appearance of advertising or product information in the various sections in the journal does not constitute an endorsement or approval by the journal and/or its publisher of the quality or value of the said product or of claims made for it by its manufacturer.

The journal is published and distributed by Medknow Publications. Copies are sent to subscribers directly from the publisher's address. It is illegal to acquire copies from any other source. If a copy is received for personal use as a member of the association/society, one can not resale or give-away the copy for commercial or library use.

The Journal is printed on acid free paper.

Editorial Office

Dr. (Mrs) S. J. Nagda
Prof. & Head,
Dept. of Prosthodontics,
Nair Hospital Dental College,
Mumbai - 400 008, India.
E-mail: jipseditor@yahoo.co.in

Published by

Medknow Publications,
A-109, Kanara Business Centre,
Off Link Road, Ghatkopar (E),
Mumbai - 400075, India.
Tel: 91-22-6649 1818/1816,
E-mail: publishing@medknow.com
Website: www.medknow.com

Websites

www.jprosthodont.com
www.journalonweb.com/jips

The Journal of Indian Prosthodontic Society

Official Publication of Indian Prosthodontic Society

ISSN 0972-4052

Editor

Dr. (Mrs.) S. J. Nagda

Editorial Board

Dr. (Mrs) A. P. Wadkar

Dr. M. A. Gandhewar

Dr. (Mrs) Vrushali Abhyankar

Dr. Ravi Savadi

Dr. Shailendra Sahu

Advisory Board

Dr. Chandrasekhar Nair

Dr. E. G. R. Solomon

Dr. Hariprakash

Dr. Muniratnam Naidu

Dr. Mahesh Verma

Dr. Sridhar Shetty

Dr. Sreelal

Dr. Satish Babu

Indian Prosthodontic Society

(Registered under Public Trust Act No. 537/78, Public Trust F/551 5, Mumbai)

President

Dr. T. V. Padmanabhan

Immediate Past President

Lt. Gen. Paramjit Singh

Hon. General Secretary

Dr. V. Rangarajan

Editor

Dr. (Mrs.) Suhasini J. Nagda

Executive Council Members

Dr. F. D. Mirza

Dr. E. G. R. Solomon

Air Cmde S. Murali Mohan

Dr. U. V. Gandhi

Dr. Ravi C. Savadi

Dr. M. Shiva Shankar

Dr. Soorya Poduval

Dr. Himanshu Aeran

Dr. Saranjit Singh Bhasin

Dr. K. Mahendranadh Reddy

Dr. Supriya Nerli

Brig. Vimal Arora

Dr. Shilpa Shetty

Dr. S. K. Khindria

Dr. K. R. Nagaraj

Dr. V. Anand Kumar

IPS Office

Dr. V. Rangarajan

Hon. Gen. Secretary cum Treasurer, 230, Avvai Shanmugham Salai,
Royapettah, Chennai - 600014, India. E-mail: drvrange@gmail.com

The Journal of Indian Prosthodontic Society

July-September 2007 - Vol 7 - Issue 3

CONTENTS

Editorial

The three magic L's

S. J. Nagda 117

Original Articles

The curvature of the retentive arm in a circumferential clasp and its effect on the retention:
3D analysis using finite element method

Allahyar Geramy, Masoud Ejlali 118

Biometric relationship between intercanthal dimension and the widths of maxillary anterior teeth

Ulhas E. Tandale, Shankar P. Dange, Arun N. Khalikar 123

Role of prosthodontist with regard to impacted esophageal dentures from an ENT perspective

Abhishek Jaswal, Avik K. Jana, Atish Haldar, Biswajit Sikder, Utpal Jana, Tapan K. Nandi 126

Evaluation of marginal microleakage of three zinc-oxide-based non-eugenol temporary
luting agents: An in vitro study

Subhash Bandgar, S. J. Nagda 132

Review Articles

Clinical tips in full veneer tooth preparation

Neelam Sharma, Vidya Chitre 137

Rotational path removable partial denture: A literature review

Marzieh Alikhasi, Abbas Monzavi, Farideh Gramipanah, Maryam Eghlima, Hakimeh Siadat 143

Nutrition in maxillofacial prosthetic patients: The unexplored frontier

Ravi Madan, Saumyendra V. Singh, Arvind Tripathi 147

Case Reports

Reconstruction of a cranial defect with an alloplastic implant

Sandeep Kumar, Seema Gupta, Nayana Prabhu 150

The removable occlusal overlay splint in the management of tooth wear

Bilquis J. Ghadiali, S. A. Gangadhar, Kamal Shigli 153

Customized cast post-and-core abutment for single tooth implants: An easy approach

S. K. Bhandari, T. Ravindranath, Shabina Sachdeva, Shraddha Gurlhosur, S. S. Bhasin 158

Guest Article

Marching ahead to the future

K. Chandrasekharan Nair 162

News and Views

..... 166

Book Review

..... 167

35th IPS Conference

..... 168

Role of prosthodontist with regard to impacted esophageal dentures from an ENT perspective

Abhishek Jaswal, Avik K. Jana, Atish Halder, Biswajit Sikder, Utpal Jana, Tapan K. Nandi

Department of Otolaryngology, Head and Neck Surgery, Calcutta National Medical College, Kolkatta, West Bengal, India

For Correspondence

Dr. Abhishek Jaswal, C/O Mr. Asoke Kumar Jana, Model Town, Garia, Balia, Kolkatta - 700 089, West Bengal, India.
E-mail: abhishekjaswal@rediffmail.com

AIMS: The study tries to elucidate the contributing factors responsible for cases of denture impaction with regard to the events preceding the impaction, types of denture responsible for impaction, duration of the use of denture, age and sex distribution, presenting signs, symptoms, diagnosis and complications with an idea of providing an ENT perspective of the problem, thereby underlining the need for preventive measures and doctor/patient education. Based on the results, a few suggestions are made to serve these purposes. **SETTINGS:** A tertiary hospital of a developing country. **STUDY DESIGN:** A retrospective chart review. **MATERIALS AND METHODS:** A retrospective analysis of 106 cases of denture impaction presenting to the Otorhinolaryngology Department over a period of 5 years (September 2000 to September 2005). **STATISTICAL ANALYSIS USED:** The statistical package for social sciences (SPSS) 10.0 windows compatible program. **RESULTS AND CONCLUSION:** Denture impaction was most prevalent in elderly persons (>50 years) using dentures for more than 5 years. The upper single tooth and double teeth nonhooked acrylic dentures were the most common types of denture responsible for impaction. The most common preceding event was the wrong manner of drinking water. The most common location of impaction was in lower one-third of the esophagus with rigid esophagoscopy being a fairly safe technique for management. The rate of complications was directly proportional to the duration of presentation. The current modalities of the localization of impacted denture were largely ineffective or high costs were involved for the routine use of radio-opaque materials and the alternative coloring of the denture. Hence, education of the doctor and patient regarding the availability of such materials and proper use of dentures should be given paramount importance.

Key words: Esophageal, impacted dentures, prevention

INTRODUCTION

With an increasing incidence of tooth loss due to caries and periodontal diseases, there is an increase in the number of people wearing dentures, thereby resulting in the proportionate increase in the incidence of impacted dentures in the upper gastrointestinal tract.^[1] The condition is further aggravated by the ignorance on the part of the patient and non adherence to the instructions regarding the mechanics of use, life span, maintenance of dentures and to honor the recall visits to the dentists in order to assess the requirement for the change of dentures. The treating physician is often a culprit who contributes to the situation because a clear prescription regarding the material to be used for the preparation of denture and precautions to be followed subsequently is often lacking. This study attempts to explain these issues and to provide an ENT perspective to the problem of

denture impaction based on the retrospective analysis of 106 cases of denture impaction during a period of 5 years. The aim is to reduce the discrepancies between the allied practices of dentistry and ENT by providing a much needed feedback with regard to the issues of denture impaction, which was lacking from previous studies.

MATERIALS AND METHODS

The study was conducted in a tertiary referral hospital in eastern India. It comprises the retrospective analysis of 106 cases of denture impaction presenting to the Department of Otorhinolaryngology over a period of 5 years (Sept. 2000 to Sept. 2005).

Data collection entailed the sorting out of all the cases of denture impaction from the operating theater register. The case files were retrieved and information regarding age, sex, presenting complaints, preceding event and

duration of denture use was noted. Further, the types of denture (upper/lower/hooked/unhooked), modes of removal of denture and subsequent complications were noted.

All the patients who were managed electively were subjected to common battery of tests, including the routine blood tests, soft tissue X-ray in the anterior-posterior neck regions and lateral view, chest X-ray and chest X-ray with light barium swallow; very few patients required computerized tomography (CT) scan for localization.

Cases were divided into two broad groups on the basis of impaction with hooked (*i.e.*, those with metallic hooks and pointed wire components) and nonhooked dentures (*i.e.*, acrylic dentures without any metallic components). The dentures responsible for impaction were further divided on the basis of number of teeth present. The dentures implicated in impactions were further categorized on the basis of site of use, *i.e.*, upper vs lower denture.

Moreover, the age and sex distributions, duration of use of the denture and contributing factors responsible for the condition of denture impaction with regard to the events preceding the impaction were noted. Further assessment was done with regard to the signs and symptoms presented and the resulting diagnosis and complications.

The statistical package for social sciences (SPSS) 10.0 windows compatible program was used for statistical analysis. During the evaluation of the data from the study, bivariate analysis was performed and odds ratio for the respective preoperative and preoperative variables along with its 95% confidence interval was calculated. The results were evaluated with respect to the 95% confidence level and significance levels of $P < 0.05$.

RESULTS

This study comprises 106 cases of dentures managed in the Otolaryngology Department of a developing country. The non hooked dentures outnumbered the hooked dentures with a ratio of 1.7: 1 (hooked = 39, non hooked = 67) [Table 1].

The mean age of the patients was 56.2 years. The age group most prone to denture impaction was those between 50 and 60 years. Patients with more than 50 years of age constituted 81.13% of the cases. None of the cases were below 30 years of age [Table 1]. Male patients outnumbered the female patients with a ratio of 2.7: 1.

The common symptoms at the time of presentation were odynophagia (100%) and foreign body sensation (65.09%) with a rare presentation of stridor (2.83%). One of the common signs observed was the pooling of saliva (81.13%) [Figure 1].

When the dentures responsible for impaction were further divided on the basis of number of teeth present, those with single tooth and double teeth outnumbered the larger dentures (29.24% and 41.50% respectively) with the acrylic non hooked dentures outnumbering the hooked dentures in both the categories [Table 2]. Larger dentures were more commonly found with metallic hooks in comparison to smaller dentures, which were generally made of acrylic.

The upper dentures outnumbered the lower dentures by a ratio of 2.15: 1. The z test for a single sample with continuing correction came out to be 3.78 with the resulting P value to be less than 0.01, thereby making this observation highly significant [Table 3].

The duration of the use of dentures revealed that most of the patients wore the dentures for more than 5 years (46.22%). Those patients wearing the dentures for less than 1 year were the next group (21.69%). The chi-square test for checking the trends was carried for checking the chances of denture impaction with the duration of use. Subsequently, the calculated P value was 0.000...(1.92×10^{-8}), which was highly

Table 1: Number of cases of denture impaction between September 2000 and September 2005

Age (years)	Hooked	Nonhooked
30-40	1	1
40-50	8	10
50-60	15	28
60-70	11	19
>70	4	9
Total = 106	39	67

Table 2: Types of dentures divided on basis of number of teeth present

	Single tooth	Double teeth	Three teeth	Four teeth
Hooked	2	17	14	6
Nonhooked	29	27	11	0
%	29.24	41.50	23.58	5.66

Table 3: Types of dentures on basis of the site of use

Type of denture	Upper denture	Lower denture	Z (Continuing correction) and P value
No. of patients	73	33	$Z = 3.78$ $P < 0.01$
%	68.86	31.13	

Table 4: Duration of denture usage

Duration of denture use (year)	No. of patients	%	Chi-square for trends and P values
<1	23	21.69	38.79 $P = 0.000... (1.92 \times 10^{-8})$
1-2	8	7.54	
2-3	3	2.83	
3-4	6	5.66	
4-5	17	16.03	
>5	49	46.22	

significant [Table 4].

The events preceding the impaction revealed that the most common event preceding the impaction was wrong manner of drinking water or taking medicines (78.30%) [Figure 2].

Most of the patient presented within the first 24 h of denture impaction (58.49%). This was closely followed by those presented after 48 h (28.30%). In 2.83% cases presented after the first week of impaction, the most common site of impaction of denture was in lower one-third of the esophagus (34.90%) followed closely by the next common site that is the middle one-third of the esophagus (32.07%) [Figures 3, 4].

Investigations for the removal of dentures were performed via commonly rigid esophagoscopy (58.49%) and hypopharyngoscopy (27.35%). Spontaneous expulsion of denture through bowel was noted in 11.32% cases whereas 2.83% cases required thoracotomy for the removal of denture for which they were referred to the department of cardiothoracic surgery [Figure 5].

The complications of interventions for denture removal were mediastinitis (3.77%), pneumothorax (0.94%) and neck abscess (0.94%). Other complications including recurrent laryngeal nerve palsy were noted in 2.83% cases.

DISCUSSION

Replacing the missing teeth not only improves the facial esthetics but also makes eating a more pleasant experience and enhances the clarity of speech. It also prevents malocclusion and tilting of the adjacent teeth and collection of food in the edentulous spaces.^[1] With the coincident increase in the number of people wearing dentures in the past 25 years, an increase was also observed in the incidence of impacted dentures in the esophagus. The incidence of impacted dentures ranges between 3.6-27.7% of all the foreign bodies impaction - the number being considerably higher in adults than in children.^[2] The occurrence of denture impaction among all upper digestive tract foreign body, in our study was 4.78% per year.

It has been noted that edentulous patients are unable to masticate properly and coupled with the absent

sensation of the teeth, they are more prone to ingest a foreign body. This problem is amplified by aging as evident by the age profile of the patients in this study, in which 81.13% cases were above 50 years of age [Table 1] with a mean age of presentation of 56.2 years. This is opposed to the pervious studies where no significant association was observed between aging and the incidence of denture impaction.^[2-4] Male patients outnumbered the female patients by a ratio of 3: 1,

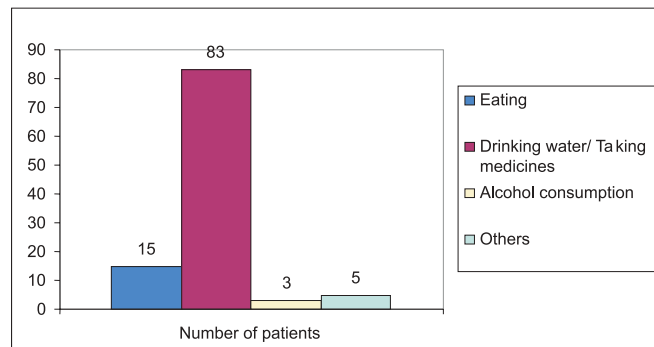


Figure 2: Events preceding denture impaction

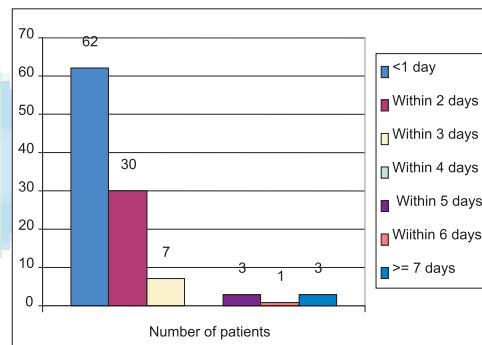


Figure 3: Time of presentation

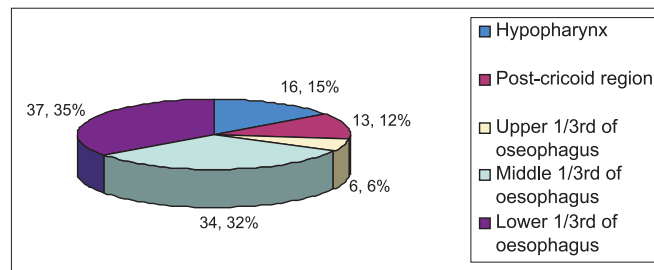


Figure 4: Level of impaction

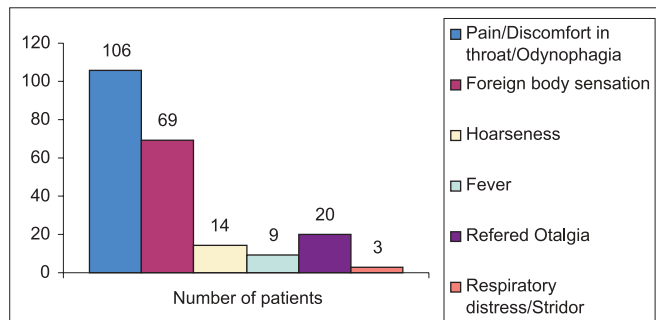


Figure 1: Symptoms on presentation

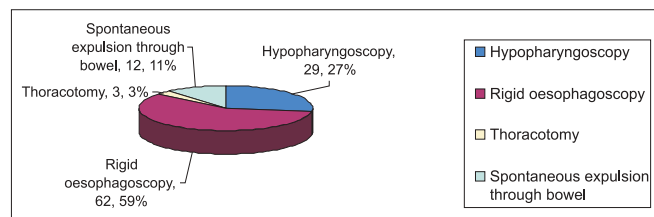


Figure 5: Procedure used for denture removal

which is similar to the earlier reported ratio of 2.7: 1,^[2,3] possibly indicating that females take more care of their denture appliances in comparison to males.

Symptoms at the time of presentation varied from the usual symptoms of odynophagia (100%) and foreign body sensation (65.09%) to unusual symptoms of hoarseness of voice (13.20%) and respiratory distress (2.83%). The latter can be explained on the basis of the large denture occluding the hypopharynx and laryngeal opening and denture impacting in postcricoid region with compression and the edema of the respiratory tract. About 8.49% cases of late presentation also presented with fever. The signs at the time of presentation included pooling of saliva (81.13%) and neck tenderness (43.39%) [Figure 1].

Prolonged use of dentures, which in most cases is made of acrylic material, are not as retentive and rugged as those with metallic framework and hence the dentures cannot readily withstand forces generated during daily use. These dentures become loose on regular use over a duration of 4-5 years and require replacement.^[1,3] In this study, the acrylic partial denture outnumbered the traditional metallic hooked dentures by a ratio of 1.7: 1 [Table 2].

The events preceding the impaction of denture revealed that most common event was the manner of drinking water, particularly while taking medicines (78.3%). Drinking water directly from the glass that is in contact with lips did not cause the damage, but it was the indirect method of drinking water in which the water was poured from an elevated position without keeping the glass in contact with the lips [Figure 2]. As expected, it was the rates of impaction of upper dentures that outnumbered the rates of the lower denture impaction (2.15: 1). The difference between the rates of impaction and dislodgement of upper dentures were found to be significant in comparison to those of the lower dentures ($P < 0.01$) on carrying out a single sample analysis [Table 3]. This method of drinking water is quite prevalent in the Indian subcontinent.

The problem of a misfit denture is further amplified by the fact that after loss of teeth, the alveolus and residual ridges continue to resorb as the person ages, resulting in the further loosening of denture that requires adjustment. The fact is strengthened by the results of this study in which most of the patients (46.22%) were using the dentures for more than 5 years. Another subset of patient that formed major portion of cases of denture impaction were the new users with the duration of use less than 1 year (21.69%), possibly because they are not accustomed to the proper use of dentures. When the chi-square test for checking the trend was carried for the chances of denture impaction with the duration of use, the results obtained were highly significant ($P = 0.000...$)

indicating that significant association exists between the chances of impaction and duration of use of denture that increases drastically if the dentures are used for more than 5 years [Table 4]

The level of impaction and ease of extraction of the denture depends upon the size and configuration of the denture and presence or absence of wire hooks. Dentures with single or double tooth are easy to extract but are lodged in lower esophagus in opposition to the larger dentures with three or more teeth. Considering the wire clasps and collets (sharp edges) of a denture, which enhance its arrest when ingested, it is not surprising that impactions in the lower esophagus are rare.^[2,4] The majority of the cases in our study were smaller dentures (70.75%) whereas there were only 29.24% cases for larger dentures. As expected, the common level of impaction was in the lower two-third of the esophagus (66.98%). The next common site of impaction was the hypopharynx and postcricoid region (27.35%); this is in agreement with the proportion of large dentures (29.24%), which are more prone to impaction in upper part of digestive tract [Figure 4].

Most of the cases of impaction were managed by rigid esophagoscopy (58.49%) whereas 27.35% cases were managed by hypopharyngoscopy. This is in agreement with the common location of impaction and types of denture impacted.^[2,3] Very few cases of large hooked impacted dentures required thoracotomy (2.83%). Extraction with rigid esophagoscopy was hampered in two cases that required thoracotomy due to late presentation where excessive edema around the denture precluded safe extraction. Spontaneous expulsion via bowel was noted in as many as 11.32% cases. In six of these cases, due to difficulty in extracting the denture proximally, the dentures were pushed into the stomach, which lead to spontaneous expulsion over a period of 36 h to 5 days [Figure 5]

The chances for complications following the extraction of denture depend upon the size, rigidity, sharp edges of the dentures and presence of hooks. In addition to these, the degree of inflammation at the site of impaction also increases the risk of complications. Complications are more likely if the presentation or intervention is delayed with the rate of complications rising from 3.2% after 24 h to 23.5% after 48 h [Figure 3].^[3,4] In this study, the rate of complication was 7.54% with serious complications such as mediastinitis secondary to perforation observed in only 3.77% cases, which is in agreement with the major series. All the cases of mediastinitis could be managed by conservative therapy with antibiotics and steroids could be used in few cases and none of the cases required thoracotomy for such a complication.

The low rate of complications in our study can be attributed to the early presentation as 86.79% cases

presented within first 48 h of impaction in opposition to 13.20% cases that presented late.

The most important issue concerning the management of impacted dentures in upper digestive tract is the inability to localize the dentures preoperatively and during the time of intervention. The role of radiography in preoperative localization is controversial as most of dentures were radiolucent.^[5,6] Alternative methods of identification and localization include computerized CT scanning and barium swallows for objects impacted in the esophagus; however, the high cost of CT scan and the almost universal symptom of odynophagia at presentation renders these modalities to be more of theoretical significance in our scenario.^[7] In this study, the localization of impacted dentures was performed using conventional radiology, which was ineffective in most cases and more often this was conducted for the sake of medicolegal causes than for true localization. The signs such as air entrapment and increased prevertebral soft tissue thickness, whenever present, were helpful aids in diagnosis. In cases of radiolucent dentures (acrylic, non hooked), the chest X-ray taken using a light barium meal was a quite helpful investigation in cases where it was feasible. Only one case required CT scan to localize and assess the associated complications.

The use of a radio-opaque acrylic has been recommended extensively in the literature over a considerable period of time for use in dental appliances to aid the detection of acrylic fragments as they are usually radiolucent, which makes it difficult to locate them with plane radiography. Attempts have been made to produce radio-opaque acrylic for denture construction. These include incorporation of radio-opaque bodies (lead foil, amalgam), the salts of heavy metals (barium fluoride, barium sulfate, bismuth glass and barium acrylate) and the production of copolymers in which one of the copolymer contains a heavy atom.^[8-10] Unfortunately, the incorporation of these materials into acrylic has adversely affected the properties of the acrylic from the esthetics to the finish that can be achieved. A material called opex and incorporation of a radio-opaque polymer of methyl methacrylate containing bromine into the denture base materials has been reported to yield good radio-opacity while retaining good mechanical properties.^[9] Recently, glitter-containing acrylics have become available that renders the acrylic to become radio-opaque on plain radiograph.^[9,10]

Although recommendations for the use of radio-opaque acrylic in dentistry are present since 1981, the materials are still not used on regular basis mainly due to lack of interest and support from the prescribing physician and cost of newer materials. However, with regular prescription and interest, the costs are bound

to decrease in the near future.^[9]

The use of colored acrylics, rather than pink, for the construction of removable appliances is a viable alternative to assist the per-operative visualization of the dentures on esophagoscopy. Although the use of alternative colors, other than pink or clear, are expected to hamper the esthetic appearance of the dentures, the use of colors in selected part of dentures is all that is required. From our experience, we have observed that most of the dentures are located along the curvature of esophagus exposing their concave inner surface. The selective coloring of this concave inner surface maintaining the outer convex surface as pink will resolve most of the concerns regarding the esthetic value of the denture.

Other suggestion regarding the preparation of dentures can be attempts to make all the components of the removable appliances smooth and rounded as far as possible. All cribs and springs should not have sharp ends and finger springs and stops should be rounded.^[8] Hooked or "C" clasps should be avoided if possible or alternative retentive components should be used. Patients should always be advised both verbally and with written instructions that they should not try to reinsert damaged, ill-fitting or broken fragments of any appliance. They should stop using them and contact the office or practice of an prosthodontist to have the appliance checked.^[9,10] Further instructions should include the requirement to undergo regular follow-up for the checking of dentures and to replace the dentures if they become loose. Patient should be told to follow the right method of drinking water using visual aids and to seek immediate medical advice in cases the denture is dislodged and impacted.


CONCLUSION

Denture impaction was most prevalent in elderly persons (>50 years) who were using dentures for more than 5 years. Upper single and double teeth non hooked acrylic dentures were most commonly responsible. The most common preceding event was wrong manner of drinking water. The most common location of impaction was in lower one third of the esophagus with rigid esophagoscopy being a fairly safe technique for management. The rate of complications was directly proportional to the duration of presentation. The current modalities of localization of impacted denture were largely ineffective or involved high costs for the routine use of radio-opaque material and alternative coloring of the dentures. Hence, doctor and patient education regarding the availability of such material and proper use of denture should be given paramount importance.

REFERENCES

1. Richardson ME. The layman's view of orthodontics: A literature review. *Br Dent J* 1998;185:324-7.
2. Tamura N, Nakajima T, Matsumoto S, Ohyama T, Ohashi Y. Foreign bodies of dental origin in the air and food passages. *Int J Oral Maxillofac Surg* 1986;15:739-51.
3. Lavine MH, Stoopack JC. An esophageal foreign body of dental origin. *J Am Dent Assoc* 1968;76:1038-40.
4. Okoisor FE. Tooth mortality: A clinical study of loss. *Niger Med J* 1977;7:77-81.
5. Absi EG, Buckley JG. The location and tracking of swallowed dental appliances: The role of radiology. *Dentomaxillofac Radiol* 1995;24:139-42.
6. Haglund S, Haverling M, Kuylensstierna R, Lind MG. Radiographic diagnosis of foreign bodies in the esophagus. *J Laryngol Otol* 1978;92:1117-25.
7. Webb WA, McDaniel L, Jones L. Foreign bodies of the upper gastrointestinal tract: Current management. *South Med J* 1984;77:1083-6.
8. McCabe JF, Wilson HJ. A radio-opaque denture material. *J Dent* 1976;4:211-7.
9. The desirability of using radiopaque plastics in dentistry: A status report. Council on Dental Materials, Instruments, and Equipment. *J Am Dent Assoc* 1981;102:347-9.
10. Chandler HH, Bowen RL, Paffenbarger GC. The need for radiopaque denture base materials: A review of the literature. *J Biomed Mat* 1997;15:245-52.

Source of Support: Nil, Conflict of Interest: None declared.



Author Help: Reference checking facility

The manuscript system (www.journalonweb.com) allows the authors to check and verify the accuracy and style of references. The tool checks the references with PubMed as per a predefined style. Authors are encouraged to use this facility before submitting articles to the journal.

- The style as well as bibliographic elements should be 100% accurate to get the references verified from the system. A single spelling error or addition of issue number / month of publication will lead to error to verifying the reference.
- Example of a correct style
Sheahan P, O'leary G, Lee G, Fitzgibbon J. Cystic cervical metastases: Incidence and diagnosis using fine needle aspiration biopsy. *Otolaryngol Head Neck Surg* 2002;127:294-8.
- Only the references from journals indexed in PubMed would be checked.
- Enter each reference in new line, without a serial number.
- Add up to a maximum 15 reference at time.
- If the reference is correct for its bibliographic elements and punctuations, it will be shown as CORRECT and a link to the correct article in PubMed will be given.
- If any of the bibliographic elements are missing, incorrect or extra (such as issue number), it will be shown as INCORRECT and link to possible articles in PubMed will be given.