

Clinical Report

Prosthetic rehabilitation of a patient with an orbital defect using a simplified approach

Manvi Supriya, Bilquis Ghadiali

Department of Prosthodontics, KLES's Institute of Dental Sciences, Belgaum, Karnataka, India

For correspondence

Dr. Supriya Manvi, B-1 Staff Quarters, J.N.M.C Campus, Nehru Nagar, Belgaum - 590 010, Karnataka, India.

E-mail: supriyamanvi@rediffmail.com

The rehabilitation of facial defects is a complex task requiring a specific design of the technique to be used in individual patient. The disfigurement associated with the loss of an eye can cause significant physical and emotional problems. Various treatment modalities are available, one of which is implants. Although implant orbital prosthesis has a superior outcome, it may not be advisable in all patients due to economic factors. The present article describes a simplified technique for the fabrication of a silicone orbital prosthesis by modifying a stock ocular prosthesis to achieve ideal fit and esthetics. Multidisciplinary management and team approach are essential in providing accurate and effective rehabilitation.

Key words: Orbital prosthesis, stock ocular prosthesis orbital defect

INTRODUCTION

The unfortunate absence or loss of an eye may be caused by a congenital defect, irreparable trauma, a painful blind eye, sympathetic ophthalmia or the need for histological confirmation of a suspected diagnosis.^[1]

The disfigurement associated with the loss of an eye can cause significant physical and emotional problems. Two surgical procedures are generally used; one is evisceration, which consists of the removal of the contents of the globe, leaving the sclera and on occasions the cornea in place and the other procedure, enucleation where the eyeball is completely removed.^[2]

The earliest known examples of restorations date to the fourth dynasty in Egypt; excavations of tombs have provided evidence of eye replacement by using precious stones, earthenware, copper, gold, enamelled bronze in the shrunken socket. Pare^[3] also used glass and porcelain for eyes, which was a great step forward. Methyl methacrylate prosthesis became popular since they offered superior strength and the shape and size could be modified. Flexible material such as silicone became advantageous when the defect extends beyond the orbital area and encounters movable tissue beds.

The replacement of the lost eye as soon as possible after healing from eye removal is necessary to promote physical and psychological healing for the patient and to improve social acceptance. Multidisciplinary management and team approach are essential in

providing accurate and effective rehabilitation and follow-up care for the patient.^[1]

This article describes a simplified method for the fabrication of a silicone orbital prosthesis.

CASE REPORT

A 35-year-old man reported to the Department of Maxillofacial Prosthodontics, K.L.E.S's Institute of Dental Sciences, Belgaum, with a missing right eye.

The patient gave a history of enucleation of the eye due to accidental exposure to nitric acid. On examination, a bare, fibrosed ocular socket covered by grafted skin was observed [Figure 1]. Moreover, the patient did not report of any pain or discomfort in the periorbital tissue.

Following complete enucleation, a treatment plan, comprising fabrication of a custom silicone orbital prosthesis was formulated.

Technique

1. A facial impression was prepared from irreversible hydrocolloid (Tropicalgin; Zhermach Inc. products, California) along with reinforcement by dental plaster [Figure 2]. Subsequently, a cast was poured in the dental stone (Goldstone; Asian chemicals, Rajkot, Gujarat, India).
2. A suitable stock ocular prosthesis was selected that closely approximates the color, size and shape of the iris and sclera of the other eye. The stock ocular prosthesis was placed on the cast and the

periphery was arbitrarily trimmed to match the socket border extensions on the cast.

3. Next, the ocular prosthesis was positioned to simulate the positioning of the left eye, with the patient focusing on the distant point directly ahead. A reference mark was placed at the midline and a

Boyles gauge was used to verify the mediolateral placement. The pupils were used as reference points for evaluation. Accurate mediolateral, anteroposterior and inferosuperior positioning of the prosthesis was performed to exactly mimic the position of the normal eye.

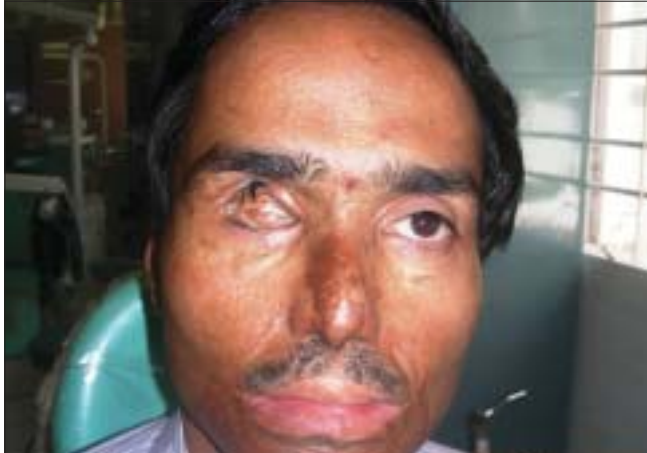

Figure 1: Preoperative view



Figure 4: Postoperative view

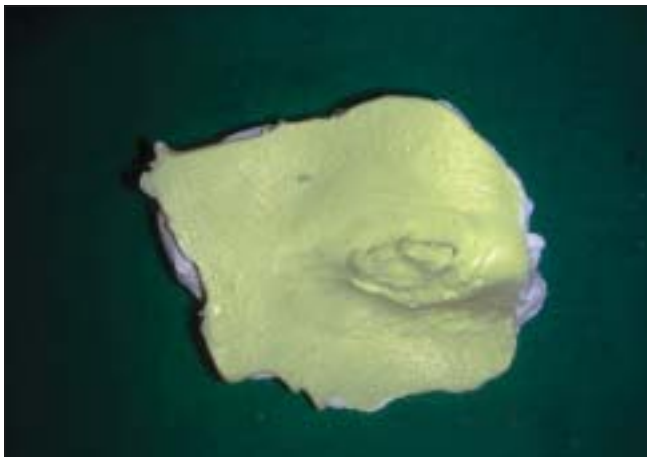


Figure 2: Impression of the defect

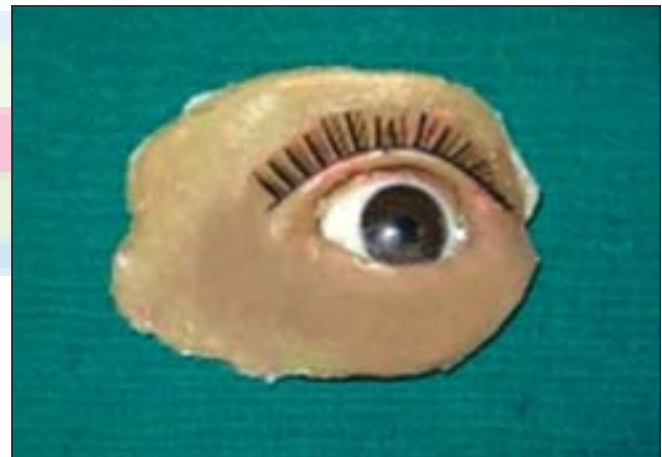

Figure 5: Finished orbital prosthesis

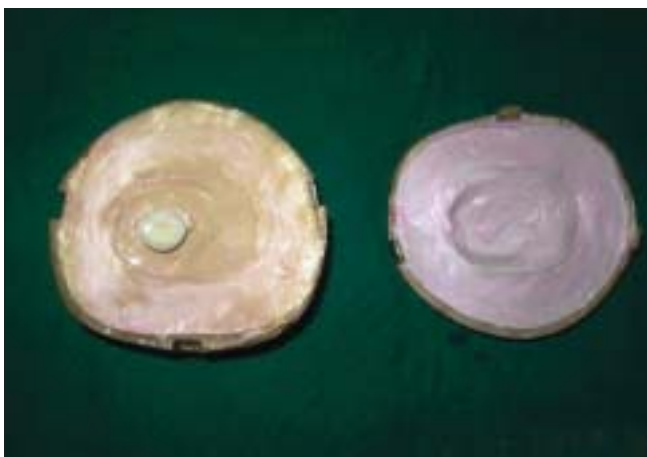


Figure 3: Positioning of the ocular prosthesis in the mold space

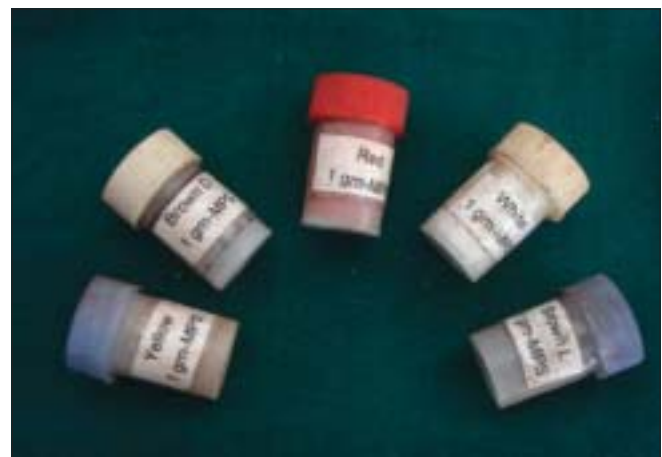

Figure 6: Intrinsic colors used

4. Some amount of baseplate wax (Hindustan Modelling Wax No. 2; The Hindustan Dental Products, Hyderabad, Andhra Pradesh, India) was then added on the tissue side of the prosthesis in order to orient the prosthesis to the desired visual axis.
5. A thin, even layer of tissue conditioner (Soft liner; GC Corporation, Tokyo, Japan) was then applied on the tissue surface of the prosthesis and placed back into the socket. The prosthesis was left in situ for 20 min during which the patient was asked to perform various functional movements.
6. The modified prosthesis was then invested [Figure 3] and packed with tooth-colored heat-cure acrylic resin (Stellon De Trey; Dental Products of India Ltd., Mumbai, India). Slow curing was carried out for acrylisation at 74°C (165°F) for 8 h.
7. After curing, the ocular prosthesis was recovered and highly polished. At the next appointment, the modified stock ocular prosthesis was inserted and evaluated again for patient comfort and esthetics.
8. The periorbital tissue was then sculpted. The lid contours and periorbital tissues were mimicked to those of the left eye as precisely as possible. The lines of the juncture were feathered, and they should not extend beyond the area covered by the eyeglass frame since such margins are difficult to camouflage.
9. The mold was then fabricated following investing and examined for any imperfections.
10. The shade was matched using natural daylight, the best time for which was between 11 am and 1 pm. The appropriate colors [Figure 4] were then obtained by mixing different intrinsic shades with the silicone material (M.P. Sai Enterprise), following which it was packed. It was left overnight to bench cure, and then placed in hot water for 1 h at 45°C.
11. The prosthesis was then retrieved, trimmed and the final finishing completed and adjusted according to the needs of the patient. Prosthetic eyelashes were then attached to the upper lid [Figure 5]. Since the lower eyelashes are quite scanty, their presence was simulated with a few vertical lines of extrinsic painting on the lower lid.
12. The retention was achieved with the help of a skin adhesive and by engaging the orbital undercut with a flexible material. Additional retention was provided by means of eyeglass frame attached to the prosthesis [Figure 6].

DISCUSSION

The importance of an orbital prosthesis with acceptable esthetics and reasonable motility in restoring the normal appearance in patients with anophthalmia has been

recognized since long.^[1] The need for an artificial eye can sometimes be satisfied by stock ocular prosthesis that come in standard sizes, shapes and colors. These are relatively inexpensive and can be delivered quickly. Often, however, a custom-made ocular prosthesis is indicated. Advantages include improved adaptation to the underlying tissues, increased mobility of the prosthesis, improved facial contours and enhanced esthetics gained from the control over the size of the iris and pupil and color of the iris and sclera. Nevertheless, a custom-made prosthesis is more expensive than a stock prosthesis and several steps are required for its fabrication.^[4] Therefore, a modified stock ocular prosthesis is an excellent alternative, which is relatively inexpensive and easy to fabricate.

An accurate alignment of the artificial eye is one of the major prerequisites for esthetic success of the orbital prosthesis. Facial measurements^[5,6] and various devices have been proposed for orienting the ocular portion of the orbital prosthesis.

The rehabilitation of the orbital defect is a complex task and if reconstruction by plastic surgery is not possible or not desired by the patient, the defect can be rehabilitated by an orbital prosthesis. The retention of the orbital prosthesis can be achieved using adhesives, attachments to eyeglasses or engaging hard or soft tissue undercuts.^[6]

The use of osseointegrated implants is a popular approach since it offers an improved retention compared to the existing alternatives. Various factors, including systemic conditions and financial constraints, limit the use of osseointegrated implants in few patients.

This article describes the rehabilitation of an orbital defect using a silicone prosthesis, wherein retention has been achieved by a combination of anatomic undercuts, adhesives and eyeglasses.

REFERENCES

1. Artopoulos I, Montgomery P, Wesly P, Lemon J. Digital imaging in the fabrication of ocular prosthesis. *J Prosthet Dent* 2006;95:327-30.
2. Taylor T. *Clinical maxillofacial prosthetics*. Quintessence Publishing Co, Inc: 2000. p. 233-76.
3. Gibson T. The prosthesis of ambrose pare. *Br J Plast Surg* 1955;8:3-8.
4. Mathews MF, Smith RM, Sutton AJ, Hudson R. The ocular impression: A review of the literature and presentation of an alternate technique. *J Prosthodont* 2000;9:210-6.
5. Chalian VA, Drane JB, Standish SM. *Maxillofacial prosthetics: Multidisciplinary practice*. Williams and Wilkins: Baltimore; 1971. p. 294-304.
6. Beumer J, Curtis TA, Firtill DN. *Maxillofacial rehabilitation: Prosthodontic and surgical considerations*. CV Mosby: St Louis; 1979. p. 364-71.

Source of Support: Nil, Conflict of Interest: None declared.