

# Functional and esthetic rehabilitation of severely worn dentition with an end-to-end relationship

**Puneet Bhardwaj, Meena Aras**

Department of Prosthodontics, Goa Dental College, Bambolim - 403 202, Goa, India

### For correspondence

Dr. Puneet Bhardwaj, Goa Dental College, Bambolim - 403 202, Goa, India. E-mail: drpuneetbhardwaj@yahoo.co.in

Full-mouth fixed rehabilitation is one of the greatest challenges in prosthodontics. Apprehensions involved in the reconstruction of debilitated dentitions are heightened by widely divergent views concerning the appropriate procedures for a successful treatment. This clinical report describes the prosthodontic rehabilitation of a patient with severely worn dentition resulting in an end-to-end relationship. Maxillary and mandibular fixed restorations and cast partial denture were constructed for the therapy. Canine-protected occlusion was developed in the definitive restorations to decrease lateral forces on the posterior dentition. Protrusive guidance was developed to distribute the protrusive forces to the maxillary and mandibular incisors.

**Key words:** Anterior guidance, interocclusal splint, rehabilitation, worn dentition

## INTRODUCTION

Badly worn teeth that have drifted into an end-to-end relationship present a real restorative challenge. It is difficult to lengthen the appearance of the upper teeth without opening the bite or severely steepening the anterior guidance. This usually calls for a compromise that permits the lower incisal edges to move forward on a fairly flat guidance and then progress gradually to a steeper incline through a concave pathway.<sup>[2-6]</sup>

To make the concave contour possible, it is usually necessary to restore the worn lower teeth with full coverage, to narrow the broad incisal edges from the labial and to position the incisal edge lingually. By moving the incisal edges lingually, the lower incisors can be lengthened to provide an overjet; the upper incisors can then curve down from the cingulum-centric spot, providing more length for the upper anterior teeth. Such a procedure enhances both esthetics and function.<sup>[1,7]</sup>

Excessive occlusal wear may manifest itself in a reduction of the vertical dimension of occlusion. Restored occlusal vertical dimension is based on the concept that by providing the patient with an interocclusal splint designed to restore the previously lost occlusal vertical dimension, all abnormal muscle activities will be eliminated or reduced.<sup>[1,7]</sup>

This case report documents the treatment of destructive occlusal wear that results in an end-to-end relationship.

## CLINICAL REPORT

The patient, a 65-year-old man, presented with a chief complaint of severely worn teeth and inability to chew food, at the Department of Prosthetic Dentistry, Government Dental College and Hospital, Goa (India).

A review of the patient's medical history revealed that he had undergone angioplasty 4 years ago and was under medication for the same.

Intraoral examination revealed that probing depths in both arches were between 2 and 3 mm with minimal bleeding; however, a generalized mild marginal gingivitis was present. No abnormal tooth mobility was noted. Oral hygiene was acceptable.

Centric occlusion did not coincide with maximum intercuspation. The patient presented with end-to-end bite. Generalized advanced erosion and attrition were noted on the incisal and occlusal surfaces of the teeth in both arches [Figure 1].

Radiographically, the trabecular bone pattern was generally normal with a finely woven pattern. Teeth 14, 15, 16, 25, 26, 36, 37, 45, 46 and 47 were missing. The crown-to-root ratios were unfavorable, all being at least 1:2.5.

### Treatment

The treatment plan was presented to the patient. The type of restorations, restorative materials, esthetic expectations, complications, limitations and oral

hygiene requirements were discussed. The patient appeared to understand and provided his consent. Two sets of diagnostic casts were prepared using irreversible hydrocolloid (Jeltrate alginate; Dentsply, York, PA) and Type IV high-strength dental stone (Prima-Rock; Whip Mix Corp., Louisville, KY). A centric relation record was prepared. A Rotofix facebow was used to record the relationship of the maxilla with a transverse horizontal axis. Two sets of diagnostic casts were mounted on the Artex semiadjustable articulator using the Rotofix facebow and a centric relation record [Figure 2]. Diagnostic wax patterns, developed to provide a mutually protected occlusion, were prepared on one set of diagnostic casts with the occlusal vertical dimension opened 3.0 mm at the central incisors [Figure 3]. The wax patterns were used to fabricate the tooth preparation guides and provisional restorations.

A maxillary occlusal splint was fabricated at an increased occlusal vertical dimension of 3.0 mm, using heat-processed acrylic resin. The occlusal splint was inserted and adjusted [Figure 4]. This splint provided a mutually protected occlusion. One week later, the patient reported no difficulties in adapting to the new position; he was recalled every 2 weeks for 2 months.

The teeth were prepared for metal-ceramic restorations in the maxilla and mandible. This allowed for provisional restoration of all teeth at an increased vertical dimension with a stable occlusion. Heat-cured acrylic resin provisional shells (DPI-Heat Cure Tooth Moulding Powder; Dental Product of India, Mumbai, India) were fabricated, relined intraorally and cemented with zinc oxide without eugenol interim cement (Templute; Prime Dental Products Pvt. Ltd., Mumbai, India).<sup>[8]</sup> They were adjusted to provide a mutually protected occlusion [Figure 5].

The patient functioned on the provisional restorations for 12 weeks to further assess the adaptation of the proposed vertical dimension for the final restorations.<sup>[10]</sup> Centric relation records were obtained by using pankey jig on the maxillary anterior teeth and bimanual manipulation to guide the mandible in the centric relation. A facebow transfer of the maxillary arch was recorded using the same three points of reference as in the initial facebow transfer at the diagnostic phase of the treatment. Irreversible hydrocolloid impressions were prepared from the provisional restorations to fabricate a custom anterior-guide table to aid in the fabrication of the final restorations. After 12 weeks of comfortable functioning in the provisional restorations, preparations were refined for definitive impressions. At the time of the impression, all soft tissues were healthy.

Maxillary and mandibular full arch impressions were

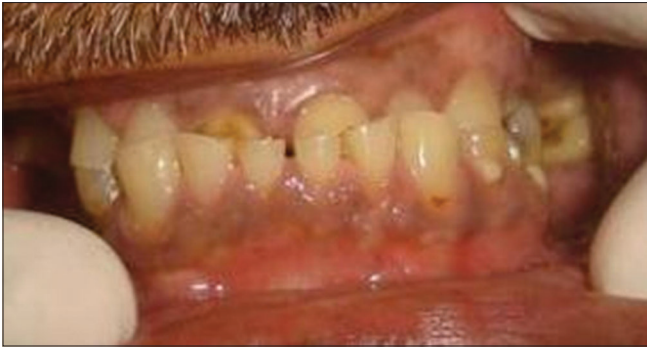prepared using vinyl polysiloxane impression material (Express, 3M ESPE; St. Paul, MN). Gingival retraction was obtained using plain braided cord moistened in aluminum chloride solution. Each impression was poured twice with type IV dental stone (Prima-Rock; Whip Mix Corp).

The metal frameworks were tried intraorally for adequate position and tightness of the proximal contacts, acceptable marginal adaptation, stability and internal adaptation.<sup>[10]</sup> The castings were returned to the laboratory for the application of porcelain. Bisque trials for verification of the fit, interproximal contacts and occlusion were accomplished [Figure 6]. A mutually protected occlusion was achieved and verified intraorally using articulating paper and 12- $\mu$ m thick shimstock. The intaglio surfaces of the restorations were microetched with 50- $\mu$ m aluminum oxide, cleaned and luted with resin-modified glass-ionomer cement (Rely X Luting; 3M ESPE). Periapical radiographs were taken as a baseline for future follow-up and to verify the complete removal of excess cement. Missing teeth were replaced by cast partial dentures with precision attachment on abutment teeth. Oral hygiene instructions included a review of brushing, flossing and the use of fluoride toothpaste. The patient returned 24 h after insertion for the final evaluation. Irreversible hydrocolloid impressions were prepared.

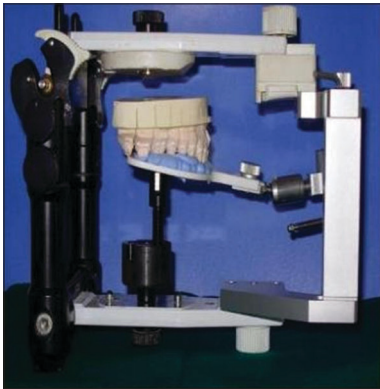
A heat-processed, clear acrylic resin maxillary occlusal splint providing a mutually protected occlusion was given to the patient to wear while sleeping and during the daytime as required. Instructions on the care of and when to wear the occlusal splint were given to the patient. The patient returned after 2 and 4 weeks for an occlusal analysis and for soft tissue evaluation [Figures 7-9]. He was placed on 6-month-periodic recall for prophylaxis. The prognosis was favorable. It was explained to the patient that the long-term prognosis of the restorations would depend on the maintenance of oral hygiene and the wearing of the occlusal splint for the protection of the restorations against parafunctional wear.

## DISCUSSION

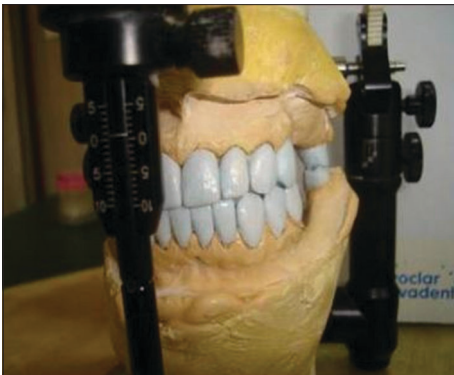Every patient has unique treatment requirements. Proper diagnosis and treatment plan are an important aspect of rehabilitation, but although the esthetics and function are improved by the above process, the envelope of function will remain restricted from its flattened pathways. It will usually be necessary to either splint the upper restoration or provide a nighttime retainer to prevent movements. The nighttime retainer can include a full occlusal coverage to reduce wear on the steepened anterior inclines.



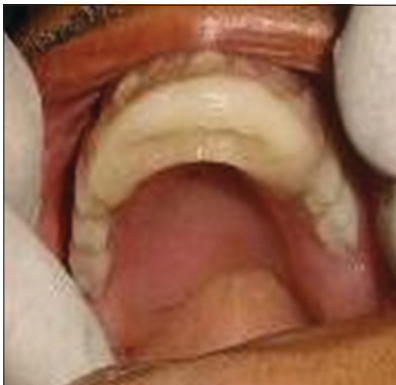**Figure 1:** Intraoral view of the patient, showing occlusion wear and edge to edge bite



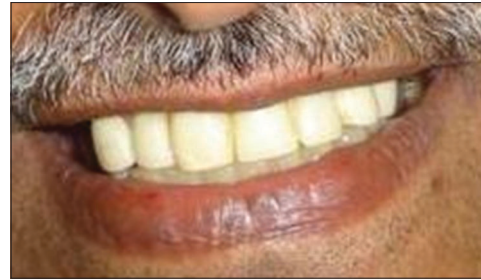**Figure 2:** Rotofix facebow transfer on an Artex semiadjustable articulator



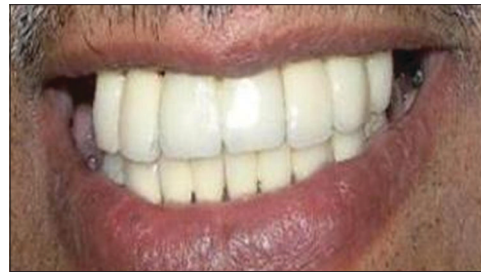**Figure 3:** Diagnostic wax up on the semiadjustable articulator



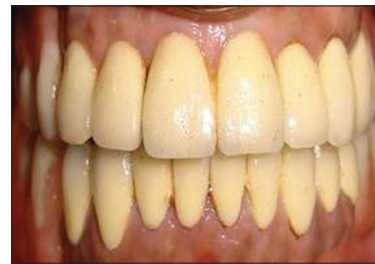**Figure 4:** Patient with interocclusal splint



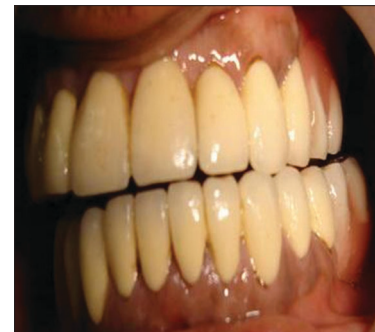**Figure 5:** Patient with provisional restoration



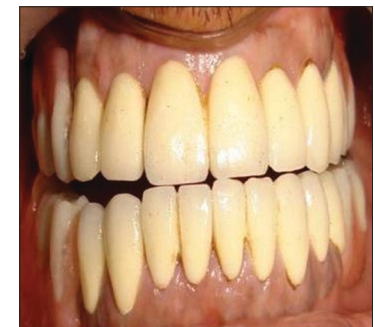**Figure 6:** Patient with a bisque trial



**Figure 7:** Patient with permanent restoration in centric occlusion



**Figure 8:** Canine-guided occlusion with disocclusion on both balancing and working side



**Figure 9:** Disocclusion with protrusion

## REFERENCES

1. Dawson PE. Evaluation, diagnosis and treatment of occlusal problems, 3<sup>rd</sup> ed. Mosby: St Louis; 2007. p. 441-3.
2. Schweitzer JM. An evaluation of 50 years of reconstructive dentistry, Part I: Jaw relations and occlusion. *J Prosthet Dent* 1981;45:383-8.
3. Schweitzer JM. An evaluation of 50 years of reconstructive dentistry, Part II: Effectiveness. *J Prosthet Dent* 1981;45: 492-8.
4. Goldman I. The goal of full mouth rehabilitation. *J Prosthet Dent* 1952;2:246-51.
5. Bronstein BR. Rationale and technique of biomechanical occlusal rehabilitation. *J Prosthet Dent* 1954;4:352-67.
6. Schweitzer JM. A conservative approach to oral rehabilitation. *J Prosthet Dent* 1961;11:119-23.
7. Abrahamsen TC. The worn dentition-pathognomonic patterns of abrasion and erosion. *Int Dent J* 2005;4: 268-76.
8. Naylor WP, Beatty MW. Materials and techniques in fixed prosthodontics. *Dent Clin North Am* 1992;36:665-92.
9. Padilla MT, Bailey JH. Margin configuration, die spacers, fitting of retainers/crowns and soldering. *Dent Clin North Am* 1992;36:743-64.
10. Rivera-Morales WC, Mohl ND. Restoration of the vertical dimension of occlusion in the severely worn dentition. *Dent Clin North Am* 1992;36:651-64.

**Source of Support:** Nil, **Conflict of Interest:** None declared.