

Clinical Report

Replacement of an upper central incisor with an implant supported crown: A case report to achieve acceptable esthetics for a malpositioned implant

Nur Hersek¹, Hasan Önder Gümüş², Ferda Taşar³, Mustafa Sayasel³

¹Department of Prosthodontics, Faculty of Dentistry, Hacettepe University, Ankara, ²Department of Prosthodontics, Faculty of Dentistry, Erciyes University, Kayseri, ³Department of Oral and Maxillofacial Surgery, Faculty of Dentistry, Hacettepe University, Ankara, Turkey,

For correspondence

Dr. Hasan Önder Gümüş, Department of Prosthodontics, Faculty of Dentistry, Erciyes University, Kayseri, Turkey
E-mail: hogumus@erciyes.edu.tr

Esthetics in implantology is a topic currently attracting a lot of attention from dental implantologists all over the world. It includes both white and red esthetics with much greater importance given to red esthetics. An ideal implant position in all 3 dimensions is required. These mesiodistal, apicocoronal, and orofacial dimensions are well described, defining "comfort" and "danger" zones for proper implant position in the anterior maxilla. Adequate bone base is usually a prerequisite for functionally and esthetically optimal reconstruction of the soft tissue architecture around a dental implant. When implants are malpositioned axially, prefabricated angled abutments or custom abutments may be used for restoration to acceptable function and comfort.

Key words: Custom made abutment, esthetics, malpositioned implant

DOI: 10.4103/0972-4052.49185

Esthetics in implantology is a topic currently attracting a lot of attention from dental implantologists all over the world. It includes both white and red esthetics with much greater importance given to red esthetics.^[1,2] An ideal implant position in all 3 dimensions is required.^[3,4] These mesiodistal, apicocoronal, and orofacial dimensions are well described, defining "comfort" and "danger" zones for proper implant position in the anterior maxilla.^[5]

An adequate bone base is usually a prerequisite for functionally and esthetically optimal reconstruction of the soft tissue architecture around a dental implant.^[6]

The standard parameters for achieving esthetic implant prosthesis result in one that is in harmony with the perioral facial structures of the patient. The esthetic peri-implant tissues, in their health, height, volume, color, and contours, must be in harmony with the healthy surrounding dentition. The restoration should imitate the natural appearance of the missing dental unit(s) in color, form, texture, size, and optical properties.^[7]

When implants are malpositioned axially, prefabricated angled abutments or custom abutments may be used for restoration to acceptable function and comfort.

CASE REPORT

A 21-year-old female patient's upper left central incisor had to be extracted because of apical lesion a few years ago. The patient was wearing a removable space holder [Figure 1]. Patient history, examination, and radiographic evaluation confirmed that the patient's missing maxillary left central incisor labial region had a bony defect. Using surgical techniques, the facial bone wall was augmented using bone substitutes to create an adequate ridge. After 5 months 3.8x11 implant fixture (Friadent-Xive Friadent GmbH Mannheim Germany) was inserted. As the bone quality and density of the grafted area was poor and due to facial bone deficiency, ideal positioning of the implant was not possible during surgery. The implant was observed to be significantly malpositioned axially. The implant was restored at 6 months after second stage surgery. Healing abutment was inserted (Friadent gingival former) to reveal healthy tissue. An implant-level impression with Friadent transfer coping [Figure 2], using the closed custom tray technique, was completed with polyether impression material (Impregum Penta Soft 3M Espe AG Seefeld, Germany). Implant analogs were placed, a gingival replica was completed in silicone material (Gingitech; Ivoclar Vivadent AG, Schaan, Liechtenstein), and

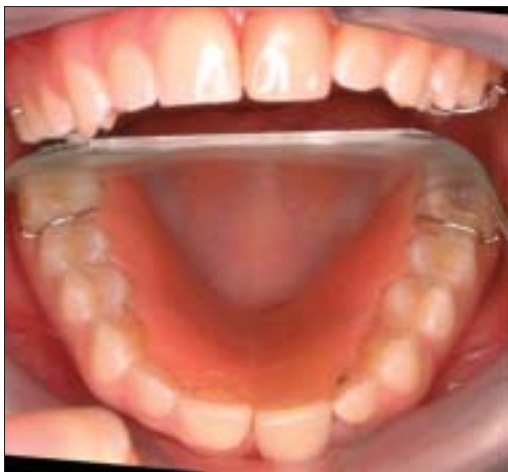

Figure 1: Removable space holder in place

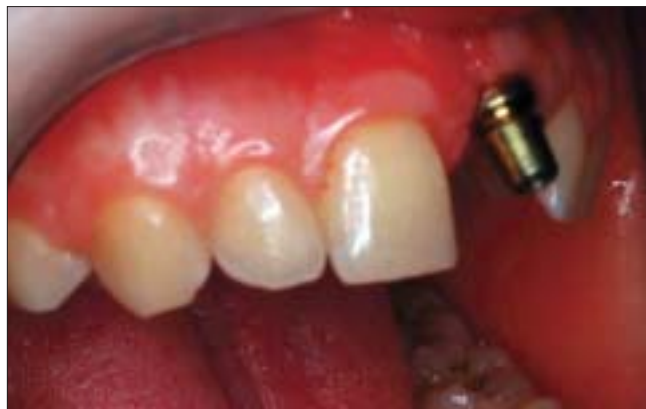

Figure 2: Position of implant can be seen clearly when transfer coping is seated

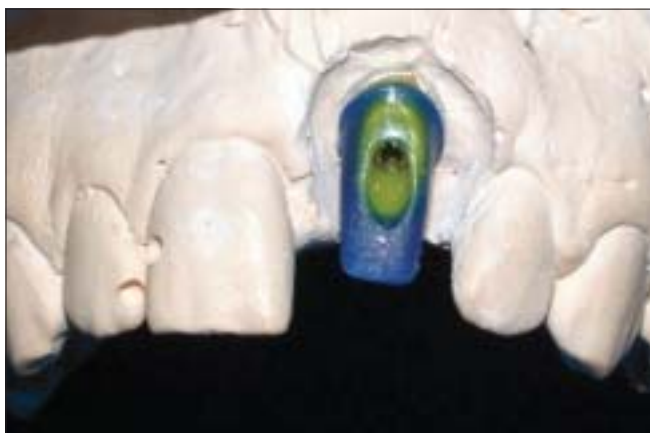

Figure 3: Friadent-AuroBase waxed

the definitive cast was poured in type V die stone. During abutment selection, even angled abutments could not correct the malposition. Treatment options for restoring the dentition to optimal function and esthetics were presented to the patient.

Gold custom abutment fabrication was planned using Friadent-AuroBase [Figure 3]. The Friadent-AuroBase consists of a gold alloy cast to abutment and waxing sleeve. It can be used to fabricate a one-piece restoration incorporating the abutment. The restoration was labially screw-retained to the implant. Prior to placement of the abutments and restorations, healing abutments were removed. The gold custom abutment was prepared and connected to the implant with a titanium screw tightened. The abutment was adjusted and sent back to the technician and ceramic restoration was finished. Metal reinforced ceramic crown was fabricated, coping was tried and margin integrity, occlusal relationship, and esthetics were verified [Figure 4]. The crown was finished, the screw-access opening was filled with cotton packing, and the restorations were cemented using provisional cement designed for cementation of implant restorations. The patient has been followed regularly for routine hygiene and evaluation of long-

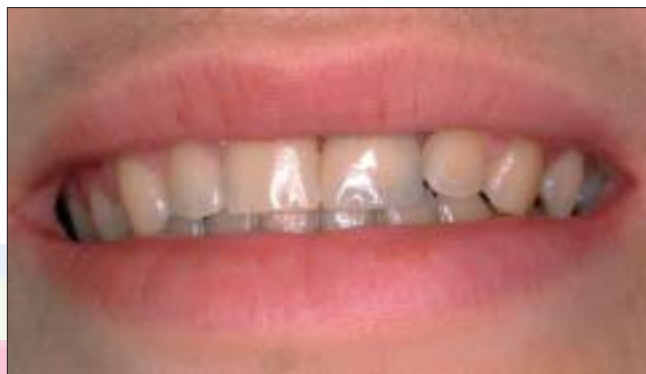

Figure 4: Finished ceramic crown

term success of the restorations. She has continued to report excellent comfort and function and is pleased with the esthetic outcome.

CONCLUSIONS


Horizontal and vertical bone deficiencies result in malpositioning of dental implants. The maximum disangulation in relation to the long axis of the implant is recommended not to exceed 30°; severe malposition of the implant in the esthetic zone may be solved by the prosthodontist to some degree.

REFERENCES

1. Zarb GA, Symington JM. Osseointegrated dental implants: Preliminary report on a replication study. *J Prosthet Dent* 1983;50:271-6.
2. Furhauer R, Florescu D, Benesch T, Haas R, Mailath G, Watzek G. Evaluation of soft tissue around single-tooth implant crowns: The pink esthetic score. *Clin Oral Implants Res* 2005;16:639-44.
3. Higginbottom F, Belser U, Jones JD, Keith SE. Prosthetic management of implants in the esthetic zone. *Int J Oral Maxillofac Implants* 2004;19:62-72.
4. Meijer HJ, Stellingsma K, Meijndert L, Raghoobar GM.

- A new index for rating aesthetics of implant-supported single crowns and adjacent soft tissues--the Implant Crown Aesthetic Index. *Clin Oral Implants Res* 2005;16:645-9.
5. Jansen CE, Weisgold A. Presurgical treatment planning for the anterior single tooth implant restoration. *Compend Contin Educ Dent* 1995;16:746-54.
 6. Bahat O, Fontanesi RV, Preston J. Reconstruction of the hard and soft tissues for optimal placement of osseointegrated implants. *Int J Periodont Rest Dent* 1993;13:255-75.
 7. Belser U, Martin W, Jung R, Hammerle C, Schmid B, Morton D, *et al.* ITI Treatment Guide Vol 1. In: Hammerle C, Jung R, editors. *Prosthetic management of implants in the esthetic zone: general principles and scientific documentation*. Berlin: Quintessence Pub. Co; 2007. p. 38.

Source of Support: Nil, **Conflict of Interest:** None declared.



Author Help: Sending a revised article

- 1) Include the referees' remarks and point to point clarification to those remarks at the beginning, in the revised article file itself. In addition, mark the changes as underlined or coloured text in the article. Please include in a single file
 - a. referees' comments
 - b. point to point clarifications on the comments
 - c. revised article with text highlighting the changes done
- 2) Include the original comments of the reviewers/editor with point to point reply, at the beginning of the article in the 'Article File'. To ensure that the reviewer can assess the revised paper in timely fashion, please reply to the comments of the referees/editors in the following manner:
 - There is no data on follow-up of these patients.
Authors' Reply: The follow up of patients has been included in the results section [Page 3, para 2]
 - Authors should highlight the relation of complication to duration of diabetes.
Authors' Reply: The complications as seen in our study group has been included in the results section [Page 4, Table]