

Cranioplasty with alloplastic cranial implant

Clinical Report

Arpan Pavaiya, Vinod K. Tyagi, Arvind Tripathi, Saumyendra Vikram Singh, Pooran Chand

ABSTRACT

Cranial defects result either from trauma or after intentional osteocraniotomies or external decompression craniectomies. These lead to mechanical vulnerability of the brain, esthetic disfigurement, and transmission of vibrations and pulsation of the brain that cause disconcerting sensations to the patient. Subsequent cranioplasty may be required to compensate for the defect and alleviate various signs and symptoms. A referred posttraumatic patient of a cranial defect that was restored with an alloplastic heat polymerizing methyl methacrylate cranial implant is presented in this case report.

KEY WORDS: Alloplastic, cranioplasty, hemiplegia, hitching, methyl methacrylate

DOI: 10.4103/0972-4052.55256

INTRODUCTION

Cranial defects result from trauma or after intentional osteocraniotomies or external decompression craniectomies. Subsequent cranioplasty is needed to compensate for mechanical vulnerability of the brain and esthetic disfigurement. A 35-year-old male patient with posttraumatic cranial defect [Figure 1], who was referred to the postgraduate departmental clinic and was rehabilitated with an alloplastic cranial implant is presented in this case report. The patient's complaint was loss of esthetics due to a head injury about eight years back leading to impacted compound fracture of the skull. Cranial compression resulted in hemiplegia of the left side that necessitated decompressive cranial surgery. Perioperative the offending piece of parietal skull bone had to be removed, following which, the patient recovered almost completely from hemiplegia within three years and did not report back to the surgeon for cranioplasty. Five years after normalization, he experienced a progressive weakness on his left side that prompted him to return to the neurosurgeon. Cranioplasty was advised and a protocol was worked out by the neurosurgeon and the prosthodontic team. On examination, the patient was found to have a palpable defect on the right side of his skull that was approximately 5 cm in diameter with clearly palpable

margins. Patient was informed about the treatment protocol and his consent recorded.

CASE REPORT

For making an impression of the skull, scalp of the patient was shaved, the outer and inner tables of the defect were marked with an indelible pencil and a mark was made on the middle of the head to orient the cast. Area to be recorded was encircled in a dam of wax sheets. Irreversible hydrocolloid (Zelgan -Dentsply), (Trevalon -Dentsply) was mixed vigorously with cold water to extend the working time, loaded in a 25 ml disposable syringe and then syringed out over the scalp area, starting at the highest point to allow the mixture to flow downward and avoid trapping air. Cotton gauze was partially embedded into the surface of the partially setting material to lock it with the outer layer of plaster of paris (Neel kamal -Kalabhai). After setting, 2-3 layers of quick setting plaster was poured to achieve a firm base of thickness of around 1 cm. After the plaster had set the impression was removed, and poured in dental stone (Dentstone - Pankaj Enterprises) in three layers such that each pour had partially set before the next (to avoid compression of the alginate) with interlocking of the layers ensured by creating grooves [Figure 2]. The cast was then painted with a suitable separating

Department of Prosthodontics and Dental Material Sciences, Faculty of Dental Sciences, C.S.M. Medical University, Lucknow, India

Address for correspondence: Arpan Pavaiya, 2/273, Viramkhand Gomtinagar, Lucknow - U.P. 226 010, India. E-mail: arpanprotho@rediffmail.com

medium, molten wax was poured into the defect for the fabrication of a wax pattern matching the contours of adjoining and contralateral side. A 7-8 mm lip of wax was created on unaltered outer table of defect to ensure proper fit of prosthesis.

Wax pattern was carved out from inside to simulate the thickness of the bone. The wax pattern was retrieved, invested, heat cured, trimmed and polished conventionally with poly methylmethacrylate. The implant was then perforated using surgical drillbits, to prevent fluid accumulation beneath the prosthesis, to ensure growth of fibrous connective tissue to assist in stabilization and to provide means of securing the implant into place by wires. Sterilization of implant was done by ethylene oxide gas at room temperature for 48 hours followed by aeration for 24 hours. Peroperative, after reflection of flap and exposure of the bony defect, bone wax was used as a pressure indicating paste to identify portions of the implant that were preventing proper seating. Points of premature contacts were

removed either by reducing the implant surface or by nibbling the bone [Figure 3]. The implant was made to seat in the defect properly and hitching of dura was done to bring dura in close proximity to bone to prevent extradural hematoma formation. Holes were then drilled into the bone using surgical drillbits to secure the implant in place by means of titanium wires, which were twisted into place, and the flap was sutured back into position. Sutures were removed on the seventh postoperative day and the patient was discharged with uneventful healing and completely recovered from symptoms in 6 months [Figure 4].

DISCUSSION

Implants are of value in cases where the fractured piece of skull is short of fit in the defect because of intractable small pieces, or where the bone got infected. Autogenous bone grafts are not commonly indicated because of complications such as absorption and loss of contour. Alloplastic implant materials like metals,

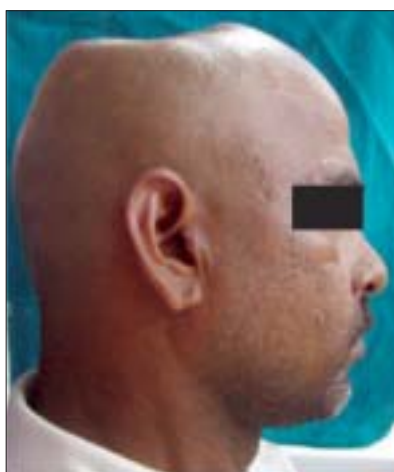

Figure 1: Preoperative profile view

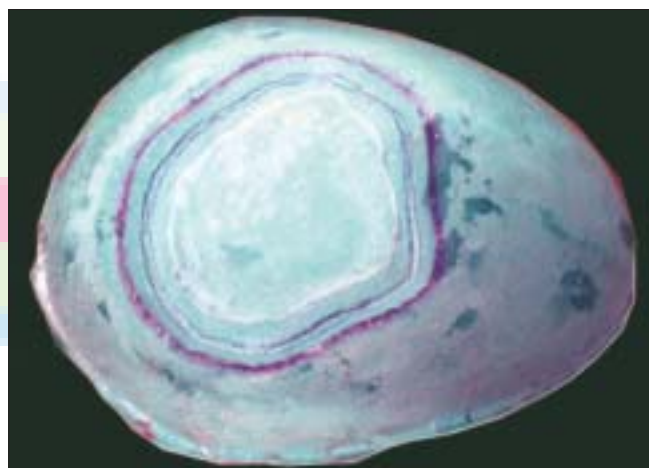


Figure 2: Cast of scalp with margins of defect outlined

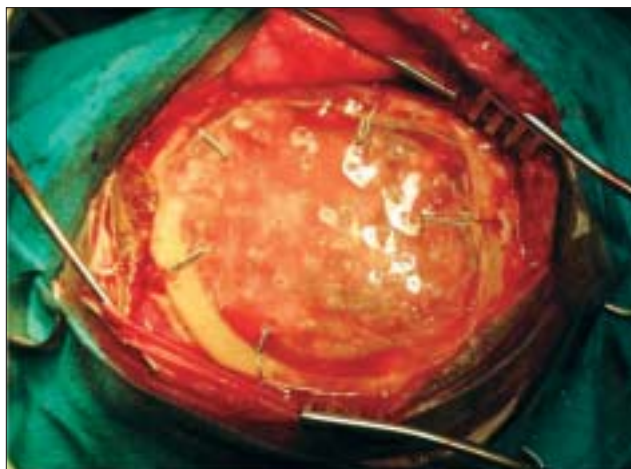


Figure 3: Cranial implant in place peroperatively

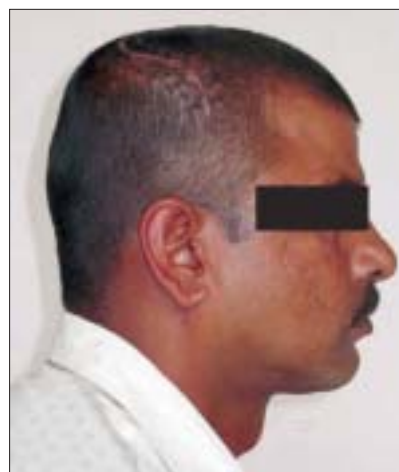

Figure 4; Postoperative profile view. *Zelgan -Dentsply, **Neel kamal -Kalabhai, ***Dentstone - Pankaj Enterprises, *Trevalon -Dentsply

autopolymerizing and heat polymerizing methacrylate, silicone and polyethylene have been reported. Metals such as tantalum, titanium, austenite stainless steel, and vitallium carry the advantage of being hard, malleable, and readily available, but their high thermal conductivity may precipitate headaches and other neurological symptoms. Silicones and polyethylene are tissue compatible but their flexibility compromises protection in cranial defects. Autopolymerizing acrylic resin is relatively inert, strong, noncarcinogenic, readily available in sterilized form, and has poor thermal and electrical conductivity, but it has the disadvantage of exposing the tissue bed to heat of polymerization and monomer. Heat polymerizing acrylic resins overcomes the disadvantages of autopolymerizing acrylic resins and are stronger, rigid, more inert with good reproduction of contours.^[1] Today, three-dimensional modeling is revolutionizing cranioplasty with detailed and accurate reproductions of the human skull possible using computed tomography and stereolithography. Rapid prototyping technology is used for creating intricate structures more accurately, whereby model fabrication is done as a removal process by carving

away material from a solid block or sheet.

Local discomfort at the site of cranial defect may be an indication for cranioplasty, which may result particularly in large defects upon rapid movements or periods of exertion and could be precipitated by intracranial tissues coming into contact with bony margins of the defect. Vibrations and pulsation of brain may be disconcerting to the patient. Some clinicians believe that the cranial implant “splints” the brain, decreases its mobility, and thereby relieve the symptoms.^[2-4]

Esthetic disfigurement may alone be a sufficient reason to seek cranioplasty as noticeable cranial defects are often interpreted by the public as signs of mental disturbance or retardation. Additionally, anxiety precipitated by fear of injury to unprotected brain may be a motivating factor.^[5]

Adequate rehabilitation of skull disfigurement with regained strength on left side of the body were highlights of the case report.

REFERENCES

1. Beumer J 3rd, Firtell DN, Curtis TA. Current concepts in cranioplasty. *J Prosthet Dent* 1979;42:67-77.
2. Spence WT. Form fitting cranioplasty. *J Neurosurg* 1954;11:219-25.
3. Fodstadt H, Eksedt J, Friden H. CSF hydrodynamic studies before and after cranioplasty. *Acta Neurochir Suppl (Wein)* 1979;28:514-8.
4. Timmons RL. Cranial defects and their repair. *Neurological surgery*. In: Youmans JR, editor. 2nd ed. Philadelphia: W.B. Saunders Co; 1982.
5. Shaw RC, Thering HR. Reconstruction of cranial defects. *Clin Plast Surg* 1975;2:539-49.

Source of Support: Nil, Conflict of Interest: None declared.