

# New spring retained surgical obturator for total maxillectomy patient

## Clinical Report

*Pravinkumar G. Patil, Rambhau D. Parkhedkar*

### ABSTRACT

Prosthetic rehabilitation with surgical obturator for total maxillectomy patients is a challenging job because of the lack of normal hard and soft tissue support. In such cases the obturator can be retained with a spring-retained appliance if mandibular dentition is normal. A patient (treated with total maxillectomy) was rehabilitated with a new spring-retained surgical obturator. The spring used in this type of appliance is made up of 23-gauge stainless steel orthodontic wire which incorporates four coils. The spring is simple in design, applying light, clinically acceptable seating force, easily cleansable and causing no soft tissue irritation.

**KEY WORDS:** Spring-retained appliance, surgical obturator, total maxillectomy

DOI: 10.4103/0972-4052.52872

### INTRODUCTION

Oral squamous cell carcinoma is the most common malignancy of the head and neck region.<sup>[1]</sup> Partial or total jaw resection followed by radiation therapy is the treatment of choice for such patients. A surgical obturator for a patient who has undergone partial maxillectomy can be retained with the remaining normal hard and soft tissues.<sup>[2]</sup> Rehabilitation of patients with total maxillectomy is difficult because of the absence of normal hard and soft tissues. In such situations, the prosthesis is wired or pinned to the available bony structure.<sup>[3]</sup> Wires or surgical implants can interfere with the healing procedure and the obturator is too high to maintain contact with the dorsum of the tongue during deglutition. This whole process requires another surgical intervention to remove wires or implants. Hence the spring-retained surgical obturator can be a better option. Literature describes many such appliances such as spiral spring appliance, Heydenreich spiral spring and flat spring appliance.<sup>[4]</sup> This clinical report describes a clinical case (treated with total maxillectomy) rehabilitated with new spring appliance.

### CASE REPORT

A 19-year-old boy reported to the Department of Prosthodontics, Government Dental College

and Hospital, Nagpur (India), with a left hemi-maxillectomy. A review of the medical and dental history revealed that the patient was operated for "squamous cell carcinoma of left maxilla" six months previously and rehabilitated with a surgical obturator. Intra-oral examination confirmed that the patient had a swelling on the right maxillary buccal vestibule [Figure 1]. Radiographic and pathologic examination revealed that the patient had recurrence of the squamous cell carcinoma on the right side. Examination of mandibular arch shows healthy hard and soft tissues.

Impressions of both the arches were made with irreversible hydrocolloid (Plastalgin, Septodont, Cedex, France). Casts were prepared with type III gypsum material (Kalstone, Kalabhai Karson Pvt. Ltd., Mumbai, India). The maxillary cast was modified by scraping the remaining right maxillary teeth and the alveolar part. Maxillary obturator plate was fabricated with heat polymerizing acrylic resin (DPI-Heat Cure, Dental Products of India Ltd., Mumbai) on modified maxillary cast [Figure 2]. Mandibular retentive plate was fabricated with heat polymerizing acrylic resin with "Adams clasps" on both mandibular first molars and "C clasps" on both mandibular first premolars [Figure 2].

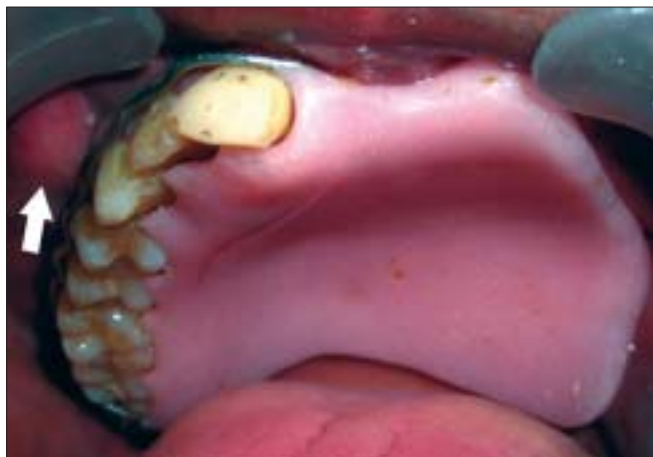Twenty-three-gauge, hard, round, stainless steel orthodontic wire (KC Smith and Co., Monmouth, UK)

Department of Prosthodontics, Government Dental College and Hospital, Nagpur, India

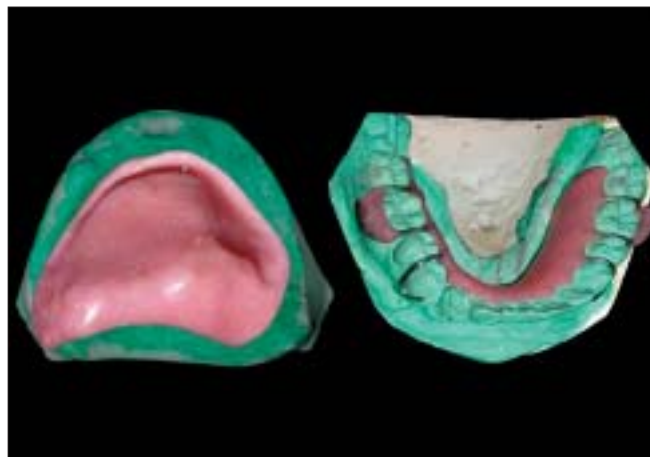**Address for correspondence:** Dr. Pravinkumar G. Patil. At- Vajrachounde, Post- Gavan, Tasgaon, Sangli, Maharashtra - 416408, India.  
E-mail: pravinandmita@yahoo.co.in

was used to prepare the spring [Figure 3]. The design includes four coils: a, b, c and d. Coil 'c' helps in opening and closing movements. Coil 'b' allows anterior and posterior action. On closing movement of the jaw, coil 'c' gets closed and vice versa. On posterior movement of

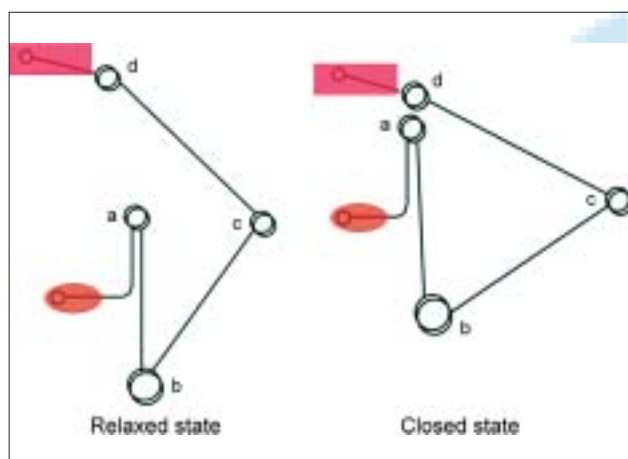
the jaw, coil 'b' gets opened and vice versa. Coil 'a' and 'd' near individual attachments give freedom to the respective attachments. All four coils act simultaneously and permit jaw movements. Two such springs were prepared.<sup>[5]</sup>



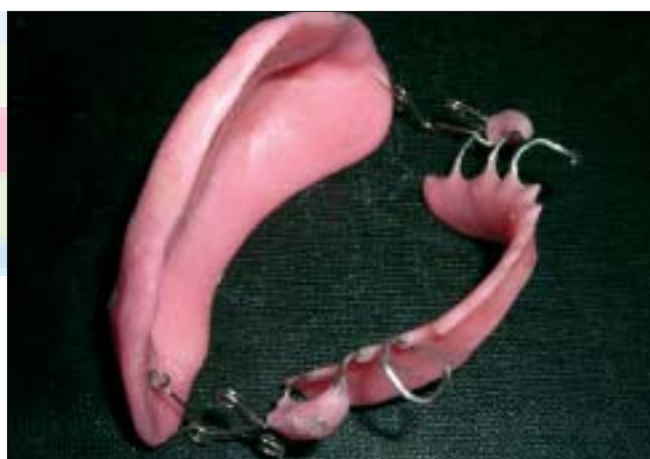**Figure 1:** Arrow indicates recurrence of carcinoma on right buccal vestibule



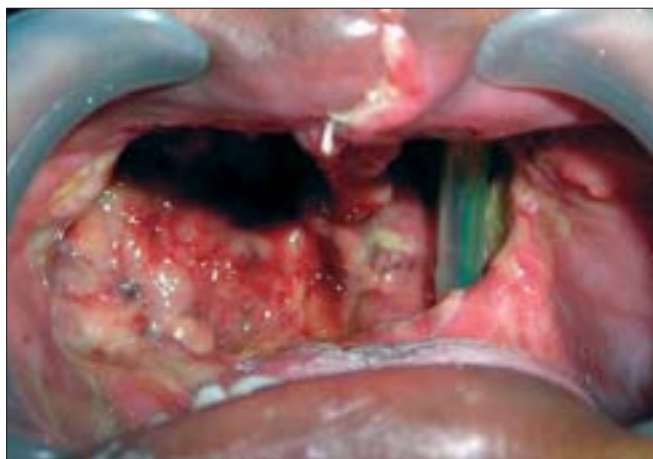**Figure 2:** Scanned maxillary cast with obturator plate, mandibular retentive plate (note auto-polymerizing acrylic resin was applied to both Adams clasps)



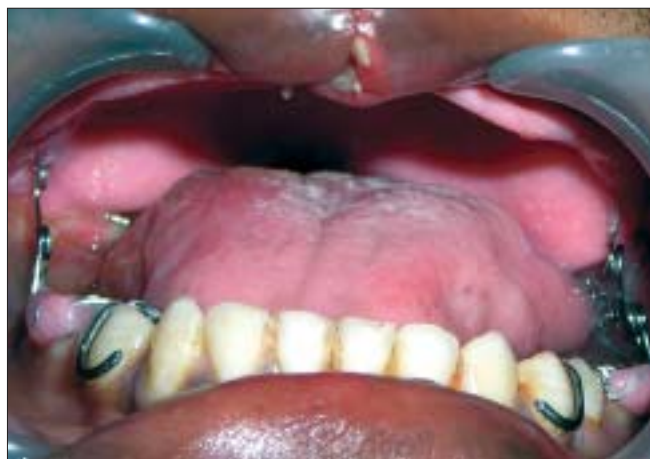**Figure 3:** Schematic diagram of the spring



**Figure 4:** Complete appliance with springs attached on both sides



**Figure 5:** Intra-oral defect after total maxillectomy



**Figure 6:** Spring-retained surgical obturator in mouth

Next the lower end of one spring was attached to one of the "Adams clasps" with the help of self-polymerizing acrylic resin (DPI-Cold Cure, Dental Products of India Ltd., Mumbai). Another spring was attached to the opposite Adams clasp in a similar way. The maxillary obturator plate was attached to the upper ends of both the springs [Figure 4]. The appliance was kept ready before surgery.

As the surgical defect was too extensive the patient was examined seven days post-surgically for placement of the appliance [Figure 5].<sup>[3]</sup> The correct position of the maxillary obturator plate in relation to the mandibular retentive plate was adjusted by opening or closing any of the four coils of the springs on both sides. The obturator was delivered and post-insertion instructions were given [Figure 6]. The patient was sent to the Radiology Department for radiotherapy and was followed at a regular interval of two weeks for routine assessment of the tissue conditions and appliance modification. The patient was comfortably

taking soft and liquid diet since last six months. The healing was satisfactory.

## DISCUSSION

There is limited data on immediate postoperative prosthodontic rehabilitation of the patients who have undergone total maxillectomy. Usually wire or implant retained surgical obturators are difficult to manage because of massive surgical defects, continuous contracture of the wound, and side effects of radiation therapy. Hence a removable (spring-retained) surgical obturator is the best solution for such situations. The obturator develops the seal with dorsum of the tongue during deglutition thus helping the patient to take liquid and soft diet orally and avoid feeding through a nasogastric tube. It is true that continuous seating force of the springs can cause soft tissue blanching or bone resorption underlying the appliance. But the time period for wearing the appliance is too short (four to six months) to cause such changes.

## REFERENCES

1. Shafer WG, Hine MK, Levy BM, Tomich CE. A textbook of oral pathology. 4<sup>th</sup> ed. Philadelphia: W. B. Saunders Company; 1993. p. 112-7.
2. Beumer J, Curtis TA, Firtell DN. Maxillofacial rehabilitation-prosthodontic and surgical considerations. St. Louis: Mosby; 1979. p. 216-43.
3. Beumer J, Curtis TA, Firtell DN. Maxillofacial rehabilitation-prosthodontic and surgical considerations. St. Louis: Mosby; 1979. p. 207-16.
4. Laney WR, Gibilisco JA. Diagnosis and treatment in Prosthodontics. Philadelphia: Lea and febiger; 1983. p. 401-5.
5. Patil PG, Parkhedkar RD. Management of a patient with complete mandibulectomy and partial glossectomy with innovative spring appliance: A case report. J Indian Dent Assoc 2007;1:134-7.