

A simple articulator for maxillofacial prosthetics

Clinical Report

Mohamed Behanam, R. Haribabu, A. Anuroopa

ABSTRACT

In patients with a defective maxillo-mandibular complex, the foremost challenge in achieving an accurate centric or eccentric record is the sheer irregularity and non-repeatability of the movements of the mandible. As a result, mandatory clinical procedures like jaw relations, intra or extra-oral tracings and interocclusal records are made complicated, and the accuracy of such records, questionable. Hence every maxillofacial patient must be considered on an individual basis and rehabilitation procedures customized to suit the clinical situation, rather than strictly adhering to theoretical principles. This involves procedures like customizing the record bases, occlusal schemes and individualized training regimens for these patients, along with some modifications in the existing articulators. One such modified articulator is presented here.

KEY WORDS: Articulator, chew-in record, condylar element, functionally generated path, incisal guidance, incisal guide table, incisal rod, interocclusal records, maxillofacial prosthetics, tongue-in-groove mechanism

DOI: 10.4103/0972-4052.52868

INTRODUCTION

Rehabilitation of a patient with congenital or acquired defect is the unenviable responsibility of any maxillofacial prosthodontist. These procedures require the use of devices to replicate and reproduce the mandibular movements, so that the prosthesis fabricated is physiologically and functionally stable and acceptable. The articulator is a device which has seen a lot of modifications, developments and improvements over the years, right from the days of the plaster articulators.^[1] But modifications specific to maxillofacial prosthodontics have been too few and far between.

Although the history of articulators dates back to the 1830s,^[2] modification of an articulator for a maxillofacial patient was done in 1958 by Flinchbaugh,^[3] who converted a Hanau Model H articulator (Teledyne Hanau, Buffalo, N.Y.) into a high post instrument by means of a 0.75 inch lucite shim (L.D.Caulk Co., Divn of Dentsply International, York, Pa). This modification had its disadvantages,

which were that it precluded the use of a facebow, besides which the space between the upper and lower members was inadequate to accommodate the reconstruction model.

In 1980, Hadeed and Sprigg^[4] modified a Whipmix articulator (Whipmix Corp., Louisville, Ky) by incorporating a condylar elevating rod which is threaded to the lower member. A long incisal pin and incisal pin extension rod of the Hanau articulator series were screwed together to allow for the increased dimension. The disadvantage of this modification was that the detent lever could no longer maintain the upper member in the recorded position.

Further, in 1983, Marunick and Tsun^[5] modified an arcon Hanau articulator (Teledyne Hanau, Buffalo, N.Y.). The modification provided adequate vertical space while maintaining the condylar element in its original position and accepted facebow registration. The authors modified a non-arcon Hanau articulator as well.

Department of Prosthodontics, JKK Nataraja Dental College, Komarapalayam - 638 183, Namakkal Dt, Tamil Nadu, India

Address for correspondence: Dr. P.A. Mohamed Behanam, 18/653(2), Palakkavalappil House, Thottingal, Near D. P. O, Palakkad, Kerala - 678 014, India. E-mail: behanam_mds@rediffmail.com

CASE REPORT

Centric relation, centric occlusion and jaw relation records have all been defined within the purview of an anatomically and physiologically healthy maxillo-mandibular complex.^[6] Apart from the general factors that affect any removable prosthodontic rehabilitation such as age, dentulousness, size and relation of jaws, anatomy of temporomandibular joints etc, additional factors^[7] for a maxillofacial patient include:

1. Available denture foundation
2. Post-operative residual movement of mandible, its limits and reproducibility
3. Sequelae of radiation
4. Neuromuscular co-ordination
5. Trismus and restricted mandibular movements
6. Mental and emotional trauma

As a result, the rehabilitation may require a reduced vertical dimension, tracings may be complicated and border movements may possibly be limited and altered.

The use of a mean value articulator [Figure 1a] in maxillofacial prosthetics has the following disadvantages:

1. A non-adjustable condylar guidance set to a mean value
2. Does not accept a facebow transfer
3. No freedom of movement allowed from centric to eccentric positions
4. Inadequate space between upper and lower member to accommodate the increased dimension of the model [Figure 1b]

Since the mandibular movements and interocclusal records are inconsistent and of questionable accuracy, extensive restorative procedures are generally not warranted, because the emphasis is more often to rehabilitate the patient with an interim prosthesis, till such time as results of the concurrent surgical, chemo-or radiotherapy can be obtained and a definitive treatment plan can be formulated. Hence, owing to these factors, a mean value instrument offers distinct advantages over a more complicated, fully adjustable articulator. One such articulator is presented here, with some modifications incorporated to overcome the few basic drawbacks that have been enumerated above.

DISCUSSION

The first and foremost modification is the increase in

vertical height of the articulator by incorporating a vertical bar of 2 inch length which raises the level of the upper member with the hinge of the articulator representing the condylar element, in the original position [Figure 2a]. The second modification is the incorporation of a modified long incisal rod to accommodate the increase in the vertical height of the articulator [Figure 2b].

The vertical bar raises the height of the upper member, yet the orientation of the cast with respect to the reference points (two posterior and one anterior-the central pin) remains unchanged. Further, an antero-posterior tongue-in-groove mechanism has been incorporated^[8] [Figure 2b]. This mechanism permits lateral and circular movements, when the holding screw is loosened. This entails freedom to make minor adjustments in two planes and represents a modification adapted from the history of articulator evolution, wherein movements are allowed from static recorded positions using the custom guides or chew-in records. Hand manipulating the upper member against the lower member of the articulator by following an intra-oral stereographic record commonly known as the functionally generated path or intra-oral chew-in is the technique used to generate the custom guide controls. According to Bergstrom,^[9] L Warnekros was probably the first to mention this technique, later fully described by Charles Luce,^[10] and even later well known to the profession as the 'Needles-House chew-in technique'.

The incisal pin was thought of as a form of vertical stop initially, and it was operators like Luce^[11], Eltner, Gysi and Hall^[8] who introduced the concept of an incisal guide to the movement. This instrument has a flat rectangular incisal table of 2 inch length and 1 inch width to allow for the wider lateral functional chew-in record [Figure 3]. After articulation of the models using a static positional record, hand manipulation and custom scribing of the anterior guidance is done in impression compound (Pinnacle, DPI Products, Bombay, India) using the functionally generated path recorded in a wax occlusal rim intra-orally [Figures 4a and 4b].

This articulator is being used at the Department of Prosthodontics, Saveetha University, Chennai with successful results, for interim rehabilitation of maxillofacial patients [Figure 5]. The emphasis has been to keep the design as simple as possible, to enable ease of use and universal applicability. Though the above design can be faulted as being an average value articulator with non-adjustable



Figure 1: (a) A mean value articulator, (b) Inadequate clearance for the restorative model




Figure 2: (a) Modified articulator, (b) Long incisal rod and tongue-in-groove mechanism in the upper member




Figure 3: Flat incisal guide table

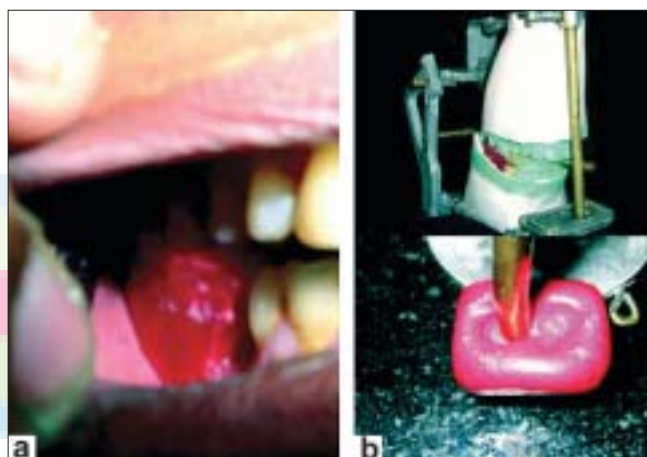

Figure 4: (a) Functionally generated chew-in record, (b) Articulation and hand manipulation to generate the custom anterior guide

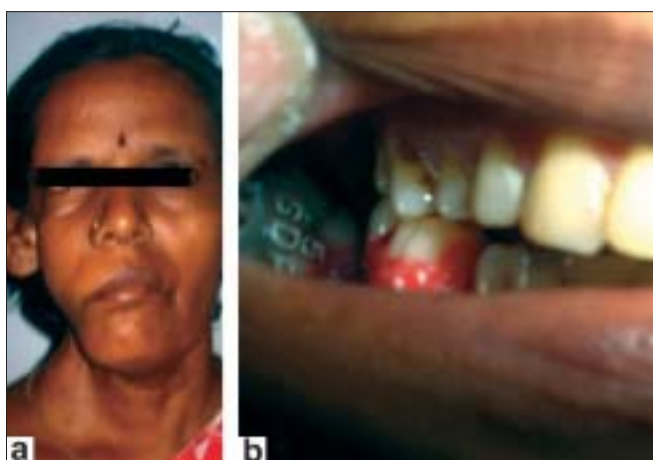

Figure 5: (a), (b) Rehabilitated patient with an interim prosthesis

condylar guide controls as well as the inability to use a facebow, it must be noted that this instrument is always used in the fabrication of an interim prosthesis, till such time as a definitive treatment plan can be formulated and executed. Anybody familiar with treatment regimens for these patients will agree that this depends upon a lot of factors, like the patient's response to treatment, either chemo- or radiotherapy, recurrence of surgically excised lesion, the basic general health of the patient etc. The focus is to adopt a wait and watch policy, i.e., not to do extensive restorative procedures, yet improve the quality of life of the patient, and it is in situations such as these that this instrument has proven to be invaluable.

REFERENCES

1. Starcke EN. The history of articulators: A perspective on the early years, Part 2. *J Prosthodont* 1999;8:277-80.
2. Fairhurst R. The Wadsworth Articulator. *Dent Record* 1929; 49:58-66.
3. Flinchbaugh RW. Modification of the model H Hanau articulator and facebow. *J Prosthet Dent* 1958;8:781.
4. Hadeed GJ, Sprigg RH. Articulator modification for maxillofacial prosthesis. *J Prosthet Dent* 1980;44:209-10.
5. Marunick MT, Ma T. Articulator modification for maxillofacial prosthetics. *J Prosthet Dent* 1983;49:685-6.
6. The Glossary of Prosthodontic Terms. *J Prosthet Dent* 1999; 81:39-110.
7. Curtis TA, Taylor RC, Rositano SA. Physical problems in obtaining records of the maxillofacial patient. *J Prosthet Dent* 1975;34:539-54.
8. Starcke EN. The history of articulators, The appearance and early use of incisal pin and guide. *J Prosthodont* 2001;10:52-60.
9. Bergstrom G. On the reproduction of dental articulation by means of articulators, a kinematic investigation. *Acta Odont Scand Suppl* 1950;9:1-149.
10. Luce CE. Mandibular movements and the articulator question. *Dent Rev* 1910;24:1102-11, 1152-7.

