

Velopharyngeal obturator in partially edentulous patient

Clinical Report

Rajesh Shetty, Kamalakanth K. Shenoy, Makham Gangaiah

ABSTRACT

Congenital large intraoral defects are amenable to prosthodontic rehabilitation as surgical procedure alone cannot restore the function of residual palatal tissues. This study presents the case report of a partially edentulous patient with congenital cleft palate (Veau's Class III). The procedure for fabrication of definitive velopharyngeal obturator attached to conventional removable partial denture is described.

KEY WORDS: Velopharyngeal obturator

DOI: 10.4103/0972-4052.57089

INTRODUCTION

Obturator is that component of a prosthesis which fits into and closes a defect within the oral cavity or other body defect.^[1] The intraoral defects can be either congenital or acquired. Palatopharyngeal insufficiency is an acquired or congenital anatomic defect of the soft palate that makes the palatopharyngeal sphincter incomplete.^[1] The closure of the soft palate defect to control nasal emission during speech and prevent leakage of foods and liquids is usually accomplished by the fabrication of a partial denture or complete denture.

Mazaheri and Millard^[2] suggest that for optimal restoration of function and speech the following guidelines should be observed:

- 1) Superior extension should be located in the nasopharynx at the level of normal palatal closure.
- 2) Inferior extension should be a continuation of the palatal plane and should be concave to provide adequate space for tongue movement.
- 3) Inferior margin should be placed at the region of maximum pharyngeal activity.
- 4) Superior surface should be convex and polished to deflect nasal secretions into the oropharynx.

This article presents a case report of a 21-year-old female partially edentulous with velopharyngeal insufficiency, rehabilitated with a velopharyngeal obturator attached to conventional removable partial denture.

CASE REPORT

A 21-year-old female patient reported to the department of Prosthodontics, Yenepoya Dental College, Mangalore, with a chief complaint of missing upper front teeth and difficulty in swallowing food. History revealed cleft palate since birth. Cleft lip was surgically corrected in childhood and she had undergone orthodontic correction of misaligned teeth two years back. Extra oral examination revealed gross asymmetry of nose with deviation to left side and a surgical scar on the upper lip due to previous surgical correction of cleft lip [figure 1a]. Her speech was not intelligible with a nasal twang in her voice lacking resonance. Intraoral examination revealed a partially edentulous state maxillary Kennedy's Class III mod 2 and mandibular Kennedy's Class I (16, 21, 22, 26, 36, 37, 47 and 48 Missing) with a Veau's class III defect i.e. unilateral cleft lip, alveolus, hard and soft palate [Figure 1b]. The inferior turbinates were visible through the defect. Detailed case history revealed that oronasal communication was present since birth and the defect

Department of Prosthodontics, Yenepoya Dental College, Deralakatte, Mangalore, India

Address for correspondence: Dr. Gangaiah M, Department of Prosthodontics, Yenepoya Dental College, Deralakatte, Mangalore, India.
E-mail: mysorumallige@yahoo.com

was not treated surgically because of its large size.

Considering her oral conditions, functional and esthetic requirements, a closed velopharyngeal/ speech bulb obturator attached to a cast partial denture was planned for the patient. A gauze strip lubricated with petroleum jelly was packed into the cleft area prior to impression making to prevent the impression material from being forced into the nasal cavity.^[3] A preliminary irreversible hydrocolloid impression (Tropicalgin, Zhermack) was made in a stock metal tray after having modified the tray with modeling wax (Hindustan modeling wax, Hindustan Dental Products Ltd) [Figure 1c-d]. The impressions were poured with gypsum type III (Gypstone, Prevest Denpro Ltd) to obtain primary casts. The casts were surveyed for determining useful undercuts and path of insertion. The undercuts were blocked and custom trays of auto polymerizing resin were fabricated with a two sheet thickness spacer of modeling wax over dentulous area and single sheet thickness over the edentulous areas.

Tooth preparation was carried out as planned, both in maxillary and mandibular arches, and final impression was made with monophasic elastomeric impression material^[4] (Aquasil monophasic, Dentsply) [Figure 2a]. The definitive casts were poured with type IV gypsum (Kalrock™, Kalabhai pvt ltd.) [Figure 2b] and again surveying was carried out. Frameworks^[5] were designed and beading was made on the master cast. Block out of master cast was done and duplicated in reversible hydrocolloid (Wirogel, Bego) to obtain refractory cast (Wirovest, Bego). Wax pattern was designed with a loop in the posterior border of the full palatal plate to attach the obturator section and sprued for investing and casting with Cobalt-chromium alloy (Wironit, Bego). The height of the loop was approximately determined by measuring the distance between the last molar and atlas and the same was measured on the cast. In a study it was found that in females the velopharyngeal closure is usually at or below the palatal plane.^[5]

The framework was retrieved, trimmed, polished and try-in was done [Figure 2c]. Facebow (Artex™, Girrback), vertical and centric records were made and mounted onto the semi adjustable articulator (Arcon, Artex™ Girrback). Semi anatomic artificial teeth (Lactodent™, Pyrax polymers) were arranged. Following the trial, the denture was waxed up and then acrylized (DPI™ Heat Cure) in the conventional manner.

The loop part of the maxillary cast partial denture was initially built with high fusing compound (Y-DENTS, Impression composition) as tray. The border molding of the tray compound was carried out with low fusing compound (DPI pinnacle, Tracing stick) till the position and contours of the obturator were satisfactory [Figure

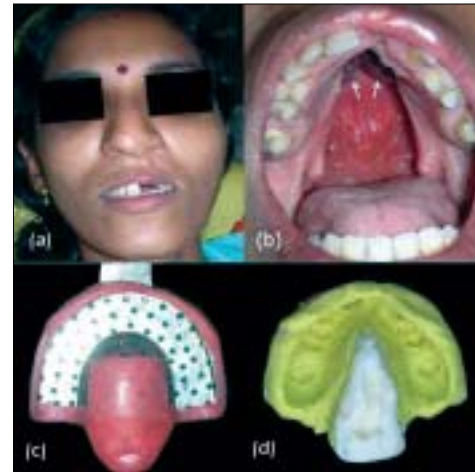

Figure 1: (a) and (b) extra oral and intra oral preoperative pictures of the patient, (c) modified stock tray and (d) primary impression with irreversible hydrocolloid material

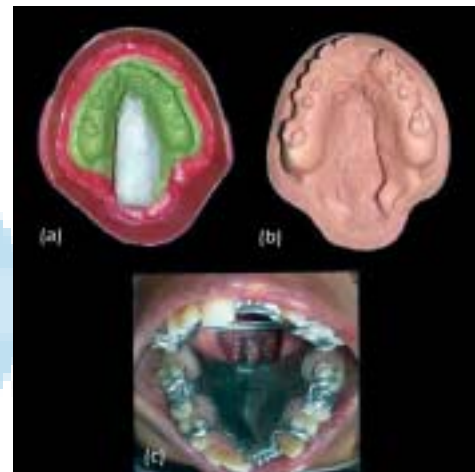


Figure 2: (a) secondary impression with beading and boxing, (b) definitive cast, (c) framework try-in.

3a]. The indentations made by the tonsillar pillars and the Passavant's ridge were visible with no shiny areas and the patient was able to speak, swallow and breathe through the nostrils effectively. The pharyngeal portion was molded by making the patient move her head in a circular manner from side to side, to extend her head as far forward and backward as possible and to say 'ah' and swallow.^[6] Final impression was made with light body polyvinyl siloxane impression material (Aquasil Ultra LV, Dentsply) [Figure 3b]. Altered cast procedure was carried out to transfer the obturator section to the master cast^[3] [Figure 3c-d]. With the framework on the altered cast the pharyngeal section was waxed up with the palatal surface concave following the contours of the palatal vault and was acrylized in conventional manner.

The prosthesis was then inserted in the patient's mouth [Figure 4a-b]. The extensions, speech and occlusion were

evaluated. Necessary adjustments were done. Speech did not show a definite improvement because of her persistent compromised pattern of tongue movements so the patient was referred to a speech therapist. The position of the obturator was confirmed by means of a lateral cephalogram of the patient taken with the prosthesis in place after coating the obturator portion with a radio opaque material (barium sulfate).

DISCUSSION

Rehabilitation of cleft palate involves essentially a multidisciplinary approach. The size and location of the defect are important considerations in selecting the method of rehabilitation. Small defects of the alveolar ridge and hard palate are easily closed surgically where as larger hard palate and/or soft palate defects are more amenable to prosthodontic obturation.

Alternative Treatment

- a) Nasal alveolar molding
- b) Surgical closure

Nasal alveolar molding- should have been considered at early childhood during the active growth period since it would provide more simple and successful surgical procedure.

Surgical closure of the palate for the patient treated was not considered because of the wide cleft, limited amount of local tissues present and need for multiple surgeries.

Since the above mentioned treatment options could not be exercised, it was decided to rehabilitate the patient using a removable prosthesis.

In this case report, the partially edentulous patient with hard and soft palate defect, complete palatal major connector was used to obturate the palatal cleft and velopharyngeal bulb for velopharyngeal inadequacy. There was no scope for extension of the obturator into the defect as the inferior turbinates and other sensitive tissues were present. The design of the framework provided sufficient retention for the prosthesis.

Patient Motivation and Education

- To try and improve speech pattern effectively under speech pathologist
- Educate the patient about insertion and removal of the prosthesis
- Maintain good oral hygiene
- Make patient understand importance of monthly recall visits

Home Care of Prosthesis

- Removal of the prosthesis for cleaning nasal secretion

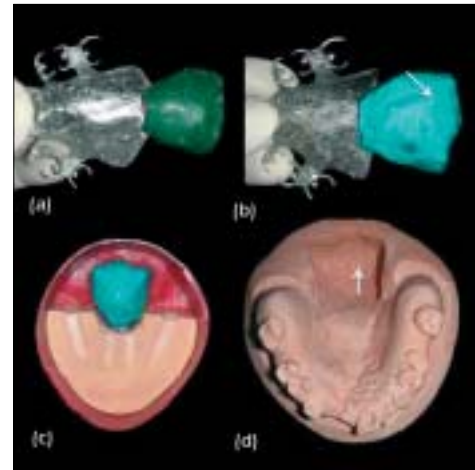


Figure 3: (a) molding of the pharyngeal section with low fusing compound, (b) final impression with light body polyvinyl siloxane, (c) beading and boxing for obtaining altered cast, (d) altered cast.

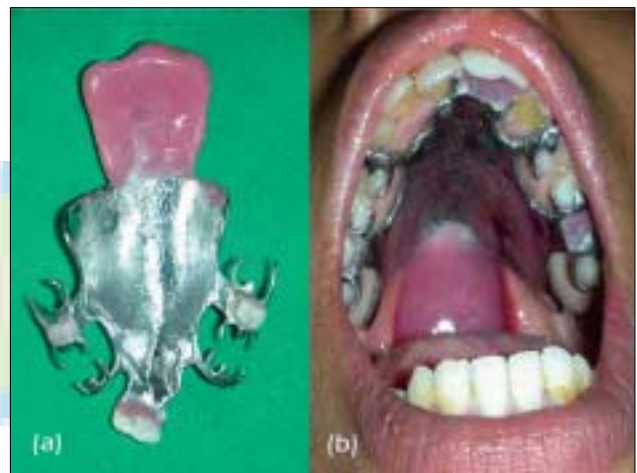

Figure 4: (a) finished prosthesis, (b) intra oral prosthesis

collected every hourly

- Use of mild cleansing solutions with denture cleaning brush
- Use of denture cleansing tablets
- Practice speech by reading newspaper aloud in front of a mirror.

Check Up Visits

- Weekly appointments for correction of sore spots, occlusion and observation for improvement of speech.
- Reinforcement of speech therapy since the musculature involved in velopharyngeal closure is continuously adapting to the new prosthesis and is necessary to adjust the prosthesis during recall visits.
- Monthly visits to evaluate fit of prosthesis and improvement in speech.

Limitations

- Patient cannot separate teeth portion of the prosthesis

if she wishes to use them separately.

- Patient adaptation to prosthesis would have been much better if prosthodontic treatment would have been preceded by surgery.
- Patient adaptation to the prosthesis takes much


longer time because of the continuous remodeling of velopharyngeal tissues that takes place in due to its contact with the speech bulb.

- Initial speech impediment.

REFERENCES

1. Glossary of prosthodontic terms – 8
2. Mazaheri M. Prosthetics in cleft palate treatment and research. *J Prosthet Dent* 1964;14:1146-58.
3. Beumer J, Curtis TA, Marunick MT. Maxillofacial rehabilitation, prosthodontic and surgical considerations. Ishiyaku Euro America: St. Louis; 1996. p. 399-402.
4. Morrow RM, Rudd KD, Rhoads JE. Dental laboratory procedures: Complete dentures. Vol. 1. 2nd ed. Mosby: St. Louis; 1985. p. 312-24.
5. Turner GE, Williams WN. Fluoroscopy and nasoendoscopy in designing palatal lift prostheses. *J Prosthet Dent* 1991;66:63-71.
6. Chalian VA, Drane JB, Standish SM. Maxillofacial prosthesis, Multidisciplinary practice. The Williams and Wilkins Company: 1972. p. 358-9

Source of Support: Nil, Conflict of Interest: None declared.



Staying in touch with the journal

- 1) **Table of Contents (TOC) email alert**
Receive an email alert containing the TOC when a new complete issue of the journal is made available online. To register for TOC alerts go to <http://www.jprosthodont.com/signup.asp>.
- 2) **RSS feeds**
Really Simple Syndication (RSS) helps you to get alerts on new publication right on your desktop without going to the journal's website. You need a software (e.g. RSSReader, Feed Demon, FeedReader, My Yahoo!, NewsGator and NewzCrawler) to get advantage of this tool. RSS feeds can also be read through FireFox or Microsoft Outlook 2007. Once any of these small (and mostly free) software is installed, add <http://www.jprosthodont.com/rssfeed.asp> as one of the feeds.