

# Fabrication of a Functional Finger Prosthesis With Simple Attachment

Bikash Pattanaik · Seema Pattanaik

Received: 1 August 2011 / Accepted: 29 November 2012 / Published online: 8 December 2012  
© Indian Prosthodontic Society 2012

**Abstract** Finger prosthesis is more acceptable by the patient when it allows some of the movement in the prosthesis along with the restoration of a natural appearance to the lost structures of the patient. This article describes a custom-fabricated, custom-colored prostheses made from silicone elastomers with a simple attachment to make the prosthesis functional to imitate some of the movement.

**Keywords** Finger prosthesis · Functional prosthesis · Attachment

## Introduction

Prosthetics is an art and science which offers a natural appearance to the lost structures of the patient. Loss of even one finger produces significant functional deficiencies. Loss of a finger may cause marked psychological trauma, in addition to loss of grip strength and security. Most common causes of finger absence are amputations

due to traumatic injuries, disease, congenital absences or malformations [1]. Cosmetics characteristics such as a realistic shape, color, contours, thin margins and life-like fingernails are essential for patient satisfaction. Functional disability can be partially restored by incorporating some attachment or wire into the prosthesis. Such attachment can allow the movement in the prosthesis to some degree [2].

In the present article, a tick-tock pin (hair pin) was incorporated in the distal inter-phalangeal joint to simulate some movements of the natural distal inter-phalangeal joint in the artificial silicone finger prosthesis.

## Fabrication Procedure

- (1) To maintain a natural appearance, it was decided to record the impression and fabricate the prosthesis with each joint slightly flexed when the patient was in a relaxed position. (Fig 1)
- (2) The patient's hand was lubricated with a thin layer of petrolatum jelly (Vaseline, Hindustan Lever, Mumbai, India). This was to prevent the hydrocolloid impression material from adhering to the surgical site and the tissue surface. A plastic container was selected according to size of the palm and holes were prepared with straight fissure bur(S S White, New Jersey, USA) to retain the impression material in its position. Irreversible hydrocolloid (Tropicalgin; Zhermach Inc, California, USA) was placed over the palmer side first and then the dorsal side. The patient was instructed to keep the hand in resting position.
- (3) After the material set, patient was asked to carry out light movement, and remove the palm from the impression.

---

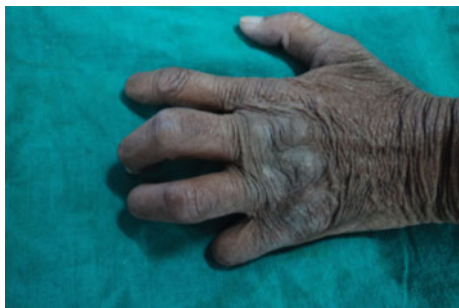Not supported by any organization.  
Not presented before any organization.

---

B. Pattanaik  
Department of Prosthodontics, SMBT Dental College and Hospital, Sangamner, Maharashtra, India

B. Pattanaik (✉)  
Flat No 102, Vaishnavi Apt, Mahatma Nagar, Nashik 422007, Maharashtra, India  
e-mail: bikashdentist@gmail.com

S. Pattanaik  
Department of Prosthodontics, MGV KBH Dental College & Hospital, Nashik, Maharashtra, India



**Fig. 1** Pre-operative photograph of hand with finger defect

- (4) The impression was poured with the dental stone (Kaldstone; Kalabhai Pvt. Ltd. Mumbai, India.) using vibrator (Confident, Bangalore, India) to avoid voids.
- (5) For wax pattern fabrication, impression of another person resembling to patient's lost finger was made, and wax pattern was fabricated by pouring it in wax (Dental Product India, Mumbai, India).
- (6) For maximum versatility, custom acrylic nail was fabricated in heat cure clear acrylic resin (Dental products of India, Mumbai, India). Nail was then incorporated in the wax pattern.
- (7) During try-in, stability and adaptation of the wax pattern was evaluated.
- (8) Wax pattern was flaked horizontally (Fig. 2) to facilitate incorporation of the hair pin inside the prosthesis at a desired position.
- (9) After wax elimination, separating medium (DPI cold mould seal, Dental products of India, Mumbai, India) was applied to the mould along with the custom made nail, so the nail could be detached from silicone prosthesis to achieve extrinsic characterization below nail bed afterwards.
- (10) The hair pin was kept open and clear adhesive tape (Kores International Pvt. Ltd, Mumbai, India) was wrapped around it tightly, to allow opening and closing movement of the hair pin. (Fig 3)
- (11) Intrinsic colors (KT-699, Silicone Coloring Kit, Factor II, Lakeside, USA) were mixed in the silicone

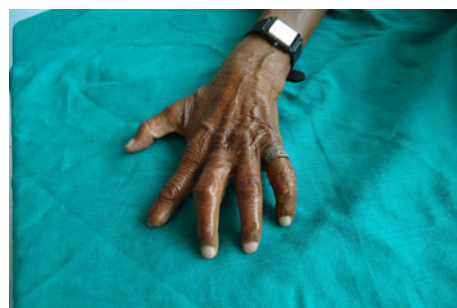


**Fig. 2** Wax pattern of the finger which was flaked



**Fig. 3** Tick-tock hair pin wrapped in the clear adhesive tape in an open (*unlocked*) position

- material (A 2186, Silicone Elastomer, Factor II, Lakeside, USA) to achieve the appropriate characterization. The mold was then packed with silicone material taking care to avoid entrapment of air in it.
- (12) During packing of Silicone material, pin was incorporated such that it remains in centre of the prosthesis at distal interphalangeal joint in open position. Small amount of Silicone material was added over it and flask was closed and processed according to manufacturer's instruction and then prosthesis was retrieved.
- (13) Final color matching was done with extrinsic pigmentation (KT-699, Silicone Coloring Kit, Factor II, Lakeside, USA) in presence of the patient. Coloring was done while the patient was wearing the prosthesis, under a variety of light sources.
- (14) Nail was removed and appropriate characterization was done in the nail bed similar to that of adjacent nail. Custom made nail was then fixed to its position with the help of cyanoacrylate adhesive (Fevi-Kwik, Pidilite industries, Mumbai, India).
- (15) Medical adhesive (Edge adhesive, Factor II, Lakeside, USA) was applied to the base of the prosthesis for retention and to reduce the gap between skin and prosthesis. The patient was advised to wear a decorative split ring (thin and wide) on the prosthetic finger to covers the margin. The thin split ring could be pressed to aid in the retention of the prosthesis. (Figs. 4, 5, 6)



**Fig. 4** Post-operative photograph of hand with finger prosthesis



**Fig. 5** Finger prosthesis showing movement



**Fig. 6** Finger prosthesis showing movement. (*Flex*)

- (16) The patient was instructed regarding wearing of the prosthesis and its maintenance.

## Discussion

The loss of even one finger produces significant deficiencies. Several microsurgical techniques have been developed for the reconstruction of the amputated fingers [3]. Esthetic outcomes may be unsatisfactory in the surgically reconstructed cases. In case of any contra-indications or failure of these surgical methods, digital prosthesis is an option for the restoration [4]. These prostheses can also improve function by restoring the normal shape and length of the finger, protecting the stump, and transferring sensations such as pressure [3, 4].

Most amputees experience phantom limb pain, in the amputated body part [5, 6]. This pain often develops within days after amputation and can last for years [7, 8]. Some authors have noted that scar tissue contained within the silicone prosthesis seems to become more pliant and comfortable after some time [9–11]. The gentle, constant pressure of an elastomer prosthesis can help desensitize and protect the injured tip [12]. Literature speculates that silicone gel improves the hydration of the stratum corneum of immature hypertrophic scars [11].

Surveys on using such artificial hands reveal that 30–50 % of upper extremity amputees do not use their prosthetic hand regularly [13]. The main factors for this are low functionality, poor cosmetic appearance, and low controllability [13].

To strengthen the extension and to increase the range of possible functions, a pliable wire insert is advocated [2]. A pliable wire allows some change in curvature for typing, writing and other similar functions. The results would be better if the prosthesis could be retained in its position so as to carry out functions like holding a glass or a pen. However, after bending for several times, wire may break due to metal fatigue. Therefore an attachment is required which should not break even after repeated movements. One of the solutions to this problem can be achieved with a tick-tock hair pin which is cheap and easily available in the market. It can be bend and retained in one position out of two possible positions (opened and closed positions). The same mechanism is used in light switches and also in some toys (Barbie's knee joint).

Care must be exercised during incorporation of the hair pin in the prosthesis. If it is incorporated in a closed position, it will not be able to open-up as the silicone materials would close the space, thereby not allowing movement of the prosthesis. Therefore pin is to be wrapped in a clear adhesive tape when pin is in an open position. This prevents the silicone material to occupy the space needed for movement of the pin. Patient can bend his joint by applying force against any hard surface or with other hand.

The superb elasticity of silicone elastomer, combined with the intimate fit and a decorative ring on the prosthetic finger aid in retention of the prosthesis beside it covers the margin and camouflages the base of the prosthesis. If the remaining finger stump is too short for retention, a double ring has been advised [2]. In this case a *thin wide split ring* was given. Advantage of the split ring is that it could be pressed to aid in the retention of the prosthesis. Acrylic fingernails are preferred to silicone fingernails [2].

*Osseointegrated dental implants* have been used to retain prostheses [3, 4, 14–16]. Retention is better than the retention obtained by the medical grade adhesives. But Implant treatment is more expensive. In recent decades, much research effort has been focused on the development of more functional artificial hands. The most technologically advanced prostheses are *myoelectric* ones. Robotic knowledge has been applied to improve some of the basic components of prosthetic hands such as the overall dexterity, electromyographic (EMG) recording, and the sensing ability of the device [17]. Main disadvantage of these prostheses is cost and less esthetic. Prostheses, particularly for patients in developing countries, should exhibit functionality at a minimum cost, durability, simplicity of repair, adaptability to local materials, and cultural acceptability [18].

## Conclusion

Functional disability can be overcome to some extent by use of a tick-tock pin (hair pin) incorporated in the joint to replicate some movements of the natural joint in the artificial silicone finger prosthesis. *Advantages* of this method are that it is *inexpensive*, the attachment is *easily available* and it can improve functional ability of the patient to some degrees in *gripping, striking* activities like typing, playing key-board. Moreover, it gives a psychological advantage and the movement of the prosthesis *can be retained in its position* till the patient desires. *Disadvantage* of this technique is that *only two movements*, flexion and extension at its maximum limit are possible. This technique does not help in achieving all ranges of movement. Further, effect of incorporating a hair pin on the strength of the silicone needs to be evaluated.

## References

- Pillet J (1981) The aesthetic hand prosthesis. *Ortho Clin North Am* 12:961–970
- Michael JW, Buckner H (1994) Options for finger prostheses. *J Prosthet Orthot* 6:10–19
- Aydin C, Karakoca S, Yilmaz H (2007) Implant-retained digital prostheses with custom-designed attachments: a clinical report. *J Prosthet Dent* 97:191–195
- Sierakowski A, Watts C, Thomas K, Elliot D (2011) Longterm outcomes of osseointegrated digital prostheses for proximal amputations. *J Hand Surg Eur* 36:116–125
- Kooijman CM, Dijkstra PU, Geertzen JHB, Elzinga A, van der Schans CP (2000) Phantom pain and phantom sensations in upper limb amputees: an epidemiological study. *Pain* 87:33–41
- Rayegani SM, Aryanmehr A, Soroosh MR, Baghbani M (2010) Phantom pain, phantom sensation, and spine pain in bilateral lower limb amputees: results of a national survey of Iraq–Iran war victims' health status. *J Prosthet Orthot* 22:162–165
- Ephraim PL, Wegener ST, MacKenzie EJ, Dillingham TR, Pezzin LE (2005) Phantom pain, residual limb pain, and back pain in amputees: results of a national survey. *Arch Phys Med Rehabil* 86:1910–1919
- Hunter JP, Katz J, Davis KD (2008) Stability of phantom limb phenomena after upper limb amputation: a longitudinal study. *Neuroscience* 156:939–949
- Ohmori S (1988) Effectiveness of silastic sheet coverage in the treatment of scar kebid. *Aesthetic Plast Surg* 12:95–99
- Wessling N, Ehleben CM, Chapman V (1985) Evidence that use of a silicone sheet increases range-of-motion over burn wound contractures. *J Burn Care Rehabil* 6:503–505
- Burkhardt A, Weitz J (1990) Oncologic applications for silicone gel sheets in soft-tissue contractures. *Am J Occup Ther* 45:460–462
- Livingstone DP (1988) The D-Z stump protector. *Am J Occup Ther* 42:185–187
- Atkins DJ, Heard DCY, Donovan WH (1996) Epidemiologic overview of individuals with upper limb loss and their reported research priorities. *J Prosthet Orthot* 8:2–11
- Doppen P, Solomons M, Kritzing S (2009) Osseointegrated finger prostheses. *J Hand Surg Eur* 34:29–34
- Manurangsee P, Isariyawut C, Chatuthong V, Mekraksawanit S (2000) Osseointegrated finger prosthesis: an alternative method for finger reconstruction. *J Hand Surg Am* 25:86–92
- Lundborg G, Brnemark PI, Rosén B (1996) Osseointegrated thumb prostheses: a concept for fixation of digit prosthetic devices. *J Hand Surg Am* 21:216–221
- Cipriani C, Controzzi M, Carrozza MC (2011) The Smart hand transradial prosthesis. *J Neuroeng Rehabil* 22(8):29
- Sitek AJ, Yamaguchi GT, DE Herring et al (2004) Development of an inexpensive upper-extremity prosthesis for use in developing countries. *J Prosthet Orthot* 16:94–102