

Treatment Using Functionally Fixed Prosthesis: A Case Report

Sumi Chandra · Ajay Singh ·
Himanshu Gupta · Chetan Chandra

Received: 2 March 2012 / Accepted: 13 January 2013 / Published online: 5 February 2013
© Indian Prosthodontic Society 2013

Abstract Most dental practitioners as well as their patients prefer to have fixed rather than removable prosthesis. However, there are many clinical situations that prohibit the use of the fixed treatment modality. These clinical cases can vary from, simply not having the proper number of healthy teeth and/or implants to, the esthetically challenging cases of high smile lines and severe loss of alveolar support. The approach of using a traditional removable prosthesis in these situations has always been met with severe compromises. The functionally fixed restoration is a third modality of treatment that can solve many of the problems of the removable restoration and at the same time provide the same comfort and success of the fixed prosthesis. This restoration has a pontic assembly that is removed by the patient for periodontal maintenance. This article presents a case report which describes a technique for treatment of partially edentulous maxilla with severe loss of alveolar support using a fixed removable prosthesis/Andrew's bridge.

Keywords Severe loss of alveolar support · Andrew's bridge · Removable pontic assembly · High smile line

Introduction

The functionally fixed restoration can meet the needs of the patients in many clinical situations in which the fixed and/or

removable modalities cannot be used. The functionally fixed restoration can provide the proper esthetics and comfort for a patient with a lack of severe alveolar support coupled with a high smile line. It can also create palateless prosthesis when there is not enough natural teeth and/or implant support for a fixed restoration [1]. It acts as a fixed prosthesis from a phonetic, esthetic, and masticatory perspective. The major difference between a fixed and a functionally fixed prosthesis is, that with the latter, the pontics can be removed by the patient for hygienic reasons [2].

The functionally fixed prosthesis incorporates the use of Andrews bars and sleeves. These attachments can be used as a single bar and sleeve, as well as a double bar with a corresponding sleeve.

Case Report

A 28-year-old female patient reported to the Outpatient Post Graduate Department of Prosthodontics, Sardar Patel Post Graduate Institute of Dental and Medical Sciences, Lucknow, with the chief complaint of faulty fixed prosthesis in the upper front region (Fig. 1). Dental history revealed that she had lost her teeth due to trauma 4 years back and subsequently the fixed partial denture was fabricated. On the removal of the faulty prosthesis, a thorough clinical examination was made to formulate a proper treatment plan. The intra-oral examination revealed grade III mobility in relation to numbers 14, 23 and 24 and were advised for extraction. The Dentascan of the region revealed inadequate bone width (~4 mm) ruling out implant supported prosthesis. Conventional fixed prosthesis or interim removable partial denture were ruled out because of very long span and lack of vestibular depth respectively. So, finally anterior segment alveolectomy and

S. Chandra (✉) · A. Singh · H. Gupta
Department of Prosthodontics, Sardar Patel Post Graduate
Institute of Dental and Medical Sciences, Lucknow,
Uttar Pradesh, India
e-mail: drsumichandra@gmail.com

C. Chandra
Department of Periodontics, Sardar Patel Post Graduate Institute
of Dental and Medical Sciences, Lucknow, Uttar Pradesh, India

then a functionally fixed prosthesis/Andrew's bridge system was proposed as implant supported prosthesis was ruled out.

On intra-oral examination of the patient it was observed that when the patient occluded her teeth then there was limited space left between the mandibular incisors and the crest of maxillary arch. Thus in order to replace the maxillary anterior teeth some space had to be created. A surgical stent was fabricated indicating the amount of bone reduction required in both anterior and crestal region (Fig. 2). In consultation with a Periodontist a full thickness flap was raised and osteoplasty was done with the help of surgical drill mounted on a physiodispensor (Fig. 3). The flaps were sutured back. After the procedure the stent was again placed which protected the wound during healing. The surgical site took about 4 weeks to heal after which the prosthetic aspect was planned (Fig. 4).

Andrew's bridge was planned in relation to teeth nos. 13, 14, 15, 25, 26 with a cast bar between 13 and 25. Tooth preparations and impression was made using addition silicone rubber base impression material (Aquasil, Dentsply). The maxillary and mandibular casts were mounted on a semi-adjustable articulator (Whip mix) using centric and protrusive records and programming of the articulator was done. The wax pattern was fabricated and a prefabricated Dolder bar (Alpha bio) molded in the form of the arch was attached to the wax pattern in relation to tooth no. 13 and 25 (Fig. 5). The bar was positioned such that it provided a clearance of 2 mm between the bar and the tissue. Then the patterns were sprued and casted. A coping trial along with the cast bar was done (Fig. 6). Porcelain was fired and the fixed restorations were luted with resin cement (RelyX U 100) along with the bar (Fig. 7). Another impression with alginate was made, a trial denture base fabricated. Thereafter, teeth arrangement for acrylic pontics using shade A2 (Cosmo) was done. Final try in (Fig. 8) was done for esthetics, phonetics and occlusion. After this, the flange portion was processed using heat cure acrylic resin (Trevlon, Dentsply). The flange was then attached to the bar using plastic clips which were picked up using self cure acrylic resin, after blocking the portion beneath the bar with putty

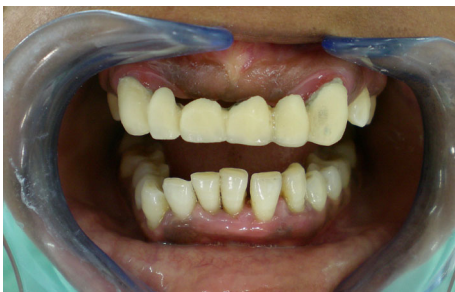

Fig. 1 Pre operative view

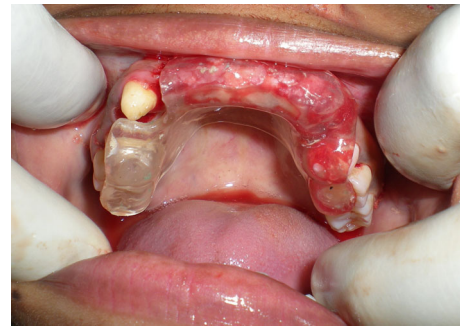

Fig. 2 Surgical stent

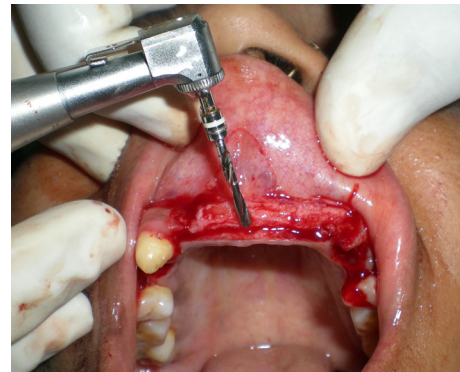


Fig. 3 Osseous recontouring using physiodispensor

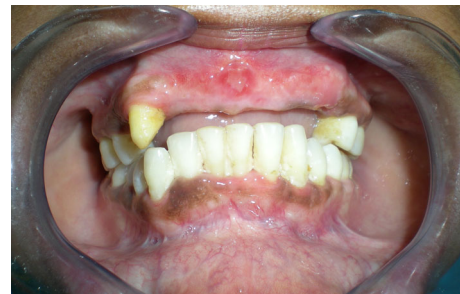

Fig. 4 Post surgical view

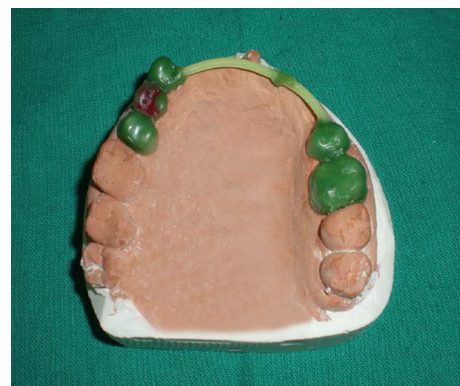


Fig. 5 Wax up with prefabricated Andrew's bar

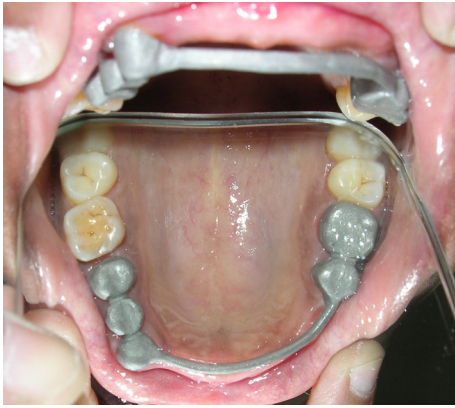


Fig. 6 Coping trial

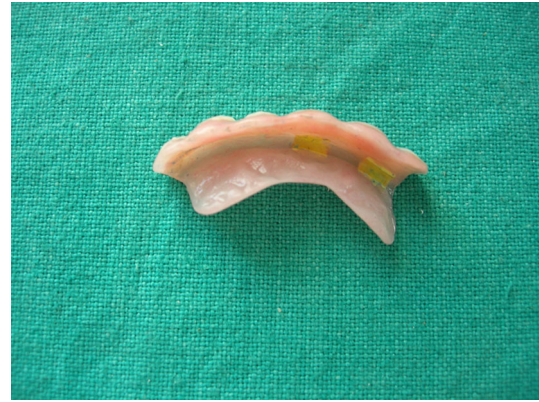

Fig. 9 Clips picked in fixed removable partial denture

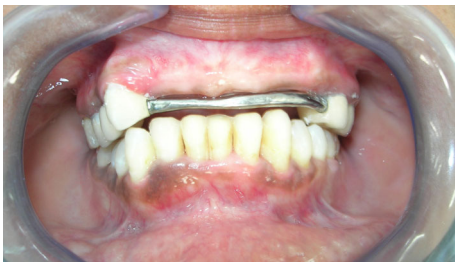

Fig. 7 Cementation of Andrews bar and PFM crowns irt 25, 26 and PFM FPD irt 13, 14, 15

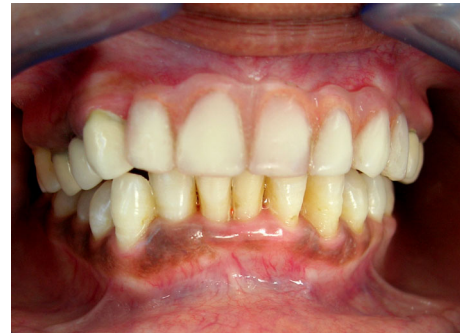

Fig. 10 (Frontal view) Post operative view showing fixed removable partial denture

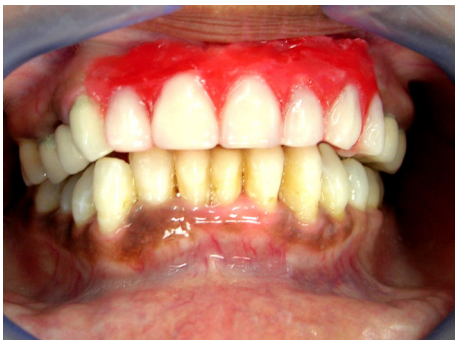

Fig. 8 Final try-in

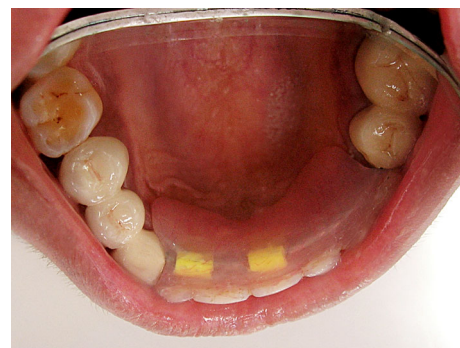


Fig. 11 (Occlusal view) Post operative view showing fixed removable partial denture

(Figs. 9, 10 and 11). Finally, instructions were given to the patient regarding the easy removal and insertion of the prosthesis and maintenance of oral hygiene. The patient was kept on recall for a period of 6 months during which patient exhibited a good acceptance both functionally and esthetically.

Discussion

Compared to the conventional removable partial denture, the fixed-removable partial denture is more stable [3]. The restoration has a fixed as well as a functionally fixed

component. The pontics are relatively immobile, and are not depressable from the forces of occlusion. Only a direct, deliberate, precise action in the planned path of removal removes the pontics from the fixed permanent section containing the specialized bar [4].

Andrew's bridge/functionally fixed prosthesis is indicated for [5]:

1. In cases involving extensive alveolar bone and tissue loss.

2. Patients whose residual ridge has a relationship to the opposing dentition that would prohibit the esthetic placement of the pontics of a fixed partial denture.
3. Patients requiring diastema to harmonize the natural dentition.

Compared to a conventional fixed partial denture, the pontic teeth are arranged during the esthetic try-in appointment [6]. The flange of the pontic assembly is almost eliminated or contoured depending on the given clinical situation to improve comfort, esthetics, phonetics and to resist possible torque during function. Another favourable criterion of the Andrew's bar system is that it can be removed by the patient for hygienic access [7]. The concept of the Andrew's bar system can also be utilized with dental implants. In some cases the Andrew's bar system is superior to the implant-supported fixed partial denture and other techniques for implant overdentures [8].

The only failures reported in the literature in the bar were due to inadequate soldering but they were eliminated by casting the retainers directly to the bar.

Conclusion

Fixed removable partial dentures are particularly indicated for patients with extensive supportive tissue loss and when the alignment of the opposing arches and/or esthetic arch position of the replacement teeth creates difficulties. The fixed-removable modality of treatments may not always

provide the answer to all of the most challenging prosthetic cases but gives the dentists one more alternative in helping to fulfil all the patients growing expectations. The functionally fixed restoration should be a part of all restorative dentists' armamentarium.

Acknowledgments The authors would like to thank Mr. Anurag Singh (Chairman), Dr. Snehalata Chaudhary (Secretary) and Dr. Praveen Mehrotra (Principal) of the college (SPPGIDMS, Lucknow) for their contribution and support in this case report.

References

1. Mueninghoff KA, Johnson MH (1982) Fixed-removable partial denture. *J Prosthet Dent* 48(5):547–550
2. Cheatman J, Newland R, Radentz W, O'Brien R (1984) The fixed removable partial denture: report of a case. *J Am Dent Assoc* 109(1):57–59
3. Donovan TE, Derbabian K, Kaneko L et al (2001) Esthetic considerations in removable prosthodontics. *J Esthet Restor Dent* 13(4):241–253
4. Berson PJ (2002) The functionally fixed restoration: a third modality of treatment. *Compend Contin Educ Dent*. 23(2): 157–162
5. Everhart RJ, Cavazos E Jr (1983) Evaluation of a fixed-removable partial denture. *J Prosthet Dent* 50(2):180–184
6. Andrews JA, Biggs WE (1999) The Andrews bar-and-sleeve-retained bridge: a clinical report. *Dent Today* 18(4):94–99
7. Andrews JA (1976) The Andrews bridge: a clinical guide. The Institute of Cosmetic Dentistry, Covington, pp 1–99
8. Walid MS (1995) Bone anchored Andrew's bar system a prosthetic alternative. *Cairo Dent J* 11(1):11–15