

Tooth Supported Overdenture Retained with Custom Attachments: A Case Report

Siddharth Bansal · Meena A. Aras ·
Vidya Chitre

Received: 5 August 2013 / Accepted: 27 November 2013 / Published online: 12 December 2013
© Indian Prosthodontic Society 2013

Abstract Overdenture is a favored treatment modality for elderly patients with few remaining teeth. Roots maintained under the denture base preserve the alveolar ridge, provide sensory feedback and improve the stability of the dentures. Furthermore, the use of copings and precision attachments on the remaining teeth enhances the retention of the denture. This clinical report describes a novel method of fabricating a tooth supported overdenture retained with custom made ball attachments using orthodontic separators as a female component. Customized ball attachments with orthodontic separators are a simple and cost effective alternative treatment to the use of prefabricated attachments for enhancing the retention of tooth supported overdentures.

Keywords Overdenture · Custom ball attachments · Direct–indirect method · Custom post patterns · Orthodontic separators

Introduction

Overdenture treatment uses a removable complete denture that overlies retained teeth, tooth roots, or dental implants. This treatment is not a new concept and practitioners have successfully employed existing tooth structures or retained roots to assist with complete denture treatment for more than a century [1, 2]. The presence of a healthy periodontal ligament maintains alveolar ridge morphology, whereas a diseased periodontal ligament, or its absence, is associated

with variable but inevitable time-dependent reduction in residual ridge dimensions [3].

To avoid this, two or more, coronally modified or restored retained teeth abutments are frequently endodontically prepared and are used as abutments for an overdenture. The objective is to distribute stress concentration between retained abutments and denture-supporting soft tissues [4, 5]. Retained root abutments can give better retention, support, and stability to an overdenture and also provide proprioception which would otherwise be lost with conventional denture treatment.

Attachments may not be used by many dental professionals for reasons such as cost and reluctance to grasp the intricacies of their indications and applications. An attachment retained dental prosthesis can improve patient esthetics and facilitate function [6–8]. Implant retained prosthesis is an option but is sometimes not possible due to insufficient amount of bone or economic reasons.

Case Report

A 72-year-old male patient reported to the Department of Prosthodontics, Goa Dental College and Hospital with the chief complaint of difficulty in chewing due to missing teeth. There was no relevant medical history affecting prosthodontic treatment. Intraoral examination revealed well formed maxillary and mandibular ridges in class I ridge relationship (Fig. 1). Only 33 and 43 were present in the mandibular arch and radiographic examination revealed good bone support and long roots. The different treatment options available for this patient's mandibular arch were—extraction of the remaining teeth followed by conventional complete denture, implant supported overdenture and tooth supported overdenture.

S. Bansal (✉) · M. A. Aras · V. Chitre
Department of Prosthodontics, Goa Dental College and Hospital,
Bambolim, Panaji 403202, Goa, India
e-mail: siddharthbansal42@gmail.com

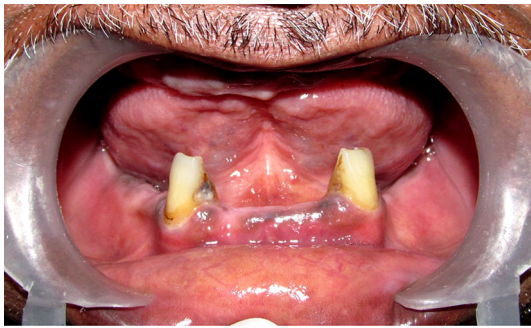


Fig. 1 Intraoral frontal view showing edentulous maxillary and mandibular ridge with 33 and 43 teeth

The patient rejected the option of an implant retained prosthesis because of the need for additional surgery, the longer duration of treatment phase and related expenditure. It was planned to construct a maxillary complete denture and a mandibular overdenture with extra coronal attachments. An orthopantomogram (OPG) and diagnostic casts were made.

Wax rims were fabricated on diagnostic casts to determine the approximate vertical dimension of occlusion. Vertical dimension recordings were determined by phonetics and esthetics. The diagnostic articulation helped in assessing the available inter-arch space and was found to be adequate. Proposed abutment teeth 33 and 43 were prepared on the diagnostic cast, and the ability to accommodate abutment copings and custom ball attachments was assessed.

After which, it was decided to fabricate a mandibular overdenture with custom ball attachments (male component) with use of orthodontic separators (female component to be placed in denture) for attachment. The treatment plan was presented to the patient and his consent was obtained.

Elective endodontics was carried out with teeth 43 and 33 and they were prepared in a dome-shaped contour and hemi spherically rounded in all dimensions with approximately 3–4 mm projecting just above the gingiva (Fig. 2). Post space was prepared and a direct–indirect method was used for the fabrication of post-coping patterns. Custom post patterns were fabricated directly in the root canal with autopolymerizing resin (Pattern resin, GC Corp, Tokyo, Japan) and a pick-up impression was made using rubber base impression (Aquasil™ Ultra Monophase, DECA, Regular Set–Dentsply, Germany) (Fig. 3). The impression was poured with die stone (Type IV die stone, Ultrarock, Kalabhai Karson Pvt. Ltd., Mumbai, India). The fabrication of the post-coping patterns was completed in the laboratory.

Custom ball attachments made from pattern resin were attached to the copings. Attachment diameter was in

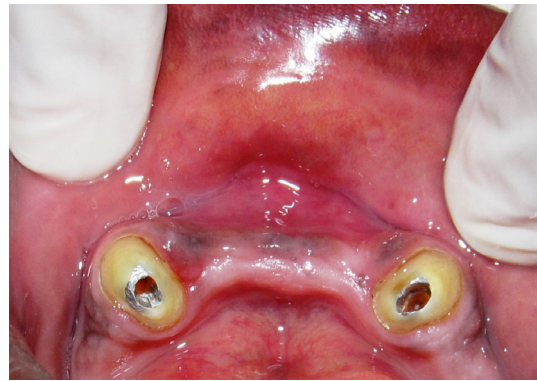

Fig. 2 Tooth preparation done on 33 and 43

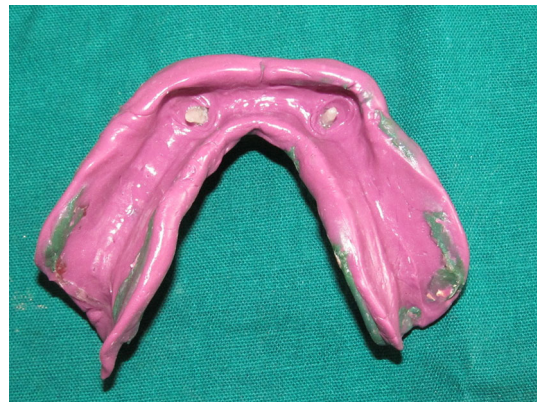

Fig. 3 Custom post patterns picked up in final impression taken with monophase impression material

accordance with the diameter of orthodontic separators (American Orthodontics, North America) to be used. Surveying was done to check for their parallelism. The casting of the patterns was done in Co–Cr alloy using conventional procedures. The copings with attachments were finished and polished and tried in the patient's mouth and the radiographs were taken. Following which, they were luted to the abutment teeth using GIC (GC Fuji PLUS™ GC America) luting cement (Fig. 4).

A primary impression of the lower arch was made with alginate and a special tray was fabricated on the primary cast after block out. Using conventional techniques border moulding was done and secondary impression was made with medium viscosity rubber base material (Aquasil™ Ultra Monophase, DECA Regular Set, Dentsply). Record rims were made and the jaw relationship was recorded. Teeth arrangement was done and a try-in was accomplished. After a satisfactory try-in, the waxed up denture was processed using heat cure acrylic. Once the denture was ready, vent holes were created in the mandibular denture in the space maintained for the attachments. Orthodontic separators were placed over the custom ball

attachments. The separators were picked up by adding autopolymerizing acrylic resin (Fig. 5) in the space while maintaining upper and lower dentures in occlusion. The excess self-cure acrylic that came out of the vent holes was trimmed. Re-polishing was done in the vent hole region. To improve the adhesion of acrylic resin to elastic separator, cyanoacrylate resin was applied at the acrylic-separator junction. The denture was delivered and the patient was given instructions about insertion and removal, eating and speaking as well as maintenance of the denture. Periodic follow-up was carried out (Fig. 6).

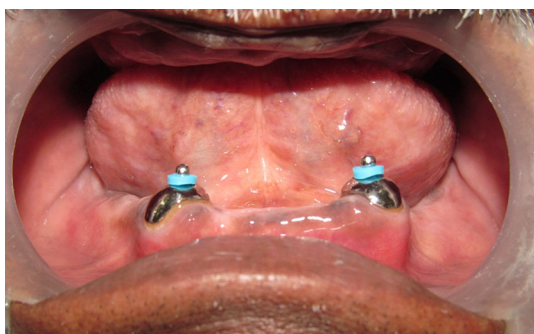


Fig. 4 Intraoral cementation of customized ball attachments

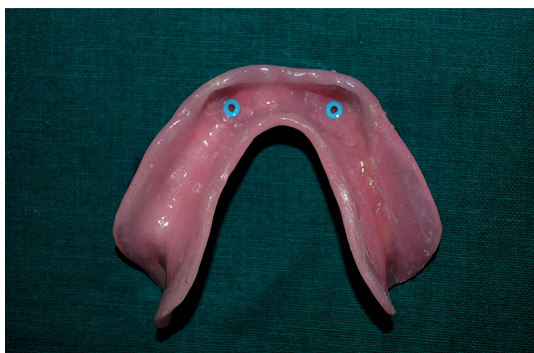

Fig. 5 Acrylised lower denture with orthodontic separators in it

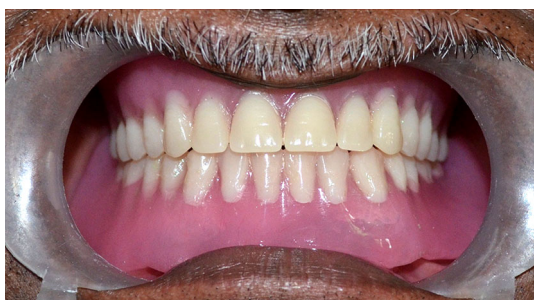

Fig. 6 Intraoral frontal view of the patient with dentures

Discussion

Various types of attachments are available and they have been widely used with removable partial/complete denture prosthesis, segmented fixed prosthesis, and implant supported prosthesis. Yet, no single attachment is perfect for every case, so it is critical that the appropriate attachment should be selected for each individual situation. By analyzing study models and radiographs, the clinician can make several important determinations, each of which will influence the final attachment selection. This is a viable alternative for the patients with some retained teeth and who are not prepared to undergo surgical procedure involved with implant placement.

In this patient treatment, custom made ball attachments (male component) and orthodontic separators (female component) were used as simple and extremely cost effective alternative to the use of prefabricated attachments.

Separators are small elastics which are commonly used during orthodontic treatment to create space between the teeth prior to placement of metal bands. In the past, Teflon discs have been used for the matrix but they are only




Fig. 7 **a** Dontrix gauge used to accurately measure the orthodontic forces exerted by orthodontic elastics on the teeth. **b** Outer diameter of separator 4.23 mm and when it was stretched by 1 mm, it became 5.23 mm

available in the form of solid cylinders, so a central hole has to be made manually by the lab technician according to the diameter of the male component which often leads to dimensional inaccuracy and decreased retention. In comparison, separators are easy to use since a diameter of required dimensions is available and there is no need of cutting a central hole [9].

Ball attachments were made 1 mm larger than the inner diameter of the separators to provide frictional retention. Inner and outer diameter of the separator used was 2.23 and 4.23 mm respectively. When it was stretched by 1 mm, the outer diameter became 5.23 mm and the amount of frictional retentive force applied by the separator on the ball attachment was calculated with the help of an instrument—known as a dontrix gauge (DONG-16 Sybron Dental Specialties, Glendora, CA, USA). A dontrix gauge is an orthodontic appliance that measures elastic forces for different orthodontic movements [10]. It is a spring device with a hook on one end and 16 black engraved markings on its shank (Fig. 7a). Each marking denotes a force of 1 oz and hence the appliance can measure up to 16 oz force in all. It was found to be 10 oz which is equal to 2.7 N (Fig. 7b). The amount of retentive force provided by the prefabricated stud attachments is in the range of 3.2–11 N, which is more than the retentive force provided by these custom ball abutments [11, 12]. Thus, this amount of force is not likely to be detrimental to the abutments and at the same time provides sufficient amount of retention to the denture.

After the prosthesis has been worn for a period of time, retention may decrease as a result of wear on the matrix components of the attachment, in which case the matrix may be easily replaced chair side [13, 14].

A cobalt chromium alloy was used to cast the customized attachments due to its cost, biocompatibility, rare allergies [15–17] and resistance to corrosion [18, 19].

Conclusion

Customized ball attachments with orthodontic separators are a simple and cost effective alternative treatment to the use of prefabricated attachments for enhancing the retention of tooth supported overdentures.

References

1. Fenton AH (1998) The decade of overdentures: 1970–1980. *J Prosthet Dent* 79:31–36
2. Morrow RM, Powell JM, Jameson WS, Jewson CG, Rudd KD (1969) Tooth supported complete dentures: an approach to preventive prosthodontics. *J Prosthet Dent* 21:513–522
3. Burns DR (2000) Mandibular implant overdenture treatment: consensus and controversy. *J Prosthodont* 9:37–46
4. Zarb, Hobrick, Eckert, Jacob (2012) *Prosthodontic treatment for edentulous patients: complete dentures and implant—supported prostheses*, 13th edn. Elsevier, St. Louis, pp 290–295
5. Winkler S (1996) *Essentials of complete denture prosthodontics*, 2nd edn. Ishiyaku EuroAmerica, St. Louis, pp 384–401
6. Burns DR, Ward JE (1990) A review of attachments for removable partial denture design: part 1 classification and selection. *Int J Prosthodont* 3:98–102
7. Burns DR, Ward JE (1990) A review of attachments for removable partial denture design: part 2. Treatment planning and attachment selection. *Int J Prosthodont* 3:169–174
8. Preiskel HW (1973) Precision attachments in dentistry. In: Preiskel HW (ed) *Precision attachments in dentistry*, 3rd edn. Henry Kimpton, London, pp 1–36
9. Nemcovsky CE, Fitzig S, Gross M (1990) Custom overdenture retainer. *J Oral Rehabil* 17:343–350
10. Ratnadeep P, Van Brakel R, Kavita I, Huddleston Slater J, De Putter C, Cune M (2013) A comparative study to evaluate the effect of two different abutment designs on soft tissue healing and stability of mucosal margins. *Clin Oral Impl Res* 24:336–341
11. Rutkunas V, Mizutani H, Takahashi H (2007) Influence of attachment wear on retention of mandibular overdenture. *J Oral Rehabil* 34:41–51
12. Fu CC, Hsu YT (2009) A comparison of retention characteristics in prefabricated and custom-cast dental attachments. *J Prosthodont* 18:388–392
13. Preiskel HW (1996) *Overdentures made easy: a guide to implant and root supported prostheses*, 1st edn. Quintessence, Chicago, pp 184–193
14. Stewart BL, Edwards RO (1983) Retention and wear of precision-type attachments. *J Prosthet Dent* 49:28–34
15. Wiltshire WA, Ferreira MR, Ligthelm AJ (1996) Allergies to dental materials. *Quintessence Int* 27:513–520
16. Takeda T, Ishigami K, Shimada A, Ohki K (1996) A study of discoloration of the gingiva by artificial crowns. *Int J Prosthodont* 9:197–202
17. Khamis E, Seddik M (1995) Corrosion evaluation of recasting non-precious dental alloys. *Int Dent J* 45:209–217
18. Geis-Gerstorf J, Sauer KH, Passler K (1991) Ion release from Ni–Cr–Mo and Co–Cr–Mo casting alloys. *Int J Prosthodont* 4:152–158
19. Brune D (1986) Metal release from dental biomaterials. *Biomaterials* 7:163–175