

Rehabilitation of a Patient with Central Giant Cell Granuloma of Mandible by Iliac Graft, Bone Distraction and Implant Retained Telescopic Prosthesis: a Two Year Follow Up

Vivek Saxena · Anil Kumar Sethuram ·
Manish Mittal

Received: 11 December 2013 / Accepted: 9 March 2014 / Published online: 25 March 2014
© Indian Prosthodontic Society 2014

Abstract Giant cell granulomas of the jaws are lesions that arise either peripherally in periodontal ligament, mucoperiosteum, or centrally in the bone. Histologically, both peripheral and central giant cell granuloma are characterized by the presence of numerous multinucleated giant cells in a prominent fibrous stroma. Traditional treatment has been local curettage, although aggressive sub-types have a high tendency to recur. This case report describes the rehabilitation procedure of a patient with central giant cell granuloma of left side of mandible. Marginal resection of the lesion was done followed by reconstruction of the resected mandible with iliac graft. Distraction of bone was done since there was partial uptake of the fibula graft. Five implants were placed once the distraction was complete. The patient was rehabilitated with implant retained removable telescopic prosthesis.

Keywords Giant cell · Marginal resection · Immediate reconstruction · Distraction osteogenesis · Implant retained telescopic prosthesis

Introduction

Giant cell granuloma is a rare bony lesion in the head and neck region. It was separated out from other jaw lesions by

Jaffe in 1953 [1] and termed giant cell reparative granulomas. It is a non-odontogenic tumor never seen in any other bone of the skeleton. A very similar lesion does occur in the hands and feet [2]. It most commonly affects the Maxilla followed by the Mandible. Although benign, it can locally be destructive. Initially it was believed that the jaw lesions were indeed reparative lesions and would resolve spontaneously [3, 4]. Histologically, the features of central giant cell granuloma (CGCG) are indistinguishable from the brown tumour of hyperparathyroidism and from giant cell lesions of genetic disorders such as cherubism, Noonan syndrome and neurofibromatosis type I [5, 6]. Because of this histological similarity, it has been hypothesized that CGCG may have a genetic aetiology [6]. Surgery is the most accepted method of treating the condition. Excision followed by placement of free bone grafts have been used frequently for mandibular reconstruction. Autogenous bone grafts from the calvarium, rib, ilium, tibia, fibula, scapula and radius have been used [7]. New developments and techniques are tested to eliminate need for bone harvesting from donor site; these include distraction osteogenesis, tissue engineering and modular endoprosthesis for mandibular reconstruction [8, 9]. Distraction osteogenesis is performed in cases of vertical resorption and marginal resections of the edentulous jaws to improve bone volume for dental implant placement. This technique provides a very good quality of the new formed bone with adequate characteristics for implant osseointegration [10]. The case reported here presented with a giant cell lesion that involved the left Mandible. The lesion was surgically excised followed by immediate reconstruction with Autogenous Iliac Crest Graft. After partial uptake of the iliac crest graft the patient was taken up for distraction osteogenesis and rehabilitated with implant retained telescopic prosthesis.

V. Saxena
Oral & Maxillofacial Surgery, CMDC (CC),
Lucknow 900450, India
e-mail: vivek484@gmail.com

A. K. Sethuram (✉) · M. Mittal
CMDC, Lucknow, India
e-mail: anil_virgo_d@yahoo.co.in

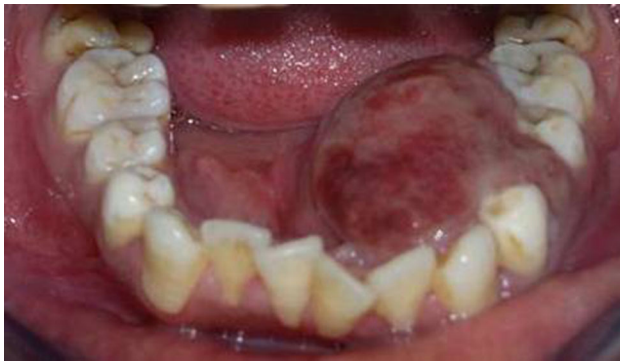

Fig. 1 Pre operative intra oral view of lesion

Case Report

A 24 year old serving soldier reported to the OPD of Command military dental centre, Lucknow (India) with a chief complaint of progressive swelling inside the mouth on the left side since 1 year. The patient took various medications for 10 months in the pretense of it being associated with a tooth infection. He was referred to our tertiary Centre with a provisional diagnosis of Ameloblastoma mandible. No associated history of any trauma with the growth of the lesion was elicited.

Intra-oral examination showed a purple, expansive mass involving left side of the Mandibular Arch extending from tooth No. 31–36 (Fig. 1). The teeth involved in the vicinity of the swelling experienced Grade III mobility. The mass was soft, tender, non pulsatile, non fluctuant & had a tendency to bleed on slight provocation. There was no bruit & the swelling was not associated with any other oral condition like dysphagia, trismus. A CT Scan of midface & mandible revealed an expansile lesion involving Left side of the Mandible causing bilateral cortical expansion and

thinning out of both buccal & lingual cortical plates with perforation (Fig. 2). An incisional biopsy was done under local anaesthesia for histological confirmation of the nature of the lesion. histopathological report was consistent with the clinical impression of central giant cell granuloma.

In view of the availability of an adequate amount of bone at the inferior border of mandible, patient was taken up for surgery under general anaesthesia with a plan of marginal mandibular resection (Fig. 3) & immediate reconstruction with autogenous corticocancellous iliac graft (Fig. 4). Entire lesion was removed along with portions of invaded bone and corresponding teeth No. 41, 31–36. A careful and thorough curettage of the residual bone cavity was performed. Immediate reconstruction with autogenous corticocancellous iliac graft was done and stabilisation of the graft at recipient site was achieved by osteosynthetic metallic plates and screws (Fig. 4). Histological examination of the specimen showed multinucleated giant cells with spindle cells in the background.

Post operative healing was uneventful. After a span of 4 months the patient was evaluated. An Orthopantomogram (OPG) was done to evaluate the uptake of corticocancellous iliac graft (Fig. 5). The OPG showed signs of partial uptake of the corticocancellous iliac graft. The available height of the bone at the resected site was insufficient for implant placement. “In lieu of the above limitations, osteotomy and distraction osteogenesis was performed to increase the height of the available bone” (Figs. 6, 7). The patient was evaluated for 3 months. An OPG was done to check the height of the available bone (Fig. 8). Presurgical planning was done for the placement of implants in the distracted site. Five fixtures (diameter of 4.9 mm, 4.0 mm, two 3.75 mm, 3.3 mm and length 12 mm Pitt Easy Innova Oraltronics Implants) were placed using a two stage approach (Figs. 9, 10). After six months of

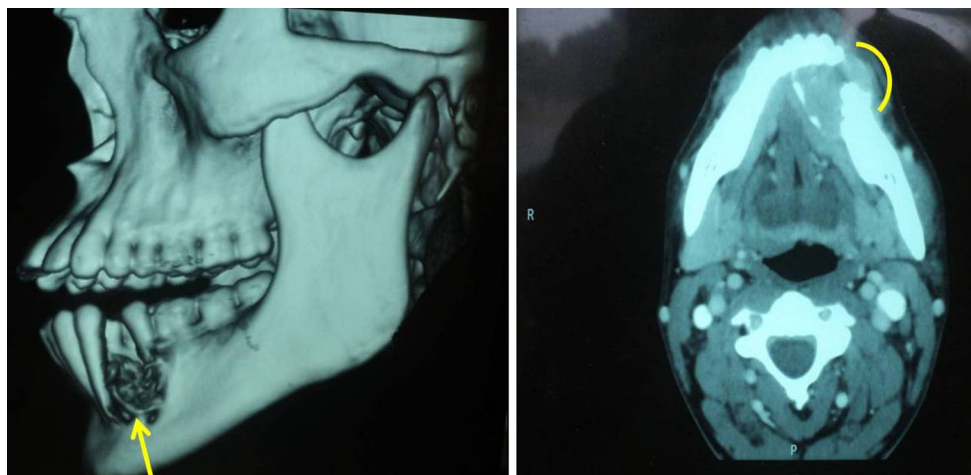


Fig. 2 Pre op axial slice-CT image

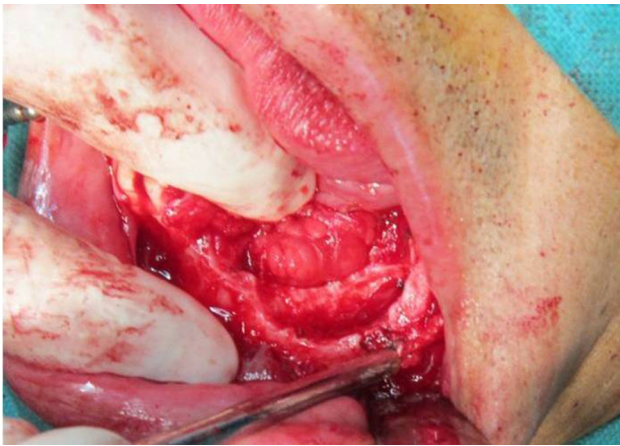


Fig. 3 Marginal mandibular resection

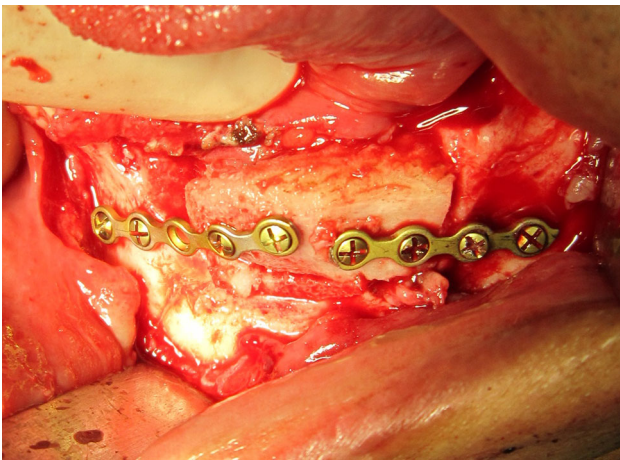


Fig. 4 Iliac graft placement

healing a second stage surgery was performed abutments were secured onto the implants. The abutments were modified intraorally to have approx 5–6 degree taper (Fig. 11). Closed tray impression was made with polyvinyl siloxane putty and light body impression material [Express™ XT VPS impression material, 3M ESPE, Germany]. The abutments were unscrewed from the mouth, fixed to the lab analogs and placed into the impression. The impression was poured using Type V Diestone [Kalstone, Kalabhai, Karson Pvt Ltd, India]. Wax patterns were fabricated over the abutments for fabrication of telescopic copings. The copings were placed on the abutments, wax up and teeth arrangement was done for the fabrication of acrylic removable partial denture. The trial denture was checked in the patient's mouth for occlusion. Implant protected occlusion with only centric contacts and no eccentric contacts were incorporated in the denture. The denture was acrylized with high impact denture base material [Trevalon HI, Dentsply, UK]. The patient was

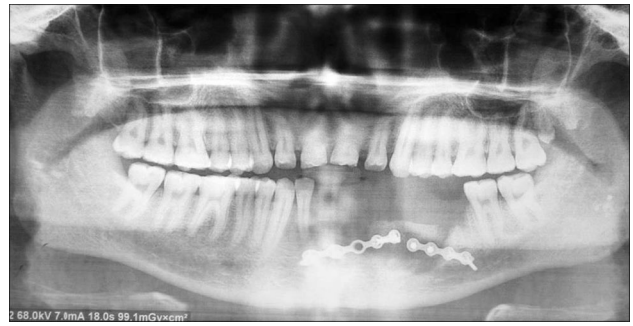

Fig. 5 Post operative OPG after Iliac graft placement

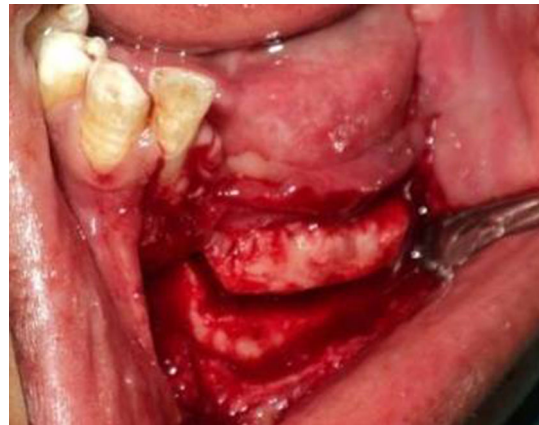

Fig. 6 Distraction osteogenesis

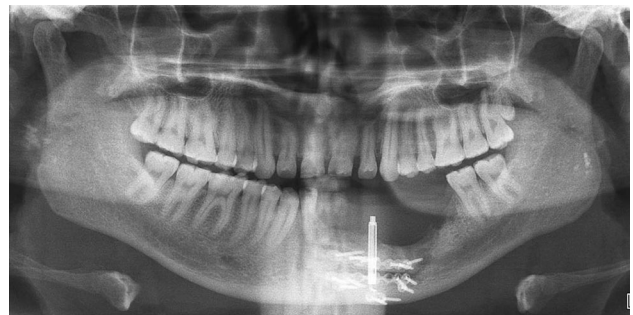

Fig. 7 OPG after distractor placement

rehabilitated with implant retained telescopic prosthesis (Fig. 12). The patient was instructed to clean the denture after every meal and remove the denture from the mouth at night times. Clinical and functional assessments, as well as quality of life and denture satisfaction were evaluated. Follow up at two years confirmed the optimal integration of grafted distracted bone around the implants. Peri-implant soft tissues showed a healthy status.

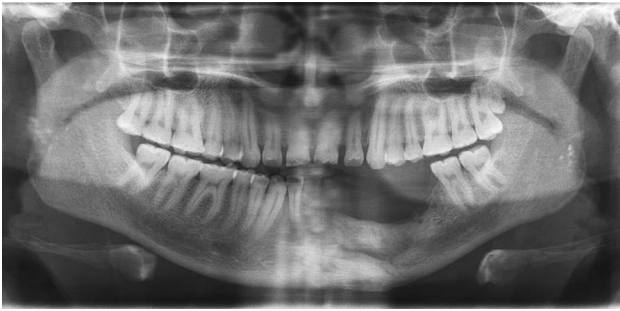

Fig. 8 Post op OPG after distraction

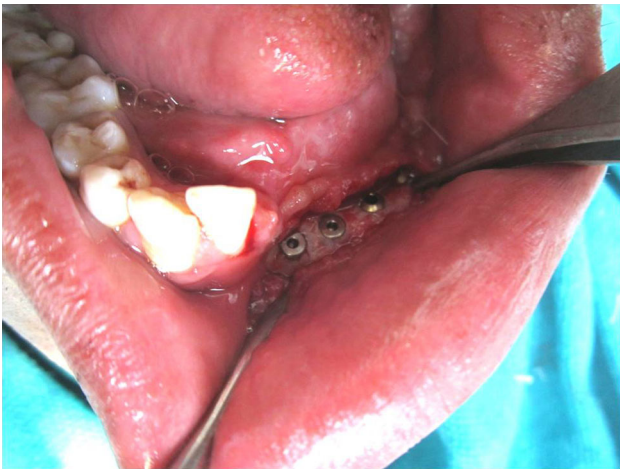

Fig. 9 Implant placement

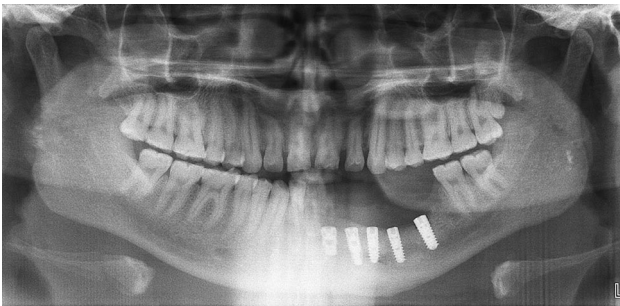


Fig. 10 Post op OPG after implant placement

Discussion

Central giant cell granuloma was first described by Jaffe in 1953. Central giant cell granuloma is a rare disease [11]. Although it can occur at any age, peak incidence is most frequently in the 2nd and 3rd decades and involves the maxilla more than the mandible [12]. It has a strong female sex predilection in a ratio of 2:1 [13]. World Health

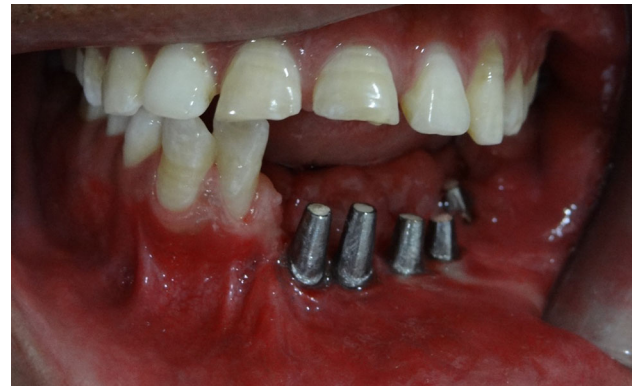
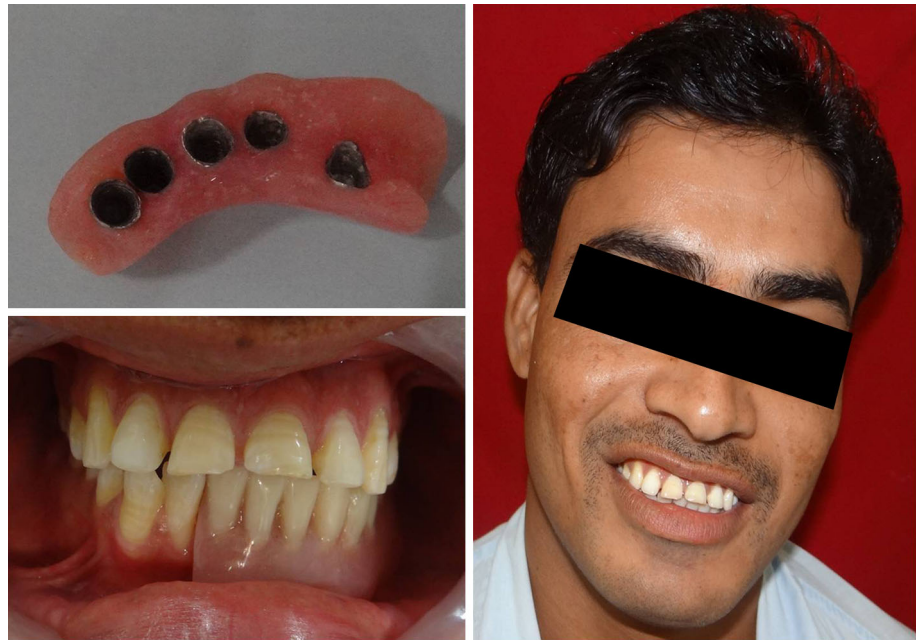
Fig. 11 Abutment placement

Organization defines it as an intra-osseous lesion consisting of cellular fibrous tissue and contains many foci of haemorrhage, aggregations of multinucleated giant cells and occasionally trabeculae of woven bone [14]. Earlier it was thought that CGCG is a reparative lesion as it developed in response to intrabony hemorrhage and inflammation secondary to trauma. Frequently it appears as only a painless swelling, but growth in some cases is so rapid that the lesion may also erode through bone particularly of the alveolar ridge to produce a soft tissue swelling [13]. Mobility and displacement of teeth and root resorption are often observed. Parasthesia is not a common finding even though the lesion is expansive and invasive as it does not usually involve perinuclear sheaths [15]. Despite the fact that the course of the disease is considered benign, there still exist some reports in literature where metastasis has been observed [16]. Furthermore malignant transformations to osteosarcoma or fibrosarcoma have been reported [17]. Waldron & Shafer described the lesion as a reactive response of bone to repeated unidentified trauma; hence it is believed that Class 2 Division 2 malocclusion could have caused the condition due to repeated micro trauma [18, 19]. It has also been suggested that it could be a reaction to some form of hemodynamic disturbance in the bone marrow [12]. Some cases are symptomless and are first detected on routine radiographical examinations. Radiographs show a rounded cyst-like radiolucent area, often faintly loculated or with a soap bubble appearance. Histologically, it is indistinguishable from other giant cell lesions of the bone like cherubism and aneurysmal bone cyst. Giant cell granuloma forms a lobulated mass of proliferative vascular connective tissue packed with giant cells. These giant cells are seen lying in vascular stroma [12]. These giant cells have a patchy distribution and signs of bleeding into the mass and deposits of hemosiderin are frequently seen [13]. Ultra structurally the proliferating cells include spindle-shaped fibroblasts, myofibroblasts and

Fig. 12 Post rehabilitation

inflammatory mononuclear cells [20]. Sparse strands of collagen fibers partly subdivide the lesion which may contain a few trabeculae of osteoid or bone [12]. Surgery is the most accepted and traditional form of treatment. However, tissue removal ranges from simple curettage to bloc resection [21]. Radiation therapy in such a case is contraindicated [19]. There have been cases reported in which radiation treated lesions have undergone malignant transformation [22]. Incidence of recurrence after surgery is 4–20 %, whereas locally aggressive Giant cell lesions have a higher recurrence rate and it usually occurs due to incomplete removal of the tumour [22]. Several surgical techniques have been proposed for removal of more aggressive central Giant cell granuloma and for an aggressive lesion that shows rapid growth and facial swelling, bloc resection and suitable reconstruction of the affected area is considered to be the most appropriate approach [23]. Non-surgical approaches to avoid disfigurement after surgery have been used, including daily systemic doses of Calcitonin and intralesional injection with corticosteroids [21]. Non-surgical treatment is good for slow growing lesions, however, successful treatment of large, rapidly growing lesions is still more likely to be achieved surgically [13]. Marginal resection of the jaws and rehabilitating with iliac crest grafts has been a very good treatment choice [10]. The loss of vertical bone height, which results in an unfavourable crown root ratio, is only one of the several disadvantageous factors. An acceptable result in function and esthetics might be achieved with the combination of inlay and onlay grafts. In this case the situation was addressed with the use of corticocancellous iliac graft followed by distraction

osteogenesis. Recent techniques involving vertical distraction of the corticocancellous graft site for secondary rehabilitation [24, 25] might help minimize the disadvantages of current concepts of masticatory rehabilitation with short dental implants. Implant supported porcelain fused to metal restoration is the treatment of choice for rehabilitation of patients with resected mandible, however at times because of the increased inter ridge distance fixed restorations would not be the choice of treatment since it will unnecessarily lead to fabrication of bulky unaesthetic restorations [24]. In such situations removable partial denture is the best available alternative. In this present case the inter ridge distance was approximately 8 cm because of the resected mandible. Fabrication of a fixed prosthesis would have led to long clinical crowns with increased facio-lingual lateral forces and failure of the prosthesis. Telescopic retained removable partial denture provided adequate retention and decreased the bulk and weight of the prosthesis. Telescopic copings reduce the destructive horizontal and rotational occlusal forces by directing them more axially and less traumatically than other retainers. With telescopic dentures the insertion and removal is much easier and thus increases the prognosis of the partial denture.

Conclusion

The result obtained in this study without the loss of implants at a long term follow up proves the combination of corticocancellous graft placement followed by distraction osteogenesis is a valuable choice for the reconstruction

of maxillofacial defects including severe atrophy of maxilla and mandible. However long term studies would be valuable in attaining more and more success in rehabilitation of patients with compromised ridges.

Conflict of interest None identified.

References

- Jaffe HL (1953) Giant–cell reparative granuloma, traumatic bone cyst and fibrous dysplasia of jaw bones. *Oral Surg Oral Med Oral Pathol* 6:159–175
- Yamaguchi T, Dorfman HD (2001) Giant cell reparative granuloma: a comparative clinicopathologic study of lesions in gnathic and extragnathic sites. *Int J Surg Pathol* 9:189–200
- Bernier JL, Cahn LR (1954) The peripheral giant cell reparative granuloma. *J Am Dent Assoc* 49:141–148
- Bernier JL (1955) The management of oral diseases. Mosby, St Louis, pp 640–641
- J De lange, Vander Akker HP, Vanden Berg H (2007) Central giant cell granuloma of the jaw: a review of the literature with emphasis on therapy options. *Oral Surg Oral Med Oral Pathol Oral Radiol Endod* 104:603–615
- De lange J, Van Maarle MC, Vanden Akker HP, Redeker EJ (2007) DNA analysis of the SH3BP2 gene in patients with aggressive central giant cell granuloma. *Br J Oral Maxillofac Surg* 45:499–500
- Urken ML, Buchbinder D (1998) Oromandibular Reconstruction. In: Cummings CC (ed) *Otolaryngology head and neck surgery*, 3rd edn. Mosby Year Book Inc, St Louis, pp 1654–1668
- Costantino PD, Johnson CS, Friedman CD, Sissons GA Sr (1995) Bone regeneration within a segmental human mandible defect. A preliminary report. *Am J Otolaryngol* 16:56–65
- Warnke PH, Whiltfang J, Springer I, Acil Y, Bolte H, Kosmahl M et al (2006) Man as living bioreactor: fate of an exogenously prepared customized tissue engineered mandible. *Biomaterials* 27(3):163–167
- Klesper B, Lazar F, Siessegger M, Hidding J, Zoller JE (2002) Vertical distraction osteogenesis of fibula transplants for mandibular reconstruction- A preliminary study. *J Craniomaxillofac Surg* 30:280–285
- Khafif A, Krempf G, Medina JE (2000) Treatment of giant cell granuloma of the maxilla with intralesional injection of steroids. *Head Neck* 22(8):822–825
- Soames JV, Southam JC (1998) *Oral Pathology*, 3rd edn, Oxford University Press, USA, p.312–131
- Cawson RA, Odell EW (2002) *Cawson’s Essentials of Oral Medicine and Pathology*, 7th ed, Churchill Livingstone, London, p.135–136
- Kramer IRH, Pindborg JJ, Shear M (1991) *Histological typing of odontogenic tumors*, 2nd edn. Springer-Verlag, Berlin
- Fechner RE, Stacey EM (1993) *Atlas of tumor pathology; tumors of the bones and joints*. Armed Forces Institute Pathology, Washington, pp 181–182
- Small GS, Rowe NH (1975) A “true giant cell tumor” in the mandible. *J Oral Surg* 33:296–301
- Thompson SH, Bischoff P, Bender S (1983) Central giant cell granuloma of the mandible. *J Oral Maxillofac Surg* 41(11):743–746
- Waldron CA, Shafer WG (1966) The central giant cell reparative granuloma of the jaws. *Am J Clin Pathol* 45(4):437–447
- Shafer WG, Hine MK, Levy BM (1983) *A text book of oral pathology*. WB Saunders Company, Philadelphia, pp 146–149
- Rosai J (1996) *Ackerman’s surgical path*, 8th edn. CV Mosby Co, St. Louis
- Bataineh AB, Al-Khateeb T, Rawashdeh MA (2010) The surgical treatment of central giant cell granuloma of the mandible. *J Oral Maxillofac Surg* 60(7):756–761
- Smith PG, Marrogi AJ, Delfino JJ (1990) Multifocal central giant cell lesions of the maxillofacial skeleton: a case report. *J Oral Maxillofac Surg* 48(3):300–305
- Whitaker SB, Waldron CA (2003) Central giant cell lesions of the jaws. A clinical, radiologic and histopathologic study. *Oral Surg Oral Med Oral Pathol* 75(2):199–208
- Chiapasco M, Brusati R, Galioto S (2000) Distraction Osteogenesis of a fibular revascularized flap for improvement of oral implant positioning in a tumor patient: a case report. *J Oral Maxillofac Surg* 58:1434–1440
- Aronson J, Harrison BH, Stewart CL, Harp JH (1989) The histology of distraction osteogenesis using different external fixators. *Clin Orthop Relat Res* 241:106–116