

## Implant Retained Auricular Prosthesis with a Modified Hader Bar: A Case Report

M. Lovely · Pradeep C. Dathan · Dinesh Gopal ·  
Biji Thomas George · K. Chandrasekharan Nair

Received: 20 May 2012 / Accepted: 13 March 2013 / Published online: 21 March 2013  
© Indian Prosthodontic Society 2013

**Abstract** Auricular prostheses for defects of external ear are retained either by mechanical means or implants. All implant retained prostheses are retained by various means such as bar and clip, magnetic attachments or a combination of bar, clip and magnets. The commonest problem encountered with the bar and clip system is loosening of the clip after 3–4 months. When magnets are used as retaining component they tend to corrode over a period of time. So various alternative retention methods which possess good retentive qualities, ease of reparability and patient friendly were tried. In the present case a newly modified Hader bar design which can act as an additional retentive feature apart from the clip is employed to increase retention. The major advantages in the modified Hader bar system were that only two implants were employed, the additional loops in the Hader bar prevented micro

movements and the retentive acrylic locks were easy to repair if broken. The modified Hader bar has anti-rotational slots which prevents the sliding or rotation of the prosthesis which gave new confidence to the patient who was otherwise worried of inadvertent displacement of the ear prosthesis while playing.

**Keywords** Auricular prostheses · Modified Hader bar design · Craniofacial implants

### Introduction

Auricular defects are seen commonly due to trauma, congenital abnormalities and malignancies [1]. A properly fabricated prosthesis precisely replaces the lost structure and will not draw the attention towards the replaced prosthesis. Good retention of the prosthesis in the facial region is difficult to obtain unless precise lab work and skill in the entire procedure is meticulously followed. Of the various options available for the patient to retain an auricular prostheses the implant retained is the most preferred as the fear of dislodgement leading to embarrassment can be avoided. For implant retained prostheses, magnets and bar and clip are the two types of retention that are commonly employed [2]. The Neodymium-Iron-Boron (NdFeB) magnets of 4 mm × 2 mm are the ones commonly used to attach to the abutments to retain the ear prosthesis. The disadvantage of this system is that a bulky superstructure is needed to enclose the magnetic unit and the magnetic components can deteriorate over a period of time [3]. The other method to retain the prosthesis to the implant is by using bar and clip. In a typical bar and clip, [3] implants are employed as per the planned position and three clips at different angles are recommended to make

---

M. Lovely (✉)  
Department of Prosthodontics, Sree Mookambika Institute  
of Dental Sciences, Kulasekharam, Kanyakumari Dist,  
Tamil Nadu, India  
e-mail: mlovely@gmail.com

P. C. Dathan  
Department of Prosthodontics, Sri Sankara Dental College,  
Varkala, India

D. Gopal  
Department of Oral and Maxillofacial Surgery,  
Al-Azar Dental College, Thodupuzha, India

B. T. George  
Department of General Surgery, Sree Mookambika Institute  
of Medical Sciences, Kulasekharam, Tamil Nadu, India

K. Chandrasekharan Nair  
Department of Prosthodontics, AECS Maaruti College of Dental  
Sciences and Research Centre, Bangalore, India

the prosthesis stable and to improve the fit. Maintenance of hygiene under the bars, bulky over-structure, loosening of the clip over a period of time are the common drawbacks of bar and clip design [4]. Hader bar designs with ERA attachments are also reported to show improved stability with just two implants and a single clip design [5].

No super structure retention device exceeds the life of the implant. Every super structure retention has its own advantages and disadvantages.

### Case Report

A 40-year-old male patient who lost his left ear in a road traffic accident came to us for a fixed auricular prosthesis. He was not willing to use an adhesive or external mechanical attachment to retain the ear prosthesis. Hence a implant retained prosthesis was the only choice.

#### Prosthodontic Procedure for Ear Positioning

The exact positioning of the restored ear prosthesis is determined using these three major aspects:

1. Axis: Line of balance through the long dimension of the ear. (Approximately 20°).
2. Level: The highest part of helix is almost in line with that of the eyebrow and the lowest part of the lobule should be on line at the base of columella or slightly below.
3. Distance from lateral orbital rim is approximately 6.5–7.5 cm.

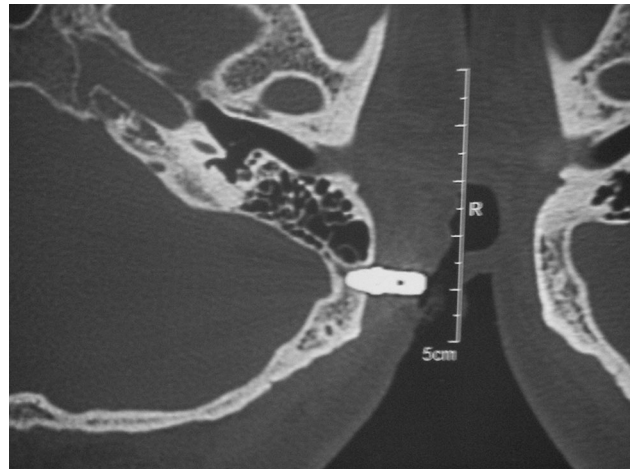
#### Implant Positioning for Auricular Prosthesis

After diagnosis and treatment planning it was decided to place only two implants (Endopore dental implant system) one at 1 o'clock and another at the 4 o'clock position. The distance of the implant from the auditory canal was maintained at 20 mm with each implant placed 15 mm apart [6].

#### Clinical Procedure

UMA Implants of 5.5 mm length and 5 mm width were placed with cover screws. These implants were allowed to osseointegrate for a period of 3 months. After 3 months a CT scan was done to confirm the degree of osseointegration achieved (Fig. 1).

The Implant was surgically exposed and the healing cap was fixed. After a period of 3 weeks, the patient was recalled, the healing cap was removed and transfer copings were fixed.



**Fig. 1** Scan showing osseointegrated implants

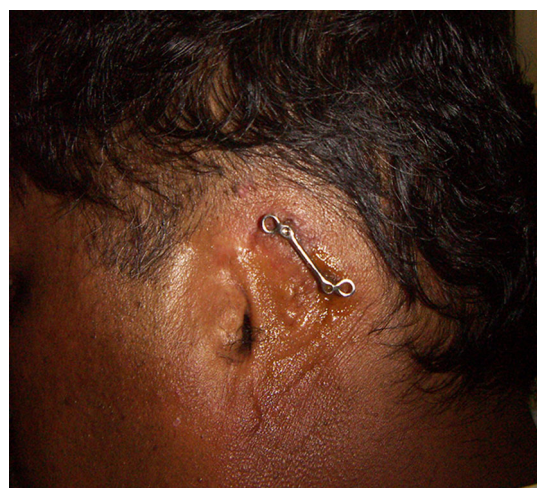An impression of the region was made with rubber base putty and light body addition silicone. A custom made tray (Factor II, Lakeside, USA) was made to accommodate the transfer coping attached to the implants. The transfer coping was picked up in the impression and the implant analogues were fixed.

A master cast was poured in die stone (Kal Rock Kala Bhai) and was sent to the laboratory for the fabrication of the modified Hader bar design.

The modified Hader bar design was cast in Co–Cr alloy (Wirrolloy Bego Dental products).

In this modified Hader-bar system two loops were placed at the terminal ends of the bar and were angulated in opposite directions as shown in (Fig. 2).

The bar is supported on two implants placed at 15 mm distance and it has a total length (including the loops) of 27 mm.



**Fig. 2** Modified Hader-bar system with two loops

The Hader bar with the screws was tried in the patient to evaluate the fit. After the trial the modified Hader bar was sent to the lab for the fabrication of the acrylic superstructure.

The Hader bar was attached with screws and a superstructure was made with a single clip attachment in acrylic with reinforced acrylic tags extending into the loops. The loops at the end of Hader bar aid in holding the acrylic superstructure tags for added retention and to prevent the rotation and sliding of the auricular prosthesis. The entire superstructure was picked in an elastomeric addition silicone impression including the site of the external auditory meatus.

The superstructure was tried on the patient to access the fit and adaptation (Fig. 3).

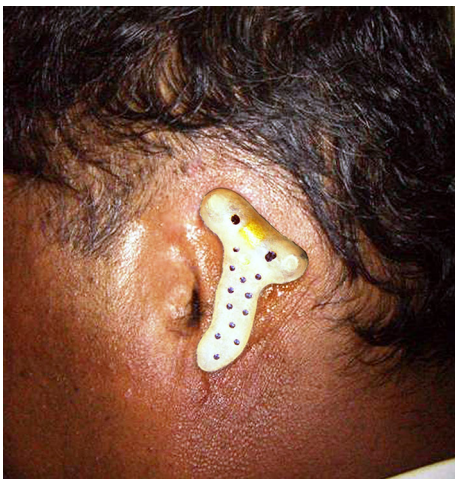A trial wax ear matching the natural ear was made and trial was done over the attached superstructure bar. The wax ear was finalized to match the opposite side natural ear in shape and position (Fig. 4).

Once the trial wax ear was approved by the patient it was invested and dewaxed.

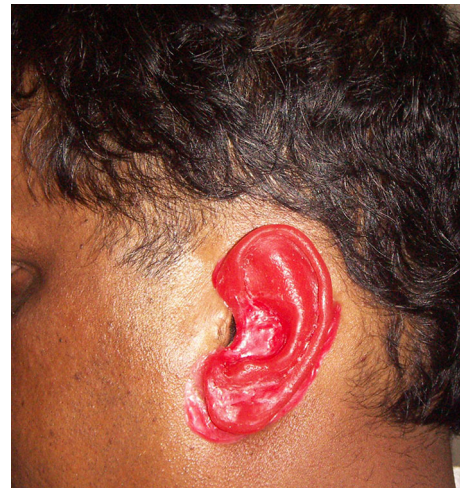After dewaxing the colour matched silicone was packed (Factor II, Lakeside, USA) as per the manufacturer's instructions. On deflasking the final colour matching was done with extrinsic colouring agents, and the final ear prosthesis was matted and finished (Fig. 5).

#### Advantages of Modified Hader Bar System

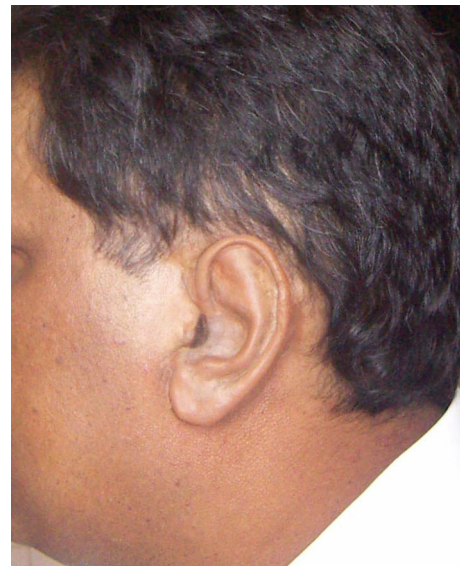1. The modified Hader bar has loops placed in opposite ends this prevents micro-movements and prevents inadvertent displacements in all directions.
2. Apart from a single clip in the centre the acrylic tags fit into the loops adding to retention, stability and support.
3. Even if the clip loosens over a period of time the reinforced acrylic tags provide retention and stability for a long period of time.



**Fig. 3** Super structure tried on patient



**Fig. 4** Completed wax pattern



**Fig. 5** Finished prosthesis

4. Less expensive to repair as the acrylic tags can be repaired easily.
5. The longevity of the clip retention is maintained as the tags function as accessory retentive feature without burdening the clip alone.
6. The entire cost of the superstructure is reduced.
7. The limitations compared to the existing systems as clip loosening are reduced in this system.

#### Discussion

A bar and clip design was popularly employed for implant retained over dentures [7, 8]. The various types of bars in



use were Hader bar, Dolder bar or an individually milled-bar [9, 10].

These bars were later used as retaining components in implant retained maxillofacial prosthesis also. The bar attachments altered in design depending on its location and alignment in relation to the implants used.

Gary and Donovan [11] suggested that a minimum of 2 implants are required for the stability of an auricular prosthesis. These implants were joined by the abutments with a bar (10–15 mm) constructed in a C shaped design. From then on various modifications in bar design were tried by various authors to improve stability.

Khan and Bowden [12] modified a bar super structure that provided the advantages of convenience, and consistent positioning even though one implant was lost. In this design the two segments were soldered together by modifying the gold retention clip allowing the bar superstructure to have slight flexibility leading to better fit. The above modifications required precise lab work and skill in the bar design making.

The present case report with the modified Hader bar design is a simplified bar with no complex design involving lab work yet the tags of acrylic resin within the modified design is repairable, easy and adds retention to the auricular prosthesis preventing micro-movements.

## Conclusion

In our literature search, no report on this type of modified Hader bar with reinforced acrylic tags has been reported. All the reported data are on opposing loops with ERA attachments and gold retained bar and clips which is highly expensive. Moreover, the existing designs for conventional bar and clip had drawbacks like difficulty in maintenance of hygiene under the bars, bulky over-structure and loosening of the clip over a period of time.

The advantages of the modified system include added retention, easy placement by the patient, prevention of

micro movements of the auricular prosthesis and easy reparability. This in turn renders more confidence to the patient to use the implant retained prosthesis.

**Conflict of interest** None.

## References

1. Beumer III J, Marunick MT, Esposito SJ (eds) Maxillofacial rehabilitation: prosthodontic and surgical management of cancer-related, acquired, and congenital defects of the head and neck, 3rd edn. Quintessence Pub., p 276
2. Chung RWC, Siu ASC, Chu FLS, Chow TW (2003) Magnet retained auricular prosthesis with an implant supported composite bar: a clinical report. *J Prosthet Dent* 89:446–449
3. de Sousa AA, Mattos BSC (2008) Magnetic retention and bar-clip attachment for implant-retained auricular prostheses: a comparative analysis. *Int J Prosthodont* 21:233–236
4. Payne AG, Solomons YF (2000) Mandibular implant supported over denture—a prospective evaluation of the burden of prosthodontic maintenance with 3 different attachment systems. *Int J prosthodont* 13:246–253
5. Srithavaj T, Wjitworawong A, Kharel A, Sanohkann S, Santawisuk W (2006) Attachment use in designing a stable facial prosthesis: a new clinical and technical report. *Mahidol Dent J* 26:337–343
6. Reisberg D, Habakuk S (1997) Use of a surgical positioner for bone anchored facial prosthesis. *Int J Oral Maxillofac Implants* 12:376–379
7. Batenburg RH et al (1998) Mandibular overdentures supported by two Branemark, IMZ or ITI implants. A prospective comparative preliminary study: one-year results. *Clin Oral Implants Res* 9(6): 374–383
8. Buser D et al (2002) Long-term stability of osseointegrated implants in augmented bone: a 5-year prospective study in partially edentulous patients. *Int J Periodontics Restorative Dent* 22(2):109–117
9. Branemark PI et al (1977) Osseointegrated implants in the treatment of the edentulous jaw. Experience from a 10-year period. *Scand J Plast Reconstr Surg Suppl* 16:1–132
10. Trakas T et al (2006) Attachment systems for implant retained overdentures: a literature review. *Implant Dent* 15(1):24–34
11. Gary JJ, Donovan M (1993) Retention designs for bone anchored facial prosthesis. *JPD* 70:329–332
12. Khan Z, Bowden M (1994) Modified bar superstructure for an implant retained orbital prosthesis. *JPD* 3:65–67