

## Palatal Identity Appliance: An Identification Tool in Mining Accidents

M. Dhanraj · S. Anand · Padma Ariga ·  
Siddhartha Sasikumar

Received: 12 July 2012 / Accepted: 28 November 2012 / Published online: 15 December 2012  
© Indian Prosthodontic Society 2012

**Abstract** Fatal accidents are rather common in mining endeavours. Establishing the identification of the deceased in mining accidents can be extremely challenging and the palatal identity appliance is a custom made intra oral device with an embedded memory chip with complete data stored in it which can be very useful in such situations to establish the identity of the dead.

**Keywords** Mining accidents · Memory chip · Palatal appliance · Identification of dead

### Introduction

A vista of mother earth's resources has been extracted for human consumption, usage and development through a complex engineering phenomenon known as mining. Mining has immensely contributed to the industrial revolution witnessed in the last two centuries. Nevertheless, the process of mining is very cumbersome and extremely risky in many situations and has claimed several human lives. Identification of the dead in such mining accidents can be very challenging and this palatal identity prosthesis has been developed to more affirmatively address this concern.

### Clinical Procedure for Fabrication of Palatal Identity Appliance

- (1) Impression of maxillary dental arch was made with irreversible hydrocolloid (Tulip, Cavex, Holland)

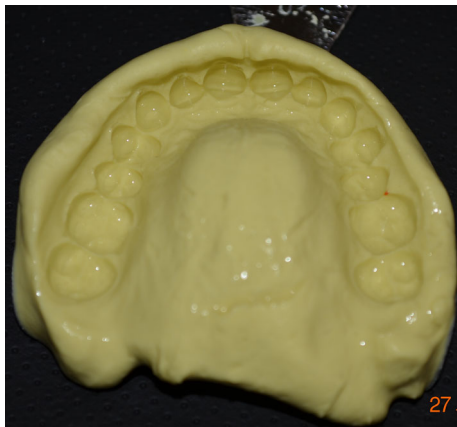(Fig. 1) and poured with Type III dental stone (Kalstone, Kalabhai Karson Pvt Ltd, India) and casts (Fig. 2) were poured.

- (2) A 1 GB memory micro chip (15 mm length × 11 mm width × 1 mm thickness) (Sandisk, India) is selected and fed with all relevant information about the mining personale entering the mines.
- (3) The memory chip is insulated (Fig. 3) with polyvinyl acetylene sheets and sealed.
- (4) A layer of palatal plate is fabricated with clear auto polymerizing resin (Rapid Repair, Dentsply, India) and the memory chip is placed in the posterolateral slopes of the hard palate (Fig. 4) and acrylization is continued to fabricate the palatal prosthesis.
- (5) The prosthesis with the embedded memory chip is retrieved, trimmed, polished (Fig. 5) and tried in the subject's oral cavity (Fig. 6).


### Discussion

Mining accidents occur rather frequently due to various reasons viz. unpredicted natural calamities, untoward weather conditions, equipment malfunction, errors in human handling and communication and the consequences can be very disastrous and many a times the miners have been trapped to death. Rescue operations can be very difficult in mining accidents. The mining debris occludes the entry portal and as a result casualties can increase tremendously due to inhalation of mining debris and trauma to the head and neck and spinal column. Identification of the dead miners can be a very arduous task as the bodies undergo degeneration and decomposition and can be contaminated with debris.

M. Dhanraj (✉) · S. Anand · P. Ariga · S. Sasikumar  
Department of Prosthodontics, Saveetha Dental College,  
No. 162, P.H. Road, Vellanchavadi, Chennai 600077, India  
e-mail: dhanrajmanganapathy@yahoo.co.in



**Fig. 1** Alginate impression of the subject




**Fig. 2** Working cast



**Fig. 3** Insulated memory chip

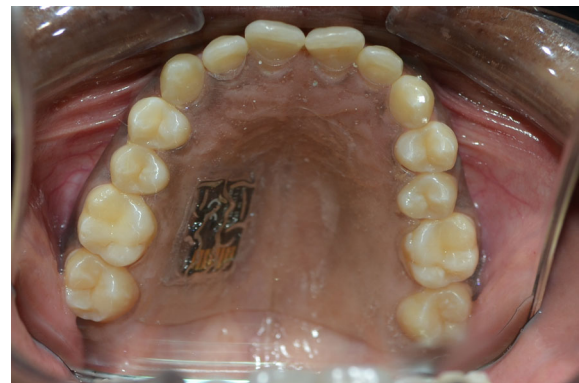Identification of the dead is absolutely essential for civil, legal and social purposes. Common methods of identification of decomposing dead bodies are by dental records [1], palatine rugae records genotyping with personal articles [2], radiographic skull image superimposition [3, 4], radiographic super imposition over ante mortem photographs, and radiologic assessment for evidence of fracture treatment with bone screws and plates if any, peculiar osseous abnormality [5] and dactyloscopy. The dental records and palatine rugae [6] records require ante mortem records and data to verify the postmortem findings and establish identity.



**Fig. 4** Working cast with embedded memory chip



**Fig. 5** Palatal identity appliance



**Fig. 6** Palatal identity appliance in the subjects oral cavity

Radiographic methods require specialized equipment and ante mortem data and the results may not be extremely accurate leading to inferences with varying degrees of doubt. Genotype matching with personal articles can be very time consuming. This palatal identity appliance can be an effective tool in identifying the dead mining personale. The mining personale entering the mines should be instructed to wear this appliance and suitable oral hygiene

maintenance regimen should be insisted. The miners should be instructed to abstain from smoking and pan chewing while wearing the appliance. The appliance should be maintained clean and stored in denture disinfectant solution while not in use. The miners may experience difficulty in phonation initially which would decrease substantially with usage and practice.

The prosthesis is customized and it fits precisely in the palatal vault, so swapping and forging becomes nonexistent. The palatal appliance is resistant to thermal and facial trauma due to its anatomical location in the oral cavity as it is well insulated by the teeth. The microchip embedded is resistant to the cellular fluids released during decomposition as it is insulated by polyvinyl acetylene sheets. The embedded memory chip can be easily retrieved from the prosthesis and processed for information very fast unlike the other methods of identification and accurate details can be extracted from the memory chip. Hence this palatal identity appliance can be employed in mining endeavors and can be very useful in identifying the dead in case of any unfortunate eventuality.

## Conclusion

Palatal identity appliance is a custom made palatal appliance with an embedded memory chip transcribed with all information about the mining personale, can be a very effective method of identifying the dead, in case of fatal mining accidents.

## References

1. Petju M, Suteerayongprasert A, Thongpud R, Hassiri K (2007) Importance of dental records for victim identification following the Indian Ocean tsunami disaster in Thailand. *Public Health* 121(4): 251–257
2. Sasaki M, Shiono H, Fukushima T, Shimizu K (1997) Human identification by genotyping of personal articles. *Forensic Sci Int* 90(1–2):65–75
3. Strauch H, Wirth I, Reisinger W (2002) Human identification by comparison of skull roentgen image. *Arch Kriminol* 210(3–4):101–111
4. Chai DS, Lan YW, Tao C, Gui RJ, Mu YC, Feng JH, Wang WD, Zhu JA (1989) A study on the standard for forensic anthropologic identification of skull-image superimposition. *J Forensic Sci* 34(6): 1343–1356
5. Riepert T, Rittner C, Ulmcke D, Ogbuihi S, Schweden F (1995) Identification of an unknown corpse by means of computed tomography (CT) of the lumbar spine. *J Forensic Sci* 40(1):126–127
6. Muthusubramanian M, Limson KS, Julian R (2005) Analysis of rugae in burn victims and cadavers to simulate rugae identification in cases of incineration and decomposition. *J Forensic Odontostomatol* 23(1):26–29