

Case Report

Prosthetic rehabilitation of large mid-facial defect with magnet-retained silicone prosthesis

Kirti Jajoo Shrivastava, Saurabh Shrivastava¹, Surendra Agarwal², Anjali Bhoyar²

Assistant Professor, Department of Prosthodontics, People's Dental Academy, ¹RKDF Dental College, ²People's College of Dental Sciences, Bhopal, Madhya Pradesh, India

Abstract

Rehabilitation of maxillofacial defect patients is a challenging task. The most common prosthetic treatment problem with such patients is, getting adequate retention, stability, and support. In cases of large maxillofacial defect, movement of the prosthesis is inevitable. The primary objectives in rehabilitating the maxillofacial defect patients are to restore the function of mastication, deglutition, speech, and to achieve normal orofacial appearance. This clinical report describes maxillofacial prosthetic rehabilitation of large midfacial defect including orbit along with its contents, zygoma and soft tissues including half of the nose, cheeks, upper lip of left side, accompanying postsurgical microstomia and orofacial communication, which resulted from severe fungal infection mucormycosis. The defect in this case was restored with magnet retained two piece maxillofacial prosthesis having hollow acrylic resin framework and an overlying silicone facial prosthesis. The retention of prosthesis was further enhanced with the use of spectacles. This type of combination prosthesis enhanced the cosmesis and functional acceptability of prosthesis.

Key Words: Acrylic framework, combination prosthesis, magnets, maxillofacial rehabilitation, midfacial defect, silicone

Address for correspondence:

Dr. Kirti Jajoo Shrivastava, Saurabh Nursing Home, 82-Marwari Road, Near Jumerati Gate, Bhopal - 462 001, Madhya Pradesh, India. E-mail: kirti.jajoo@gmail.com

Received: 13th January, 2015, **Accepted:** 28th May, 2015

INTRODUCTION

The defects in maxillofacial region may result due to certain disease, pathological changes, radiation, burns, trauma or surgical intervention. The case reported in this article is a large facial defect resulted from rare severe fungal infection mucormycosis. The primary objectives in rehabilitating the maxillofacial defect patients are to restore the function of mastication, deglutition, speech, and to achieve normal orofacial appearance.^[1]

Large facial defects are difficult to restore prosthetically due to lack of anatomic undercuts, limited means of retention, mobility of soft tissues, and weight of prosthesis.^[2] Various methods of auxiliary retention include eyeglasses, magnets, adhesives, combinations of the above, and implants.^[1,3] Although osseointegrated implants may provide the most reliable prosthesis retention; extensive size of the defect, poor mucosal quality and minimal bony supporting structures, additional surgeries, expenses would result in poor long-term prognosis,^[4] particularly for this case.

Materials commonly used for fabrication of facial prostheses are acrylic resins, acrylic copolymers, vinyl polymers, polyurethane elastomers, and silicone elastomers, but none of them fulfills all the requirements for a satisfactory prosthesis. However, the advent of silicone has brought us a material that nearly meets the requirements of ideal prosthetic material as outlined by Bulbulian.^[5] This clinical report describes prosthetic

Access this article online	
Quick Response Code:	Website: www.j-ips.org
	DOI: 10.4103/0972-4052.161571

rehabilitation of large midfacial defect with a magnet retained combined two piece acrylic resin-silicone facial prosthesis.

CASE REPORT

A 68-year-old, male patient was referred to Department of Prosthodontics for orofacial rehabilitation. Complete healing of the surgical wound was found after excision of left maxilla including orbit along with its contents, zygoma and soft tissues including half of the nose, cheeks, upper lip of the ipsilateral side [Figure 1a and b]. Mutilation left the patient with restricted mouth opening, orofacial communication resulting in the escape of food and fluids, and thus a nasogastric feeding tube was inserted.

After precise evaluation of the case, the proposed treatment plan was to construct magnet retained two piece combination prosthesis having hollow acrylic resin framework and a silicone facial prosthesis. The rationale behind fabrication of this two piece tissue supported prosthesis was to avoid invasive techniques leading to recurrence of lesion and also to help distribute the weight of prosthesis and enhance retention with magnets and adhesive as mutual means of retention. This treatment plan also had a future perspective of replacement of silicone prosthesis without repetition of acrylic resin framework fabrication, if required.

Procedure

- Impression of the maxillofacial defect and entire face was made first by making Facial moulage. For this the face was boxed with hard baseplate wax (TruWax Baseplate wax, Trubyte; Dentsply International) and then irreversible hydrocolloid impression material (Hydrogum, Zhermack) was applied over the face. The impression was reinforced with fast setting dental plaster (for support during retrieval and pouring of impression) [Figure 2a-c] and working model was obtained

- The working model was then used for fabrication of hollow heat polymerizing polymethyl methacrylate (PMMA) (Trevalon; Dentsply, USA) substructure, the same way as conventional heat cure PMMA hollow bulb obturators are made with the lost salt technique. The technique was followed by packing salt in orbit and malar region in substructure and after curing, salt was removed by making holes in resin framework where magnets were planned to be placed. This led to considerable loss of weight of acrylic framework and also there is no need to fabricate the whole prosthesis again in case of discoloration or damage of the silicone layer as the outer silicone layer can be removed and repacked with the new silicon on the acrylic resin framework if the mold is preserved
- The resin framework obtained was trimmed, finished, and was then adjusted clinically with the aid of pressure indicating paste to allow complete seating on the face. Facial moulage was then made again to pick up the resin framework in alginate impression material (so as to allow maximum adaptation of prosthesis to tissues for retention and to restore facial features in correct alignment during sculpting in wax and later on in final silicone prosthesis) and was poured to obtain a new working model [Figure 3a and b]
- The three Cobalt-Samarium magnets, 2.5 mm in thickness (Jobmasters, Randallstown, MD, USA)^[6] were embedded in acrylic framework [Figure 4]. The counter magnets and modified stock eye prosthesis were then securely positioned with wax on resin framework. The ocular prosthesis was placed into a position that matches the gaze of another normal eye when the patient was directly staring at a point at eye level at least 6 feet away. This was followed by sculpting for the silicone prosthesis with wax. Patient's previous photographs and the references from his first circle relatives were taken as a guide for shaping the wax pattern. The contour of final surface and skin texture was fabricated by carving in lines and

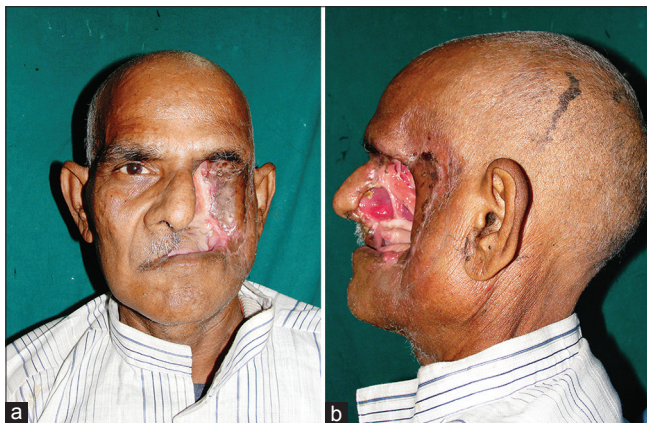

Figure 1: Front (a) and lateral (b) view of healed orofacial defect after surgical excision.

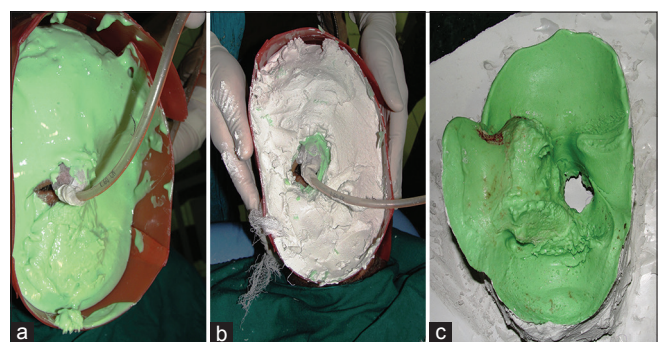


Figure 2: Facial moulage (a) Irreversible hydrocolloid impression material applied over the boxed face. (b) Type II dental plaster applied for support. (c) Facial moulage obtained for support

wrinkles and was evaluated clinically [Figure 5]. After final contouring, acrylic rod was placed on modified stock eye (to prevent its displacement during investing and dewaxing procedures)

- The silicone prosthesis was then fabricated following conventional technique of investing, dewaxing and packing MDX4-4210-base silicone (Dow Corning Corp, Michigan, USA). The wax pattern was flaked using die stone (Ernst Hinrichs GMBH, Goslar, Germany) to form a mold for packing the silicone. Wax elimination was then performed in usual manner. Laminar intrinsic staining was used in packing according to the patient's skin color, using intrinsic stains (KT-699, Silicone Coloring Kit; Factor II, USA) [Figure 6a and b]. The silicone was heat processed for 2 h at 90°C, bench cooled, deflasked, trimmed, and finished [Figure 7].
- The silicone prosthesis obtained was then bonded to the underlying resin framework with medical adhesive type A (Factor II) under vacuum. Polyurethane lining was also applied to the margins to increase the tear resistance of the marginal silicone.^[7] The prosthesis was trial fitted and extrinsically colored with oil pigments (Factor II, Lakeside, USA). A spectacle frame was adhered to the

prosthesis to provide extra retention, and final result was obtained [Figure 8a and b].

The patient was given hygiene instructions for cleaning the prosthesis and was recalled every 6 months. During these visits, the prosthesis was thoroughly cleaned with a disinfectant. The advantages of this prosthesis are that the technique is noninvasive, cost-effective, tissue tolerant, esthetic, comfortable to use, and easy to clean.

DISCUSSION

Large orofacial defects result in serious functional and cosmetic deformity which often has a significant psychological impact on the patient. The patient reported in this article was left mutilated with the loss of left midfacial tissues due to severe fungal infection mucormycosis which had a chance of recurrence even after surgical removal. Thus, to avoid recurrence of lesion and financial constraint of the patient, implant supported prosthesis was not planned for this case. Acceptable

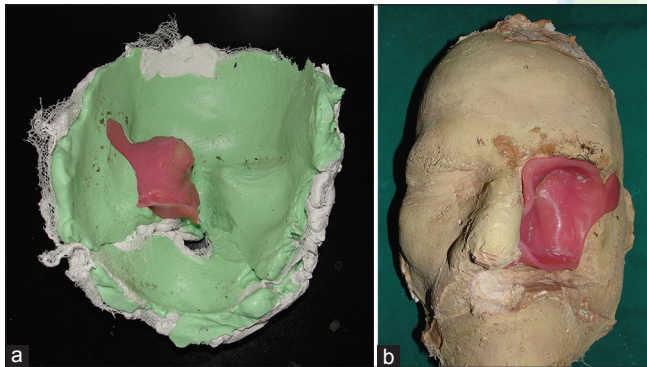


Figure 3: (a) Pick up of acrylic substructure in facial moulage (b) Working model obtained

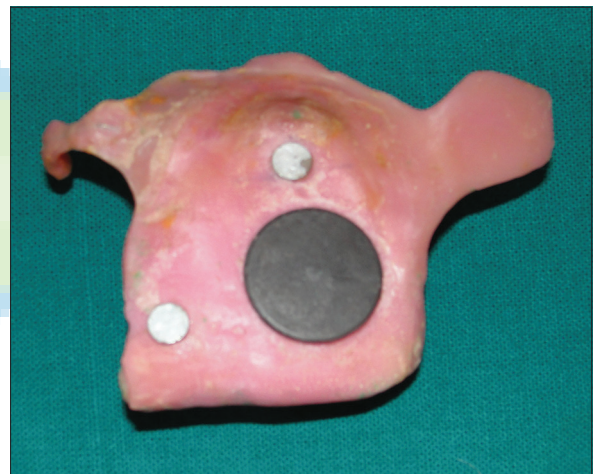

Figure 4: Hollow acrylic substructure with magnets in place

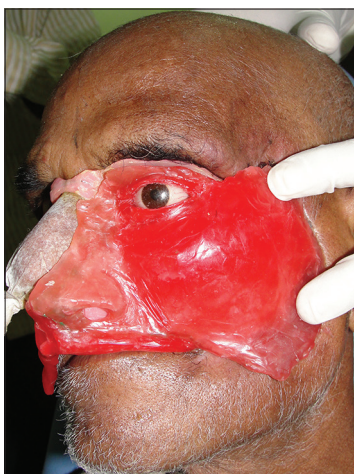

Figure 5: Final sculpted wax pattern



Figure 6: (a) MDX4-4210-base silicone and Silicone Coloring Kit; Factor II, USA (b) Packing of silicone in dewaxed mold

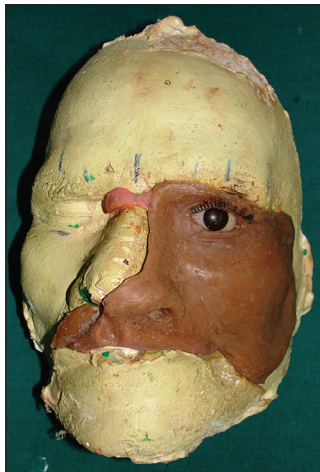

Figure 7: Finished prosthesis

results, however, could be obtained with a tissue supported facial prosthesis. But, retention of such a large prosthesis is difficult, and only with ingenuity and an understanding of the remaining anatomic structures, combination prosthesis that mutually retain one another can be constructed as was done in this case. Various methods of auxiliary retention for facial prostheses which have been described in the literature were used in this case including eyeglasses, tissue undercuts, magnets, adhesives, and combinations of the above.^[1,8-10] In this case retention of prosthesis was further enhanced by making light-weight PMMA hollow resin substructure along with magnets embedded in it to facilitate better mutual retention and also helped in proper alignment of silicone prosthesis without hindering the external appearance. Medical grade silicone adhesive and polyurethane lining also added to retention of the prosthesis. Clinically significant vertical mobility or sinking down of the prosthesis during functional movements was also not found in this case due to the distribution of weight of prosthesis by adhering it with eye glasses and restricted mouth opening. However, several authors have reported different problems with a combination (PMMA and silicone) prosthesis like degradation of the silicone, delamination, reduced marginal integrity, and poor simulation of facial expressions. Problem of degradation of silicone in this case is expected to be minimal since medical grade material and intrinsic stains with layering technique has been used, with virtually no tissue contact except at margins (due to substructure), thus allowing least contact with skin secretions like sweat. The problem of delamination was overcome by bonding processed silicone to the framework with an adhesive under vacuum and increasing marginal strength with polyurethane lining. A 6-month periodic recall appointment was advisable for assessment of the prosthesis (retention, stability, and support) and the supporting tissues.

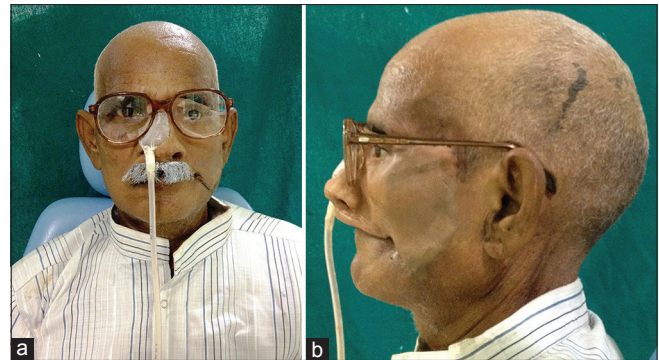

Figure 8: Front (a) and lateral (b) profile view of Final prosthesis

SUMMARY

A patient who has lost his facial tissues due to trauma, infection, or tumor experiences lot of emotional and psychological breakdown similar to that experienced by an amputee. A prosthesis that is lifelike in appearance provides a sense of psychological security to the patient, and the physical wearing comfort becomes a primary prerequisite for the patient. A 68-year-old male patient was referred for facial rehabilitation after surgical excision of left maxilla due to an underlying severe fungal infection mucormycosis. Prosthetic rehabilitation was done with magnet retained two piece prosthesis having hollow acrylic resin framework and a silicone facial prosthesis. This type of combination prosthesis enhanced the cosmesis and functional acceptability of prosthesis. Thus, it can be concluded that prosthetic rehabilitation of large facial defects is a challenging task which requires critical understanding of available anatomic structures and prosthesis designs to achieve maximum retention, stability, and esthetics.

REFERENCES

1. Beumer J, Curtis TA, Firtell DN. Maxillofacial Rehabilitation. Prosthodontic and Surgical Considerations. St. Louis, Toronto: C.V. Mosby Co.; 1979. p. 183-243.
2. Beumer J, Curtis TA, Marunick MT. Maxillofacial Rehabilitation: Prosthodontic and Surgical Considerations. St. Louis: Ishiyaku EuroAmerica; 1996. p. 225-9.
3. Goiato MC, Fernandes AU, dos Santos DM, Barão VA. Positioning magnets on a multiple/sectional maxillofacial prosthesis. J Contemp Dent Pract 2007;8:101-7.
4. Marunick MT, Harrison R, Beumer J 3rd. Prosthodontic rehabilitation of midfacial defects. J Prosthet Dent 1985;54:553-60.
5. Bulbulian AH. Maxillofacial prosthetics: Evolution and practical application in patient rehabilitation. J Prosthet Dent 1965;15:544-69.
6. Sasaki H, Kinouchi Y, Tsutsui H, Yoshida Y, Karv M, Ushita T. Sectional prostheses connected by samarium-cobalt magnets. J Prosthet Dent 1984;52:556-8.
7. Lemon JC, Martin JW, King GE. Modified technique for preparing a polyurethane lining for facial prostheses. J Prosthet Dent 1992;67:228-9.
8. Udagama A. Urethane-lined silicone facial prostheses. J Prosthet Dent 1987;58:351-4.

9. Thomas K. Prosthetic Rehabilitation. London: Quintessence Publishing; 1994. p. 93-103.
10. Dumbrigue HB, Fyler A. Minimizing prosthesis movement in a midfacial defect: A clinical report. J Prosthet Dent 1997;78:341-5.

How to cite this article: Shrivastava KJ, Shrivastava S, Agarwal S, Bhoyar A. Prosthetic rehabilitation of large mid-facial defect with magnet-retained silicone prosthesis. J Indian Prosthodont Soc 2015;15:276-80.

Source of Support: Nil, **Conflict of Interest:** None declared.

