

Case Report

Prosthetic rehabilitation of a mandibular root amputated molar using single crown

Azam Sadat Mostafavi, Seyed Mehran Falahchai

Department of Prosthodontics, Dental Research Center, Faculty of Dentistry, Tehran University of Medical Sciences, Tehran, Iran

Abstract

In teeth with furcation involvement, root amputation is one of the treatment choices. A challenge which a dentist may encounter with is the prosthetic treatment of such teeth when their adjacent teeth are intact. According to the current goal of operative dentistry based on conservative treatment, it would be desirable to do in a manner resulting in minimal damage to the adjacent sound teeth. In the following case report, a step-by-step conservative treatment sequences of a mandibular molar with distal root amputation which not involving surrounding teeth is described. During 18 months follow-up, the results were satisfactory.

Keywords: Furcation involvement, prosthetic rehabilitation, root amputation

Address for correspondence: Dr. Seyed Mehran Falahchai, Department of Prosthodontics, Dental Research Center, Faculty of Dentistry, Tehran University of Medical Sciences, Northern Karegar Street, Tehran 009821, Iran.

E-mail: mehran.falahchai@gmail.com

Received: 28th April, 2017, **Accepted:** 14th August, 2017

INTRODUCTION

Root resection was defined for the first time in 1884. Since that time, reports and studies about this treatment modality have been accomplished. Decision-making about molar teeth with furcation involvement is still a challenge for the clinicians.^[1] There exist several treatment options with different amounts of complexity to maintain such a tooth which indeed require the collaboration of periodontics, endodontic, and restorative dentistry. Choosing the best treatment option is contingent on many factors. The most important factor is the grade of furcation involvement which is an effective factor in the determination of prognosis as well.^[2]

One of the mentioned treatment options is root resective therapy with the aim of preservation as much tooth

structure as possible. There are different resection procedures including root amputation, hemisection, bisection, and radisection.^[3]

Several cases about root resection have been reported. In all of such case reports, fixed dental prosthesis (FDP) was chosen as the treatment of choice. Nowadays, the goal of operative dentistry is to achieve the both esthetic and conservative results. Therefore, in the case of molar root resection, it would be desirable to avoid preparation of the intact tooth adjacent to edentulous space resulted from root resection. In the following report, a step by step treatment sequences of a mandibular molar with distal root amputation which was restored conservatively with a single crown is reported and the essential considerations for using this treatment modality is discussed as well.

Access this article online	
Quick Response Code:	Website: www.j-ips.org
	DOI: 10.4103/jips.jips_121_17

This is an open access article distributed under the terms of the Creative Commons Attribution-NonCommercial-ShareAlike 3.0 License, which allows others to remix, tweak, and build upon the work non-commercially, as long as the author is credited and the new creations are licensed under the identical terms.

For reprints contact: reprints@medknow.com

How to cite this article: Mostafavi AS, Falahchai SM. Prosthetic rehabilitation of a mandibular root amputated molar using single crown. J Indian Prosthodont Soc 2017;17:412-6.

CASE REPORT

A 35-year-old male patient was referred to the Prosthodontics Department of Tehran University of Medical Sciences with a mandibular right first molar subjected to distal root amputation [Figure 1]. The patient's oral hygiene was good, and he insisted to keep his teeth intact. Root canal therapy and an extensive deficient amalgam restoration had been done for the tooth. After consultation with the endodontic department, the accuracy of existing endodontic treatment was verified.

The usual treatment option performed in mandibular root resected teeth is FDP. It has been used in all related cases reported. In this patient, however, right second molar had a minimal composite restoration, and the patient did not tend to the preparation of his sound tooth [Figure 2]. To these reasons and according to the aim of the prosthetic rehabilitation which is the preservation of teeth structure, single crown restoration was considered for him. In the first appointment, diagnostic casts were provided. The extensive amalgam restoration was removed. Preparation of the tooth and root canal was performed. A 5 mm gutta-percha was reserved to apical seal maintenance. Postpattern (Pattern resin LS, GC America, Illinois, USA) was formed [Figure 3] and preparation was accomplished. In the second appointment, the cast post and core was tried in and its seating was verified by a periapical radiograph after cementation (GC Fuji II, GC America, Illinois, USA), refinement of the preparation was done, and occlusal clearance was checked [Figure 4]. The gingival finishing line was shallow chamfer and a little subgingival to make the appropriate establishment of emergence profile. Retraction cord was placed to expose the margin, and a complete arch putty-wash impression was made with poly-ivynil siloxane (Panasil, Kettenbach, Hesse, Germany). The temporary restoration was made with features to be respected in the final restoration (Visalys Temp, acrylic composite material, Kettenbach, Hesse, Germany). The impressions were poured and mounted on a nonarcon semiadjustable articulator (Dentatus articulator ARH, Dentatus, Spånga, Sweden). The required specific features were determined for the technician as follows: buccolingual dimension of the crown should be smaller and decreased toward the distal part (cantilevered portion should be smaller); Wide and strong proximal contact should be provided, particularly in distal part; clearance of cantilevered portion from the ridge should be provided sufficient to allow the tip of explorer to cross the site; and occlusal contact should not be established on cantilevered portion. Restoration should have a contact in Maximum Intercuspation (MIC) position, not in eccentric movements. To be sure of considering these

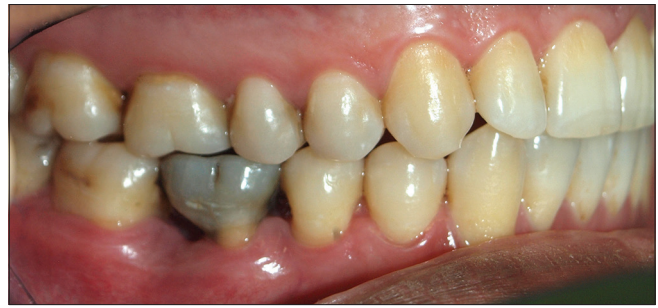

Figure 1: Buccal view of mandibular right first molar with distal root amputation

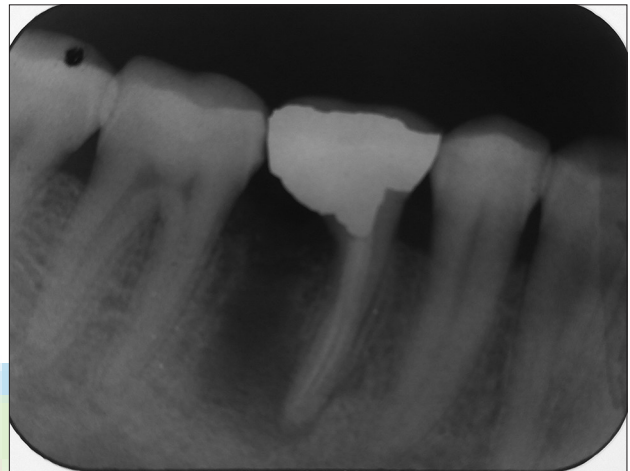


Figure 2: Preoperative radiograph of mandibular right first molar

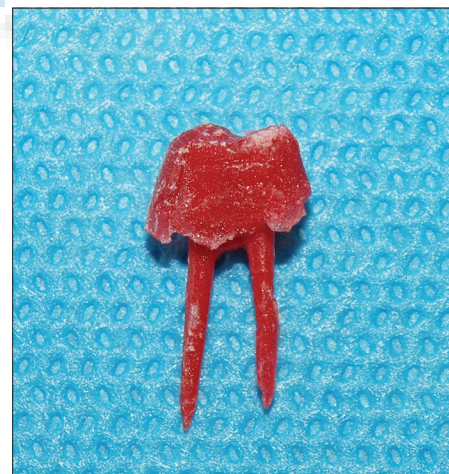


Figure 3: Fabricated postpattern

features, crown wax up was checked [Figure 5]. In the third appointment, seating of the cast framework was verified, and margins were evaluated in both clinical and radiographic examination [Figure 6]. Then, porcelain layering was accomplished by technician [Figure 7]. In the fourth clinical appointment, porcelain trying, checking the color and contour and occlusal adjustment were performed based on previous criteria described. In the fifth appointment, after

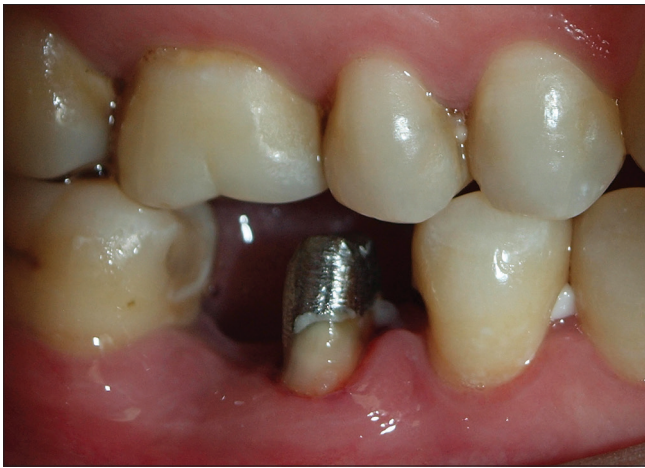

Figure 4: Final preparation after postcementation

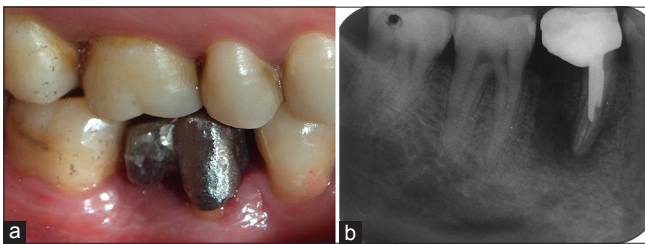


Figure 6: Cast framework try-in through (a) clinical examination, and (b) periapical radiograph

porcelain glazing, the crown was cemented with temporary cement (Temp-bond, Kerr, California, USA) [Figure 8]. Oral hygiene instructions were given to the patient and recall appointments were scheduled. After 1 month, the restoration was cemented permanently with glass ionomer luting agent (GC Fuji II, GC America, Illinois, USA). During 18 months follow-up, there was no problem with esthetic, function, and hygiene and the patient was satisfied with his prosthesis [Figure 9].

DISCUSSION

Current studies revealed that one of the effective treatment options for molars with furcation involvement is root resective therapy.^[4] It was found that it can provide a desirable long-term prognosis, especially when a restoration with accurate fit and occlusion is fabricated.^[5] Bühler suggested that before extraction of any molar, hemisection should be considered as a possible treatment modality.^[6] There are many studies about survival rate and success of root resected teeth. Some of them stated that over 10 years, 30% of molars subjected to root resection failed.^[7] Others suggested that survival rate of such teeth is more than 90%.^[8] Carnevale *et al.* found that survival rate of both root resected tooth and nonresected tooth in 10 years of observation were 93% and 99%, respectively.^[4]

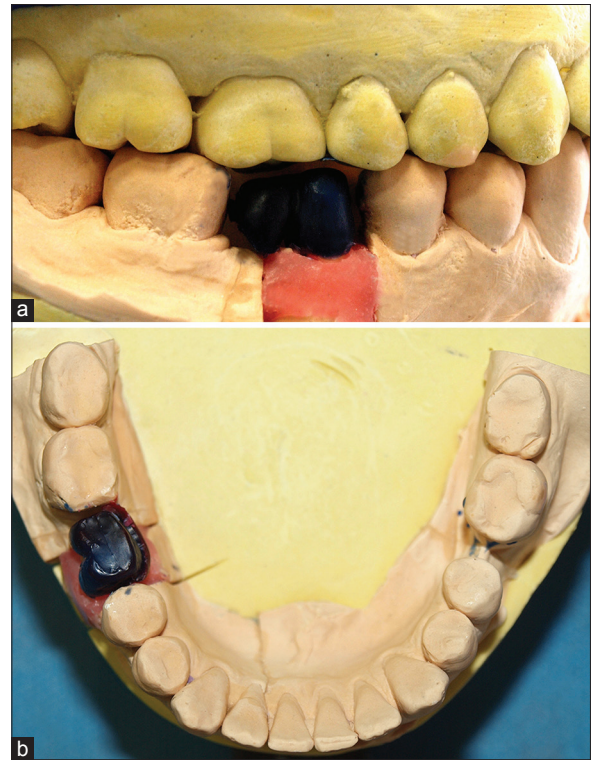


Figure 5: Designing framework wax up. (a) Lateral view, (b) occlusal view

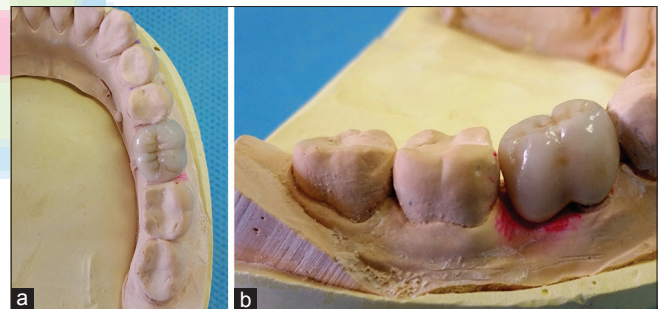


Figure 7: Porcelain layered restoration. (a) Occlusal view, (b) lateral view

Some studies compared survival rate of root resected teeth versus dental implants.^[1] Zafiroopoulos *et al.* found that majority of both dental implants and root resected teeth had not any complication within at least 4 years maintenance care. However, complication of root resected mandibular molars was more than dental implants.^[1] Fugazzotto stated that cumulative success rates of molars subjected to root resection and dental implants replacing the molar are 96.8% and 97%, respectively, over 15 years. They suggested that functional success of both treatment options is high.^[9] Choosing a molar for root resective therapy is influenced by several factors including root morphology, attachment of the remaining root, the divergence of root and location of the furcation.^[10] Mesial root is more difficult to prepare because its concavity is toward the distal. Therefore, in

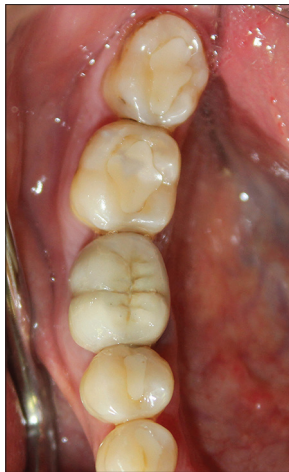

Figure 8: Final restoration of mandibular right first molar

mandibular molars, the mesial root is often subjected to the resection and it is preferred that distal root is maintained.^[10] However, occasionally, distal root has severe bone loss and it is condemned. In such condition, if the mesial root has appropriate anatomy, it can be maintained and the distal root would be resected, similar to the current case.

There are many case reports about mandibular root resected molars. In all of them, edentulous area resulted from root resection was managed using FDP. However, sometimes, dentists encounter with situations in which the tooth adjacent to the edentulous area is intact or with minimal restoration. In such condition, preparation of sound tooth structure is so invasive and is contrary to conservative goals of operative dentistry. Therefore, in described patient, single crown restoration was preferred.

Biomechanical, endodontic, and periodontal factors are the main reasons of failure in restorations of root resected teeth. In a study of Langer *et al.*, failure reasons of the root resected molars were as follows: root fracture (75%), endodontic treatment failure (18.4%), dissolution of the cement (7.9%), and periodontal problems (26.3%). The most common reason resulting in root fracture is biomechanical problems.^[11] Augereau *et al.* assessed location of stress and its magnitude by 3-D finite element in 4 conditions: (1) molar without root amputation, (2) mesial root amputation restored by a single crown, (3) mesial root amputation restored by FDP with two distal abutments and mesial cantilever, and (4) mesial root amputation restored by FDP with two abutments (the distal root and the second premolar). They found that option 2 applies more stresses on surrounding bone and the root.^[12]

According to this, although using a single crown with a cantilever splinted to the remaining root has biomechanical

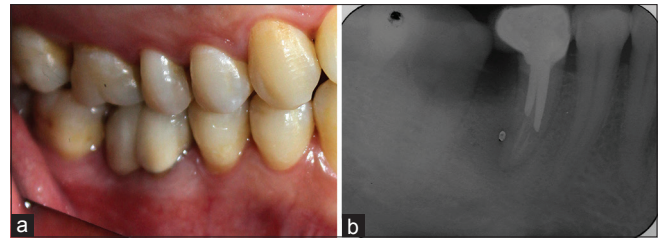


Figure 9: Final restoration after 18 months. (a) Intraoral view, (b) periapical radiograph

risk, it can meet conservative goals which is so important in today dentistry. Therefore, in such condition, certain considerations are required to avoid this problem:

- Although supragingival margin is favorable,^[13] too provide sufficient retention and proper emergence profile, margins should be placed subgingival, but not too much
- In the conventional method, the smaller size of the occlusal table is a determining factor in the survival of restoration in root resected tooth.^[14] The buccolingual width of the occlusal table should be decreased toward the cantilevered portion (to the distal part, in this case)
- Another important factor in root resected teeth is proper occlusal adjustment^[10] which is more important in such cases. There should be a stable contact except in cantilevered portion in MIC. No occlusal contact should be exist in eccentric movements
- A broad and strong proximal contact should be provided, particularly in cantilevered side
- Light contact of buccal half of the cantilevered portion with the ridge is important so that super floss should be able to pass beneath of the pontic to better oral hygiene.

CONCLUSION

Choosing the proper prosthesis type for the root amputated molar depends on several factors such as biomechanical considerations and condition of the adjacent teeth. Therefore, proper case selection is of utmost importance in any treatment plan. If the adjacent teeth are sound or with minimal restoration, it is possible to restore the remaining root in a manner which provides both conservative and functional goals. In such condition, single crown with a cantilevered portion may be a suitable option, if the described important considerations are respected.

Financial support and sponsorship

Nil.

Conflicts of interest

There are no conflicts of interest.

REFERENCES

1. Zafropoulos GG, Hoffmann O, Kasaj A, Willershausen B, Deli G, Tatakis DN, *et al.* Mandibular molar root resection versus implant therapy: A retrospective nonrandomized study. *J Oral Implantol* 2009;35:52-62.
2. Svärdröm G, Wennström JL. Periodontal treatment decisions for molars: An analysis of influencing factors and long-term outcome. *J Periodontol* 2000;71:579-85.
3. Parmar G, Vashi P. Hemisection: A case-report and review. *Endodontology* 2003;15:26-9.
4. Carnevale G, Pontoriero R, di Febo G. Long-term effects of root-resective therapy in furcation-involved molars. A 10-year longitudinal study. *J Clin Periodontol* 1998;25:209-14.
5. Yadav P, Tahir M, Kumar MV, Rao H. Prosthetic rehabilitation of a hemisected maxillary molar: A rare entity. *J Indian Prosthodont Soc* 2013;13:373-7.
6. Bühler H. Survival rates of hemisected teeth: An attempt to compare them with survival rates of alloplastic implants. *Int J Periodontics Restorative Dent* 1994;14:536-43.
7. Carnevale G, Di Febo G, Tonelli MP, Marin C, Fuzzi M. A retrospective analysis of the periodontal-prosthetic treatment of molars with interradicular lesions. *Int J Periodontics Restorative Dent* 1991;11:189-205.
8. Blomlöf L, Jansson L, Appelgren R, Ehnevid H, Lindskog S. Prognosis and mortality of root-resected molars. *Int J Periodontics Restorative Dent* 1997;17:190-201.
9. Fugazzotto PA. A comparison of the success of root resected molars and molar position implants in function in a private practice: Results of up to 15-plus years. *J Periodontol* 2001;72:1113-23.
10. Schmitt SM, Brown FH. The hemisected mandibular molar: A strategic abutment. *J Prosthet Dent* 1987;58:140-5.
11. Langer B, Stein SD, Wagenberg B. An evaluation of root resections. A ten-year study. *J Periodontol* 1981;52:719-22.
12. Augereau D, Pierrisnard L, Renault P, Barquins M. Prosthetic restoration after coronaradicular resection: Mechanical behavior of the distal root remaining and surrounding bone. *J Prosthet Dent* 1998;80:467-73.
13. Savadi A, Rangarajan V, Savadi RC, Satheesh P. Biologic perspectives in restorative treatment. *J Indian Prosthodont Soc* 2011;11:143-8.
14. Saad MN, Moreno J, Crawford C. Hemisection as an alternative treatment for decayed multirrooted terminal abutment: A case report. *J Can Dent Assoc* 2009;75:387-90.

