

Ultrasonic evaluation of influence of hard acrylic resin denture on blood flow of mandibular denture supporting mucosa utilizing duplex color Doppler studies: An *in vivo* study

S. Binsu, K. Chandrasekharan Nair¹, Bijoy Jhon², Sanjna Nayar³, Jose Julian, Muhammed Shahid

Departments of Prosthodontics and ²Implantology, Indira Gandhi Dental College, Ernakulam, Kerala, ¹Department of Prosthodontics, Vishnu Dental College, Bengaluru, Karnataka, ³Department of Prosthodontics, Sree Balaji Dental College, Chennai, Tamil Nadu, India

Abstract

Aims: To determine the influence of hard acrylic denture base materials on the blood flow of mandibular denture supporting mucosa over a period of six months time.

Materials and Methods: Select fifteen edentulous patients of age 55-75 years. The blood flow of the mandibular denture supporting mucosa was measured bilaterally in the molar region and in the incisor region utilizing Ultrasound colour Doppler (2D and Duplex Imaging). Measurements were performed prior to denture insertion and later after the dentures were worn for 1 month, 2 months, 3 months, 4 months, 5 months and 6 months.

Statistical analysis used: Mean blood flow as measured by Ultrasound colour Doppler were tabulated significant changes if any at various time interval in comparison to baseline was assessed by Kruskalwallis ANOVA test followed by Wilkoxan sign rank test for pairwise comparison. (In the present study, $P < 0.05$ was considered as the level of significance).

Results: The denture supporting mucosa exhibited a progressive reduction in the blood flow both with hard denture. The blood flow change with hard denture was a reversible condition as the blood flow improved at the end of six months. Kruskalwallis ANOVA test revealed no significant change in the blood flow at any interval of time in comparison to base value ($P = 0.133$).

Conclusions: Within the limitations of the study denture supporting mucosa exhibited a progressive reduction in the blood flow with hard denture which was reversible.

Keywords: Denture, ultrasonography, vascularity

Address for correspondence: Dr. S. Binsu, Prima, Kaladi, Ernakulam, Kerala, India.

E-mail: drbinsu@gmail.com

Received: 15th January, 2017, **Accepted:** 12th June, 2017

Access this article online	
Quick Response Code:	Website: www.j-ips.org
	DOI: 10.4103/jips.jips_12_17

This is an open access article distributed under the terms of the Creative Commons Attribution-NonCommercial-ShareAlike 3.0 License, which allows others to remix, tweak, and build upon the work non-commercially, as long as the author is credited and the new creations are licensed under the identical terms.

For reprints contact: reprints@medknow.com

How to cite this article: Binsu S, Nair KC, Jhon B, Nayar S, Julian J, Shahid M. Ultrasonic evaluation of influence of hard acrylic resin denture on blood flow of mandibular denture supporting mucosa utilizing duplex color Doppler studies: An *in vivo* study. J Indian Prosthodont Soc 2017;17:289-94.

INTRODUCTION

Alveolar ridge resorption after teeth extraction is a chronic, progressive and cumulative disease of bone reconstruction. Residual ridge resorption (RRR) starts with the tooth and its periodontal membrane loss, responsible for the bone formation.^[1] Periodontal membrane loss leads to decreasing metabolism in the alveolar ridge and to biochemical resorption of the bone caused by the dental plaque endotoxines, prostaglandines and human stimulating factors of alveolar ridge resorption.^[1,2] The patient who needs complete denture therapy is deprived of periodontal support and the entire mechanism of functional load transmission to the supporting tissue is altered. The approximate periodontal ligament area of 45 cm² in each arch combines with viscoelasticity, sophisticated sensory mechanism, and osteogenesis potential to cope up with the diverse direction, magnitude, and frequencies of different forms of occlusal loading. On the other hand, the unsuitability of the tissues supporting complete denture for load-bearing function must be recognized because the mucous membrane is forced to serve an identical purpose as the periodontal ligament.

Preservation of alveolar ridge morphology is a prime objective in complete denture treatment.^[3] This concern applies specifically to mandible because of lesser denture bearing area. Woelfel *et al.*^[4] have cited the projected maxillary denture area to be 4.2 sq in and 2.3 sq in for the mandible; which is in the ratio of 1.8:1. The maxillary residual ridge is often broader, flatter, and more cancellous than the mandibular ridge. Cancellous bone is ideally designed to absorb and dissipate the forces it is subjected to. Resorption is limited to the alveolar process in the maxilla, rarely moving to its body, while in the mandible changes also affect the mandibular angle, leading to its atrophy. Alveolar loss in the maxilla runs from the cheek to the palate in the horizontal plane, in the mandible the alveolar ridge becomes atrophic in the glosso-buccal direction in its lateral parts, while in the anterior part this occurs from the oral vestibule.^[4] These anatomical variations may result in the observed differences in the RRR of the upper and lower jaw and the need for preservation of mandibular alveolar ridge.

A heavily beaded area may cause partial or complete stenosis of veins and lymphatic vessels. The destruction of supporting tissue may occur because of constant pressure and interfere with vascularity. When the soft tissue mucosa underneath the denture base is compressed, the blood flow that supplies nutrients to and removes metabolites from the bone can be affected, potentially leading to resorption.^[5,6]

Consequently it appears important to determine whether hard acrylic resin base interfere with the blood supply to supporting tissues of mandibular residual ridge underlying dentures.

The aim of this study was to determine the influence of hard denture on the blood flow of tissues under mandibular denture base.

Null hypothesis: Hard acrylic denture base has no influence on the blood flow of denture bearing mucosa.

METHODOLOGY

Fifteen edentulous patients were selected. The following criteria were used in subject selection: Patient with Class I jaw relation, aged between 55 and 75 years, stable health without any systemic disorder, and presence of Class I ridge morphology, normal tongue position, nonsmoker. The exclusion criteria were patient with Class II and Class III jaw relation, neuromuscular incoordination, parafunctional habits, any systemic conditions and medications, temporomandibular disorders, inflammation of residual ridge.

All the patients were provided with complete dentures fabricated using similar technique. Final impressions were made with light body (addition silicone) and balanced occlusal schemes were provided. Processing consisted of a compression molding technique using acrylic resin (acralyn-H). After the denture insertion, clinical problems associated with new denture (pressure spots) were eliminated. The occlusion was carefully checked to ensure even occlusal contact and nondefective. Prior to insertion blood flow measurements were made and base line value were recorded. Influence of hard acrylic

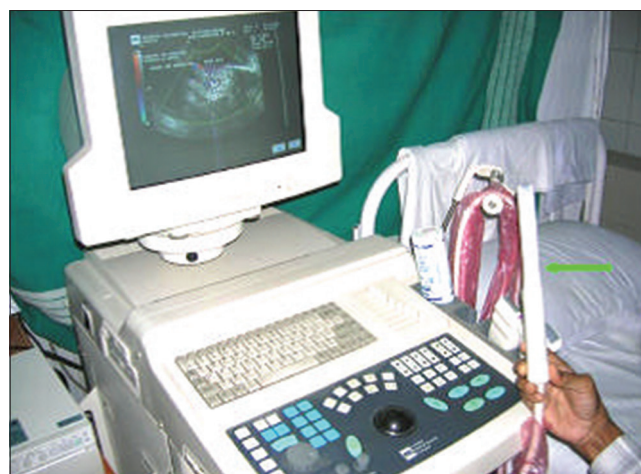

Figure 1: HDI 1500 – ATL unit with three-dimensional and color Doppler facilities (green colour marked is intracavity transducer probe)

resin on blood flow of mandibular denture bearing tissue was evaluated utilizing HDI 1500 – ATL unit with two-dimensional (2D) and color Doppler [Figure 1] facilities. For intra oral mucosal study, intracavity convex transducer with 9–5 MHz capacity was used. Vascularity measurements were made for all the fifteen patients prior to insertion, 1st month, 2nd month, 3rd month, 4th month, 5th month and 6th month of denture insertion. Vascularity values were recorded by placing intracavity probe on the residual ridge using measuring plate.

Measuring plate [Figures 2 and 3]

Water filled vinyl glove was used as the fluid medium. An acrylic plate with glove holder was fabricated to standardize the positioning of the probe in the first molar and the anterior (incisor) region for each patient.

Ultrasound and imaging

Ultrasound waves produced by piezoelectric crystals

in ultrasonography (USG) transducer pass through tissues and get reflected differentially and received by the same crystal and are converted into electronic signals. Computer converts electronic signals USG into images that are projected on the monitor. Intracavity transducer pick up moving tissues and red blood cells and delineate tissue images motion mode [Figure 4], color coded images (5) and spectral images [Figure 5]. Also, the flow pattern by spectral Doppler clearly indicates the velocity of blood flow to the region (cm/s). Prior to insertion is shown in Figures 4-6 and after insertion is shown in Figures 7-9.

RESULTS

Out of 15 patients seven patients showed improvement in blood flow at the end of 6 months as shown in table. Vascularity measurements remained same for one patient. Remaining seven patient showed reduction in blood flow after 6 months of insertion. However Kruskal–Wallis

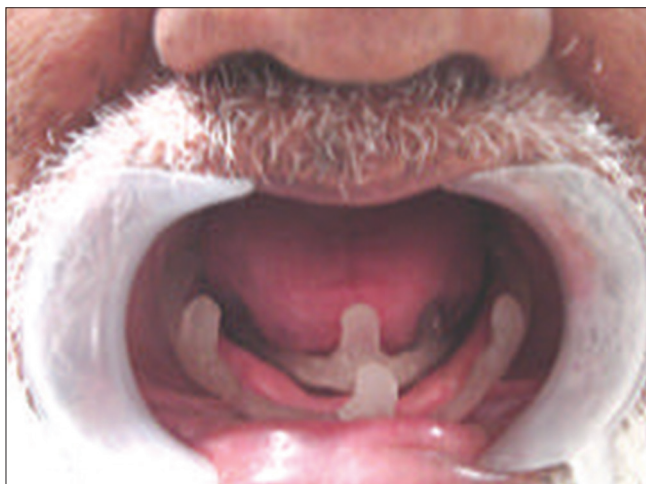

Figure 2: Intra oral view of acrylic stent

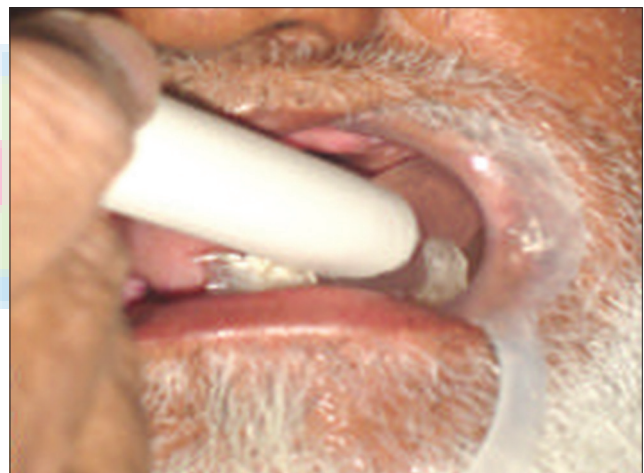

Figure 3: Placement of prob in relation to first molar region

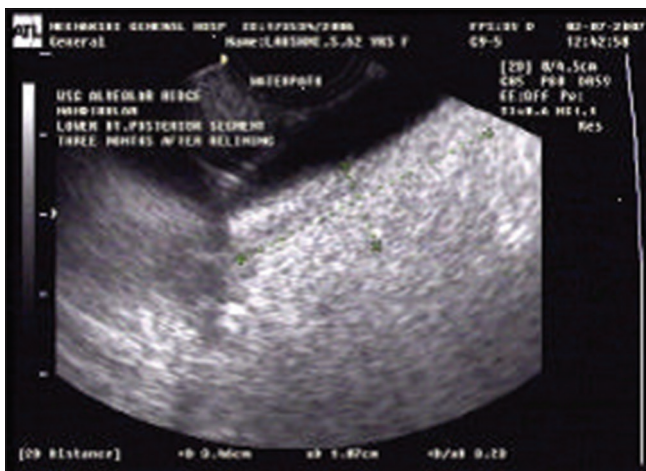

Figure 4: Prior to insertion two-dimensional

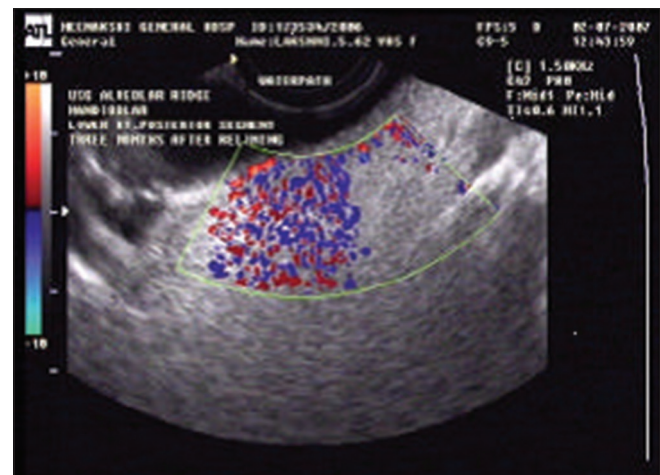

Figure 5: Prior to insertion spectral image

Table 1: Mean-peak systolic velocity of control group at different time intervals

Patients	V1 (cm/s)	V2 (cm/s)	V3 (cm/s)	V4 (cm/s)	V5 (cm/s)	V6 (cm/s)	V7 (cm/s)	Kruskal-Wallis ANOVA
1	1.71	1.92	2.03	2.03	1.79	1.59	1.99	$\chi^2=9.815$, degree of freedom=6, $P=0.133$ (NS)
2	2.02	1.96	2.06	2.01	1.81	2.02	2.09	
3	2.02	1.56	2.02	1.96	2.06	1.09	2.00	
4	1.80	1.92	1.96	2.10	2.00	2.00	1.78	
5	2.80	2.01	1.55	1.92	2.04	2.03	1.99	
6	1.91	1.77	1.54	2.04	2.16	2.03	1.66	
7	1.90	2.29	1.79	1.83	1.99	1.99	2.10	
8	1.81	1.86	2.04	2.01	2.03	1.94	2.14	
9	1.87	2.26	2.31	2.51	2.08	2.71	1.62	
10	2.11	2.30	1.99	2.36	2.09	2.02	1.77	
11	1.81	1.89	1.99	2.23	1.84	1.79	1.81	
12	1.62	1.74	1.72	2.02	2.13	2.03	1.66	
13	1.41	1.35	2.56	1.83	1.99	1.64	2.10	
14	2.01	2.08	2.18	2.02	2.01	1.93	1.79	
15	1.46	2.68	2.68	2.22	2.00	1.32	1.99	

V1: Prior to insertion, V2: 1st month, V3: 2nd month, V4: 3rd month, V5: 4th month, V6: 5th month, V7: 6th month, NS: Not significant

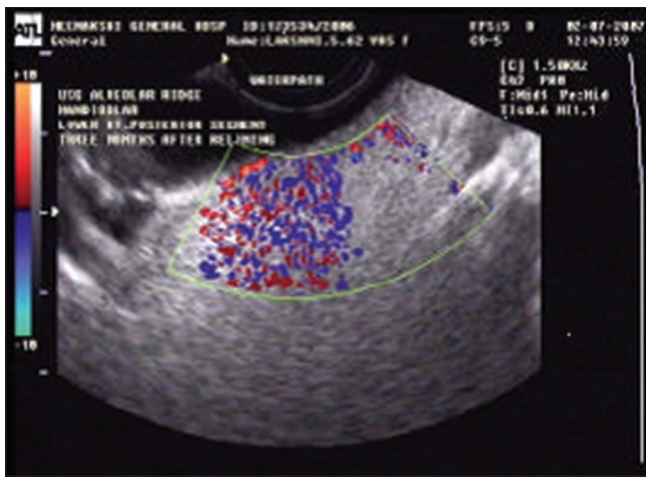


Figure 6: Prior to insertion color Doppler

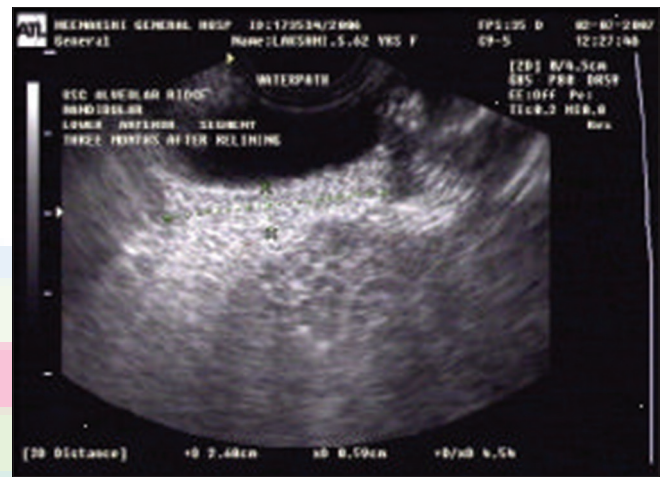

Figure 7: After insertion two-dimensional image

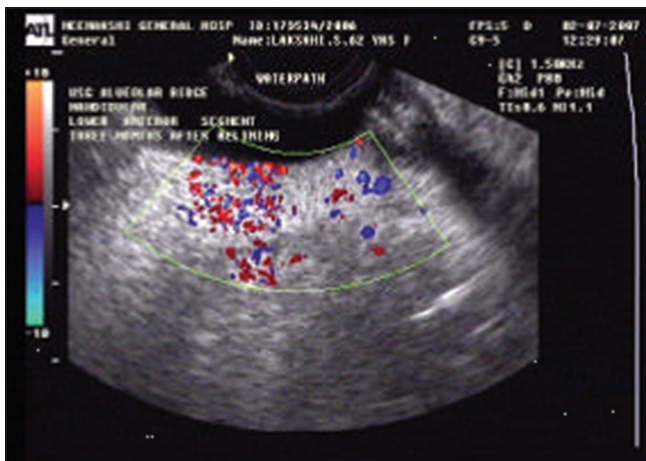

Figure 8: After insertion color Doppler

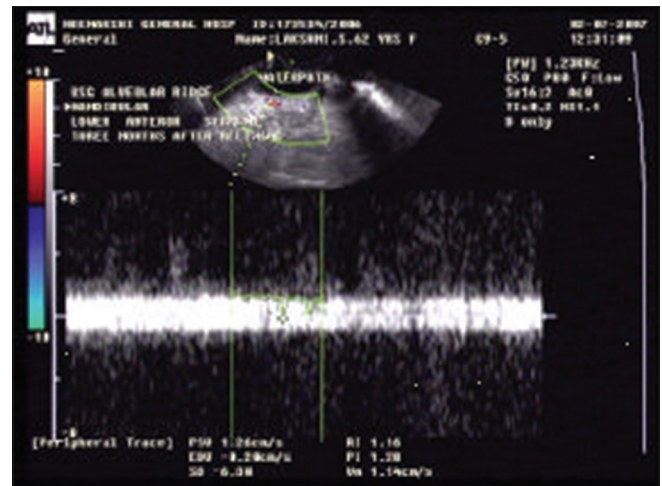
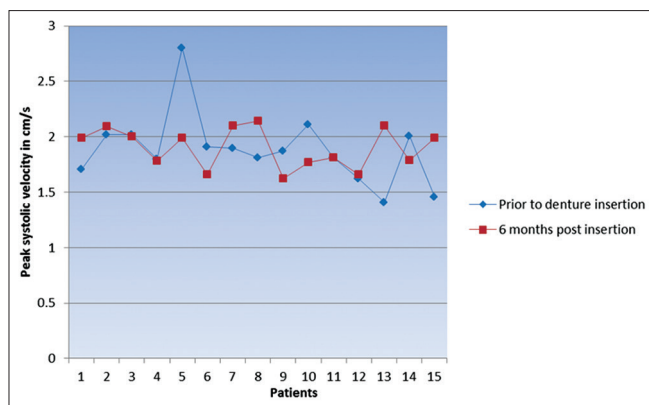


Figure 9: After insertion spectral image

ANOVA test revealed no significant change in the blood flow at any interval of time in comparison to base value. “P” value turns out to be 0.133 (nonsignificant) [Table 1 and Graph1] (in the present study, $P < 0.05$ was considered as the level of significance).

DISCUSSION

The investigation of the changes in microcirculation is one of the key measures to evaluate the changes in tissue



Graph 1: Graph depicts peak systolic velocity of control group at different time intervals showing the blood flow change with hard denture. After 6 months of denture wearing period, blood flow returned to the value obtained prior to denture insertion

underlying denture base. This study was planned to evaluate the changes in blood flow for a period of 6 months after the denture insertion utilizing 2D USG. It was found that the denture supporting mucosa exhibited a reduction in the blood flow while using acrylic complete denture. However there was an improvement in the blood flow at the end of 6 months. Reduction in blood supply is similar to the observation of Ataserver *et al.*^[7] when the epithelial layer of the mucosa is subjected to loading, there will be cellular swelling, increased nuclear size, and intercellular edema.^[8] This inflammatory response of the cells and surrounding tissue may contribute to a change in the permeability of the mucosal tissue, which may further compromise blood circulation. If the hydrostatic pressure that develops in the mucosa underneath the denture exceeds the blood pressure in the mucosa blood vessels, blood flow will be decreased and may even temporarily cease altogether as a result of the combination of active arteriolar closure and passive capillary obstruction.^[9] However at the end of 6 months of observation period, the blood flow was increased in few patients which is similar to the finding of Kocabalkan and Turgut^[7] he reported an increase in blood flow 40 days after wearing complete dentures.

The USG is safe and suitable for simple assessment of blood vessels, and also enables a real-time interpretation.^[10] For standardisation of the positioning of the probe we fabricated a measuring plate with glove holder. The image acquisition methods for vascularization are expensive and may jeopardize the patient's condition. 2D transvaginal sonography to be a highly effective means of diagnosis, with 75%–100% sensitivity and up to 95% specificity^[11] USG has been used in dentistry mainly in periapical injuries to make differential diagnosis between a granuloma and a cystic lesion^[10] or to intraosseous lesions.^[12,13] Others studies refer

to the parotid gland performing Doppler USG.^[14,15] Other clinical applications of USG are assessment of donor site vascularity for grafts, evaluation of soft tissue and treatment planning prior to implant placement, evaluation of gingival vascularity, periodontal soft tissue evaluation. Advantages of USG are noninvasive, radiation free, repeatable, quick to perform, acceptable to patients in children and pregnant women, provides direct visualization of quantum of vascularity, wider area of right and left, upper or lower segments delineated, comparative study of gingiva at different sites possible, provides more information directly and faster than radionuclide scintigraphy, selective catheter angiography, laser Doppler flowmetry.

CONCLUSION

Within the limitations of the study following conclusions were drawn that in complete denture patients, there was an initial reduction of blood flow due to alveolar ridge resorption followed by an increase in the blood flow related to bone remodelling. Null hypothesis was accepted as the influence on blood flow was nonsignificant. To the best of our knowledge this is the first study conducted to study vascularity using USG. In the context of our observation USG is demonstrated to be a reproducible method for assessment of alveolar bone vascularity. However smaller sample size was one of the drawback of our study. Long duration study needed to correlate it with resorption rate.

With the increasing popularity of implant therapy and rapid advancements in computed tomography, there is potential to develop a patient-specific treatment plan in clinical applications that may provide the least disturbance to blood flow in the mucosa to better suit individual residual ridge conditions. Areas for further research includes its application in implant restoration and long-term investigations in reducing RRR.

Financial support and sponsorship

Nil.

Conflicts of interest


There are no conflicts of interest.

REFERENCES

1. Klemetti E, Vainio P, Lassila V, Alhava E. Trabecular bone mineral density of mandible and alveolar height in postmenopausal women. *Scand J Dent Res* 1993;101:166-70.
2. Klemetti E. Resistance of the maxillary ridge to occlusal trauma. *J Prosthet Dent* 1995;73:250-2.
3. Zarb GA, Bolender CL, Eckert S, Jacob R, Fenton A, Mericke-Stern R. *Prosthetic Treatment of Edentulous Patients: Complete Dentures and Implant Supported Prostheses*. 12th ed. St. Louis: TEXAS; 2003.

Binsu, *et al.*: Ultrasonic evaluation of mandibular denture supporting mucosa

4. Abirami G Samyukta, *et al.* Residual ridge resorption in complete denture wearers. *J Pharm Sci Res* 2016;8:565-9.
5. Kydd WL, Daly CH, Nansen D. Variation in the response to mechanical stress of human soft tissues as related to age. *J Prosthet Dent* 1974;32:493-500.
6. Sawada A, Wakabayashi N, Ona M, Suzuki T. Viscoelasticity of human oral mucosa: Implications for masticatory biomechanics. *J Dent Res* 2011;90:590-5.
7. Kocabalkan E, Turgut M. Variation in blood flow of supporting tissue during use of mandibular complete dentures with hard acrylic resin base and soft relining: A preliminary study. *Int J Prosthodont* 2005;18:210-3.
8. Kydd WL, Daly CH. The biologic and mechanical effects of stress on oral mucosa. *J Prosthet Dent* 1982;47:317-29.
9. Ashton H. The effect of increased tissue pressure on blood flow. *Clin Orthop Relat Res* 1975;113:15-26.
10. Steinhart H, Zenk J, Sprang K, Bozzato A, Iro H. Contrast-enhanced color Doppler sonography of parotid gland tumors. *Eur Arch Otorhinolaryngol* 2003;260:344-8.
11. Canzone G, M. Parlato, L. Triolo *et al.* 2D-3D ultrasound in the diagnosis of uterine malformations. *Donald Sch J Ultrasound Obstet Gynecol* 2007;1:77-9.
12. Cotti E, Simbola V, Dettori C, Campisi G. Echographic evaluation of bone lesions of endodontic origin: Report of two cases in the same patient. *J Endod* 2006;32:901-5.
13. Bialek EJ, Jakubowski W, Osmólski A, Zajkowski P. Ultrasonography as the method of incidental detection of mandible lesions. *Acta Otorhinolaryngol Belg* 2004;58:157-9.
14. Sumer AP, Danaci M, Ozen Sandikçi E, Sumer M, Celenk P. Ultrasonography and Doppler ultrasonography in the evaluation of intraosseous lesions of the jaws. *Dentomaxillofac Radiol* 2009;38:23-7.
15. Carotti M, Salaffi F, Manganelli P, Argalia G. Ultrasonography and colour Doppler sonography of salivary glands in primary Sjögren's syndrome. *Clin Rheumatol* 2001;20:213-9.



New features on the journal's website

Optimized content for mobile and hand-held devices

HTML pages have been optimized of mobile and other hand-held devices (such as iPad, Kindle, iPod) for faster browsing speed.

Click on [**Mobile Full text**] from Table of Contents page.

This is simple HTML version for faster download on mobiles (if viewed on desktop, it will be automatically redirected to full HTML version)

E-Pub for hand-held devices

EPUB is an open e-book standard recommended by The International Digital Publishing Forum which is designed for reflowable content i.e. the text display can be optimized for a particular display device.


Click on [**EPub**] from Table of Contents page.

There are various e-Pub readers such as for Windows: Digital Editions, OS X: Calibre/Bookworm, iPhone/iPod Touch/iPad: Stanza, and Linux: Calibre/Bookworm.

E-Book for desktop

One can also see the entire issue as printed here in a 'flip book' version on desktops.

Links are available from Current Issue as well as Archives pages.

Click on  View as eBook