

Systematic analysis on the efficacy of bone enhancement methods used for success in dental implants

S. Elakkiya, A. S. Ramesh, K. Prabhu

Department of Prosthodontics, Adhiparasakthi Dental College, Melmaruvathur, Tamil Nadu, India

Abstract

Abstract: Bone grafting is beneficial in enhancing bones that are lost due to trauma or natural or pathologic process. Autogenous bone, allogenic bone, xenogeneic bone, bone substitutes, and alloplasts can also be used for this purpose. Bone quantity should be adequate for the placement of implants, which necessitate the use of bone grafts before implant placement.

Objective: This review analyses the different bone graft materials that are used for grafting around implants and evaluate if these grafts yield successful implant osseointegration over a period of time.

Materials and Methods: The MEDLINE–PubMed database was searched from September 2016 to 10 years previously. Several journals were hand searched and from cross-references. The primary outcome measure that was analyzed was the survival rate of dental implants in the grafted sites at 6 months–1 year, and the secondary outcomes were success rates of dental implants over a period of 3–5 years' follow-up.

Results: The search yielded 213 articles. Ultimately, 31 studies meeting the eligibility criteria were selected. The analysis shows that autologous bone grafts can be preferred over allografts and xenografts for grafting implant sites, which showed less complication and high success rate.

Conclusion: Based on the available data in the current existing studies with a follow-up period of at least 3–5 years, it can be summarized that the autologous bone grafts can be preferred over allografts and xenografts for grafting implant sites since they are stable for at least 3–5 years.

Keywords: Bone grafts, bone loss, dental implants, implant success

Address for correspondence: Dr. Elakkiya Saravana Kumar, Aksharam, Plot No. 6, Thiruveedhiamman Koil Street, Royal Avenue, Koyambedu, Chennai - 600 107, Tamil Nadu, India. E-mail: elakya.dent@gmail.com

Received: 21st January, 2017, **Accepted:** 10th April, 2017

INTRODUCTION

Most patients present after tooth loss with a wide range of bone loss, which may not accommodate a dental implant prosthesis. Bone grafting is beneficial in enhancing bones that are lost due to trauma or natural or pathologic process. Autogenous bone, allogenic bone, xenogeneic bone, bone

substitutes, and alloplasts are commonly used for this purpose.^[1]

The long-term success of dental implants is highly dependent upon the degree of osseointegration in sufficient and healthy bone.^[2] Implants have a predictable outcome and are the advanced treatment option for edentulous patients.^[3]

Access this article online	
Quick Response Code: 	Website: www.j-ips.org
	DOI: 10.4103/jips.jips_19_17

This is an open access article distributed under the terms of the Creative Commons Attribution-NonCommercial-ShareAlike 3.0 License, which allows others to remix, tweak, and build upon the work non-commercially, as long as the author is credited and the new creations are licensed under the identical terms.

For reprints contact: reprints@medknow.com

How to cite this article: Elakkiya S, Ramesh AS, Prabhu K. Systematic analysis on the efficacy of bone enhancement methods used for success in dental implants. *J Indian Prosthodont Soc* 2017;17:219-25.

Bone augmentation helps in providing sufficient quality and quantity of the bone in the atrophic ridges for the placement of dental implants.^[4] Grafts and guided bone regeneration techniques are used to improve primary stability during implant placement in atrophic ridges.^[5] Hence, a systematic analysis was performed to check the efficacy of bone enhancement methods used for success in dental implants.

MATERIALS AND METHODS

The following analysis was performed according to the guidelines and the principles of the PRISMA statement for a systematic review.

Focused question patient intervention comparison and outcome

The review is focused on: “What is the efficacy of various types of bone enhancing grafts that leads to dental implants success?”

Search strategy

The MEDLINE–PubMed database was searched from September 2016 to 10 years previously.

The following search terms were used as shown in Figure 1.

Study inclusion criteria

The studies were analyzed according to the following inclusion criteria:^[6-8]

1. All studies treated with bone grafts and implants with a follow-up of at least 1 year
2. Patients with reduced quantity of edentulous ridges resulted due to ridge resorption, periodontal diseases, and trauma were included
3. The following grafts were considered:^[9-11]
 - a. Autologous bone graft
 - b. Allograft
 - c. Composite bone grafts
 - d. Xenograft.

4. Articles related to dental implants were considered for inclusion
5. All dental implant systems were included
6. Only studies in the English language were included
7. Only human studies were included.

Study exclusion criteria

The studies with following criteria were not included in the review:^[12-14]

1. Studies involving only implants, without any bone graft
2. Case reports regarding patients with any syndrome or major systemic disease
3. Studies not related to implants and bone grafts
4. Studies not related to dentistry
5. Studies with insufficient information
6. Animal studies.

Data extraction

All studies which met the inclusion and exclusion criteria for review were obtained and screened independently. Relevant studies without abstract were included for full-text screening. The following data were extracted from the studies included for review:^[15-20] publication, study design, number of patients, type of graft, and number of dental implants, timing of implants, follow-up time, implant survival, and implant success rate. Quality of various studies regarding bone graft, implant success, and survival were considered for quality assessment of bone graft and implant [Figures 1 and 2].

Failure of bone grafts

The most frequent complication of graft failure may be due to exposure of bone graft, not proper stabilization of the graft, and infection.^[21-26] Of the complications, only graft exposure was moderately associated with bone graft failure.^[27]

The factors that can increase the risk of a bone graft failure are:^[28,29]

- Periodontal disease
- Smoking
- Osteoporosis
- Surgical errors
- Systemic conditions such as uncontrolled diabetes
- Immune system deficiencies.

The implants placed in the autologous bone grafts had a higher survival rate when compared to those placed in other graft materials. Alloplastic material had a lower resorption rate when compared to autologous material.^[30] The addition of bone substitute to autogenous grafts has been found to accelerate bone formation,^[27 31] but interestingly, in this review, majority of studies found a higher rate of

Search	Add to builder	Query	Items found	Time
#26	Add	Search (Cortical bone chips) OR (Osseous coagulum) OR (Bone blend) OR (Dentin graft) OR (Cortical bone graft) OR (Cancellous bone graft) OR (Corticocancellous bone graft) OR (Lamellar graft) OR (Periosteal graft) OR (Block graft) OR (Particulate graft) OR (PRP) OR (PRF) OR (CGF) OR (TGF-beta) OR (PDGF) OR (FGF) OR (BMP) OR (ePTEF) AND (Autologous bone graft) OR (Bone enhancement methods) OR (Autologous Augmentation) OR (Dental implant)	12194	12:58:33
#25	Add	Search (PRP) OR (PRF) OR (CGF) OR (TGF-beta) OR (PDGF) OR (FGF) OR (BMP) OR (ePTEF) AND (Autologous bone graft) OR (Bone enhancement methods) OR (Autologous Augmentation) OR (Dental implant)	12176	12:56:18
#24	Add	Search (Cortical bone chips) OR (Osseous coagulum) OR (Bone blend) OR (Dentin graft) OR (Cortical bone graft) OR (Cancellous bone graft) OR (Corticocancellous bone graft) OR (Lamellar graft) OR (Periosteal graft) OR (Block graft) AND (Autologous bone graft) OR (Bone enhancement methods) OR (Autologous Augmentation) OR (Dental implant)	12147	12:52:46
#23	Add	Search (Dental implant)	5811	12:49:01

Figure 1: Keywords for article search

graft failure in patients who received composite bone grafts [Tables 1 and 2].

DISCUSSION

In the review of the past studies, evidence is available about the efficacy of different types of bone grafts. This review tried to systematically evaluate the current evidence and to compare the different grafts in bone enhancement as well as the success of implants placed along with the graft in long-term follow-up. In total, 31 articles could be included, from which the data were obtained. To assess the success of implant placed in different bone grafts, all the 31 articles were reviewed for the following characteristics: design of the study, number of patients per study, graft type, surgical procedure and donor site, number of dental implants, timing of implants, follow-up time, implant survival, and implant success rate.

Block graft

Out of 31 included articles, 14 studies were using block graft.^[32-45] Of which, 11 studies were case reports while three were prospective. A total of 86 patients with reduced alveolar ridges were treated with block grafts. In total, 223 dental implants were placed after 3–6 months of

grafting. The follow-up ranged from 1 to 5 years. The survival rates for the dental implants in grafted bone ranged from 97.3% to 100% and the mean was 98.5%.

Particulate graft

Out of 31 articles included, three studies were using particulate graft.^[46-48] Of these, all three were case reports. A total of three patients with reduced alveolar ridges were treated with particulate graft. In total, nine dental implants were placed after 4 months of healing. The follow-up ranged from 1 to 3 years and the mean was 1.7 years.

Blood derivatives

Out of 31 articles included, three studies have used blood derivatives as grafting material.^[49-51] A total of 15 dental implants were placed for 3 patients, of which 6 implants were placed immediately along with the graft material and 9 dental implants were placed after 2–3 months of healing. After the start of loading, the follow-up ranged from 1 to 4 years. Survival rate for the dental implants was 94.7%. The implant success rate was 93.2%.

Composite bone graft

Out of 31 articles included, seven studies have used composite bone as grafting material.^[52-55] Three studies were case report while four were case series. A total of five patients were treated with three different donor materials and 21 dental implants were placed after 4–12 months of graft healing. After the start of loading, the follow-up ranged from 1.0 to 5 years. The survival rate for the dental implants in grafts was 99.3%. The implant success rate was 90.7%.

Xenograft

Out of 31 articles included, only one study used xenograft as grafting material.^[30] One patient with reduced alveolar ridge was treated with bovine bone, mixed with fibrin adhesive. In total, three dental implants were placed after 6–12 months after healing of the graft material. After the start of loading, the follow-up ranged from 1 to 3 years. The survival rate for the dental implants was 85.4%. The implant success rate was 73.2%.

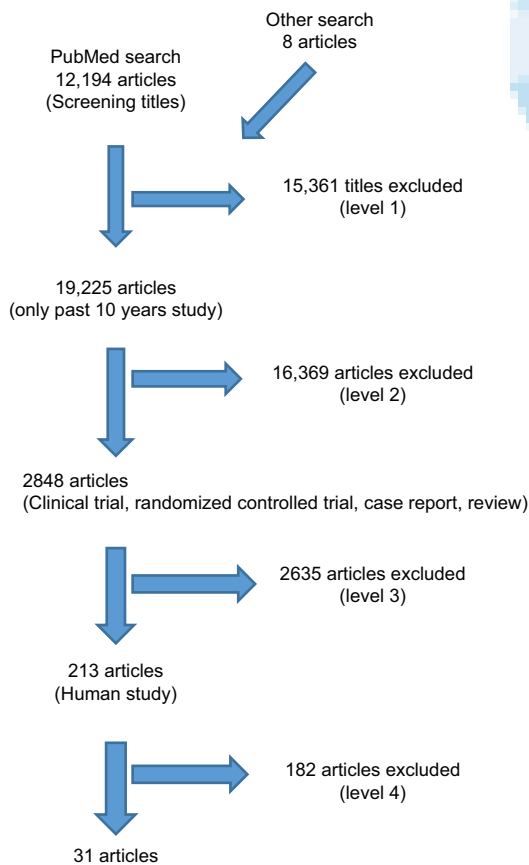


Figure 2: Search strategy

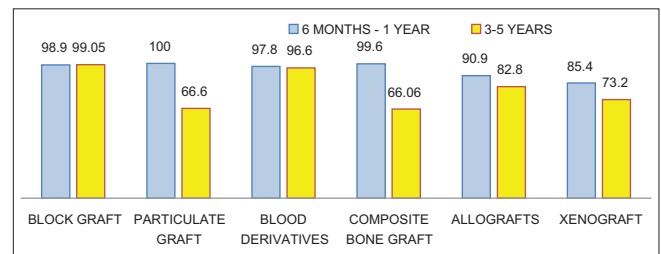


Chart 1: Success and survival rate of implants placed in various graft materials.

Table 1: Characteristics of 31 studies included

Reference	Study design	Number of patients	Graft materials	Number of implants	Timing of implant placement	Follow-up implant survival (%)	Implant success (%)
José-Luis Cebrian-Carretero	Case series	4	Fibula, iliac crest, and scapula-free flaps	19	6-12 months after reconstruction	100	100
Balaji SM	Case report	1	BMP-rhBMP-2	6	No data	100	100
Emir Yüzbaşıoğlu	Case report	1	Iliac bone graft	3	4 years 6 months after reconstruction	No data	No data
Kristian Rude	Case report	1	Free vascularized fibula flap	5	Oral rehabilitation was carried out 12 months postoperatively	100	100
Hisahiro Kamoi	Case report	1	Rib bone	5	Dented implants inserted simultaneously during surgery	100	100
Po-Sung Fu	Case report	1	Autogenous bone harvested from the chin	1	4 months after socket augmentation	100	100
Pedro Infante Cossío	Case report	1	Composite bone graft of autogenous bone, xenograft, and autologous PRP	2	24 months after augmentation	100	100
Hideshi Sekine	Case report	1	Iliac bone block and PCBM	5	On the right side, two implants were placed 4 months after bone grafting. On the left side, three implants were placed simultaneously after bone grafting	100	100
Masako Sawaki, <i>et al.</i>	Case report	1	A PCBM graft and RBOG	2	5 months after bone grafting	100	100
Juliano de Alenear Vasconcelos, <i>et al.</i>	Case report	1	Bone tissue collected during the osteotomies and drilling processes	2	Bone graft placed at the same time of implant placement	100	100
Dr. Eugenio Miguel Pereira	Case series	1	Fresh-frozen bone allograft from the iliac crest	8	5 months after grafting	100	100
Francesco Grecchi	Case report	1	Femur homografts	12	8 weeks after grafting	100	100
Gui-Youn Cho-Lee	Case report	1	Free vascularized fibular flap	3	Implants placed after 3 months	100	100
Pedro Infante-Cossío	Case report	1	Iliac crest graft	3	6 months and 2 weeks after grafting	100	100
Po-Sung Fu	Case report	1	Chin graft	1	Implant placed after 4 months of grafting		
Dr. Gregory Taylor	Case report	1	Ramus graft	1	Implant placed after 6 months of grafting		
Mario Santagata	Case series	11	Particulate bone graft				
Jee-Won Moon	Case report	1	Bovine bone, mixed with fibrin adhesive	3	Placed immediately		
Mi-Ra Ahn	Case series	11	Irradiated cancellous bone and marrow	27	Placed after 5 months	99	97.5
Devorah Schwartz-Arad	Retrospective study	214	Autologous intraoral block OBG augmentations, combined with Bio-Oss - mixed with PRP, and covered by PPP - as scaffold	633	4-6 months	93.4	83
Thomas J. Balshi	Case report	1	Iliac crest bone graft	2	Implants placed subsequently	50	0
Matteo Chiapasco	Case series	3	Iliac crest	22	5-6 months	100	100
Eduardo Anitua	RCT	23	PDGF and TGF-β		Placed immediately	100	100

Contd...

Table 1: Contd...

Reference	Study design	Number of patients	Graft materials	Number of implants	Timing of implant placement	Follow-up implant survival (%)	Implant success (%)
Michael Peleg	RCT	63	Autogenous composite bone graft consisting of a combination of 50% membranous bone harvested from the symphysis and 50% DFDBA	160	Placed immediately	100	100
Ji-Min Kim	Case series	63	Fibrin-rich block with concentrated growth factors	74	After 5 months	100	98.6
Gerry M. Raghoebar	Case series	14	Zygomatic rim	14	No data	100	100
Stefan Lundgren	Case series	11	Bone flap	21	Placed immediately	98.7	100
Mats Sjöström	Case series	29	Free iliac crest grafts	192	6-8 months after grafting	90	61.8
Federico Hernández-Alfaro	Case series	14	Mandibular bone block graft and biomaterials	108	14-16 weeks after grafting	88.4	77.99
Dong-Seok Sohn	Case series	53	Fibrin-rich blocks with CGF	113	Placed simultaneously	99	98.2
Jee-Won Moon	Case series	14	Peripheral venous blood	31	Placed simultaneously	95.1	93.5

CGF: Concentrated growth factor, DFDBA: Demineralized freeze-dried bone allograft, PDGF: Platelet-derived growth factor, TGF-β: Transforming growth factor-β, rhBMP2: Recombinant human bone morphogenetic protein-2, PCBM: Particulate cancellous bone and marrow, RBOG: Ramus bone onlay grafting, OBG: Onlay bone graft, PPP: Platelet-poor plasma, RCT: Randomized controlled trials, PRP: Platelet-rich plasma, BMP: Bone morphogenetic protein

Table 2: Characteristics of the different bone grafts

Grafts	Patient	Implant	Survival rate (%)	Success rate (%)
Block graft				
Femur graft	1	12	97.3	95.5
Chin graft	1	-	100	100
Iliac graft	81	208	100	100
Rib graft	1	-	98.3	100
Ramus graft	1	-	98.8	98.8
Fibula graft	1	3	100	100
Fibula, iliac crest, and scapula-free flaps	4	19	100	0
Particulate graft				
PCBM	1	5	100	100
Bone collected during osteotomy process	1	2	100	0
PCBM and RBOG	1	2	100	100
Blood derivatives				
PRP	1	5	97.3	96.05
BMP (rhBMP-2)	1	6	100	100
CGF	1	4	98.9	97.2
Peripheral venous blood	14	31	95.1	93.5
Composite bone graft				
Composite bone graft of autogenous bone, xenograft, and autologous PRP	1	2	100	100
Fibrin-rich blocks with CGF	53	113	99	98.2
Allografts				
Irradiated cancellous bone and marrow	11	27	99	97.5
Mandibular bone block graft and biomaterials	14	108	88.4	77.99
Xenograft				
Bovine bone, mixed with fibrin adhesive	1	3	85.4	73.2

PCBM: Particulate cancellous bone and marrow, RBOG: Ramus bone onlay grafting, PRP: Platelet-rich plasma, BMP: Bone morphogenetic protein, CGF: Concentrated growth factor, rhBMP2: Recombinant human bone morphogenetic protein-2

RESULTS

The results of the study are depicted in Chart 1.

The mean value of the survival and success rate of the implants on various types of grafts is charted on a graph.

The blue bar signifies the survival rate and yellow bar signifies the success rate.

From the chart, we can observe that:

- Block grafts have 98.9% survival rate and 99.05% success rate

- Particulate grafts have 100% survival rate and 66.6% success rate
- Blood derivatives have 97.8% survival rate and 96.6% success rate
- Composite bone grafts have 99.6% survival rate and 66.06% success rate
- Allografts have 90.9% survival rate and 82.8% success rate.

CONCLUSION

Based on the available data in the existing studies with a follow-up period of at least 3–5 years, it can be summarized that the autologous bone grafts can be preferred over allografts and xenografts for grafting implant sites since they are stable for at least 3–5 years.

Among the various autologous grafts reviewed, block grafts and blood derivatives had a higher percentage of success rate. Hence, by following proper diagnostic and clinic protocol for implant placement, block grafts and blood derivatives can be used for better clinical outcome and success of the implant over a long period of time.

Financial support and sponsorship

Nil.

Conflicts of interest

There are no conflicts of interest.

REFERENCES

1. Tucker S, Cevidanes LH, Styner M, Kim H, Reyes M, Proffit W, *et al.* Comparison of actual surgical outcomes and 3-dimensional surgical simulations. *J Oral Maxillofac Surg* 2010;68:2412-21.
2. Sheikh Z, Sima C, Glogauer M. Bone replacement materials and techniques used for achieving vertical alveolar bone augmentation. *Materials* 2015;8:2953-93.
3. Kalle M, Karthik MS, Hegde C, Shetty SN, Raghobam K. Enhancement of support for mandibular complete denture prosthesis: A preprosthetic ridge augmentation procedure by distraction osteogenesis. *J Indian Prosthodont Soc* 2009;9:88.
4. Hegde R, Prasad K, Shroff KK. Maxillary sinus augmentation using sinus membrane elevation without grafts – A systematic review. *J Indian Prosthodont Soc* 2016;16:317-22.
5. Patil RC, Kanchan S, Ramanathan K. Immediate implant placement in conjunction with a DFDBA graft and resorbable membrane: A 1-10 year retrospective clinical study. *J Indian Prosthodont Soc* 2005;5:203.
6. Santagata M, Tozzi U, Prisco RV, Tartaro G, D'Amato S. Autologous bone graft harvested during implant site preparation: Histological study. *Plast Aesthetic Res* 2014;1:94.
7. Balaji SM. Augmentation of residual alveolar bone height with tissue engineering for dental implant placement. *Indian J Dent Res* 2014;25:410-2.
8. Yuzbasioglu E, Alkan A, Ozer M, Bayram M. Multidisciplinary approach for the rehabilitation of central giant cell granuloma: A clinical report. *Niger J Clin Pract* 2014;17:528-33.
9. Modabber A, Legros C, Rana M, Gerressen M, Riediger D, Ghassemi A. Evaluation of computer-assisted jaw reconstruction with free vascularized fibular flap compared to conventional surgery: A clinical pilot study. *Int J Med Robot* 2012;8:215-20.
10. Liu XJ, Gui L, Mao C, Peng X, Yu GY. Applying computer techniques in maxillofacial reconstruction using a fibula flap: A messenger and an evaluation method. *J Craniofac Surg* 2009;20:372-7.
11. Foley BD, Thayer WP, Honeybrook A, McKenna S, Press S. Mandibular reconstruction using computer-aided design and computer-aided manufacturing: An analysis of surgical results. *J Oral Maxillofac Surg* 2013;71:e111-9.
12. Moon JW, Sohn DS, Heo JU, Shin HI, Jung JK. New bone formation in the maxillary sinus using peripheral venous blood alone. *J Oral Maxillofac Surg* 2011;69:2357-67.
13. Kim JM, Lee JH, Park IS. New bone formation using fibrin rich block with concentrated growth factors in maxillary sinus augmentation. *J Korean Assoc Oral Maxillofac Surg* 2011;37:278-86.
14. Raghoebar GM, Meijer HJ, Telleman G, Vissink A. Maxillary sinus floor augmentation surgery with autogenous bone grafts as ceiling: A pilot study and test of principle. *Clin Implant Dent Relat Res* 2013;15:550-7.
15. Hidalgo DA. Fibula free flap: A new method of mandible reconstruction. *Plast Reconstr Surg* 1989;84:71-9.
16. Hidalgo DA, Rekow A. A review of 60 consecutive fibula free flap mandible reconstructions. *Plast Reconstr Surg* 1995;96:585-96.
17. Wei FC, Chen HC, Chuang CC, Noordhoff MS. Fibular osteoseptocutaneous flap: Anatomic study and clinical application. *Plast Reconstr Surg* 1986;78:191-200.
18. Foster RD, Anthony JP, Sharma A, Pogrel MA. Vascularized bone flaps versus nonvascularized bone grafts for mandibular reconstruction: An outcome analysis of primary bony union and endosseous implant success. *Head Neck* 1999;21:66-71.
19. Schusterman MA, Miller MJ, Reece GP, Kroll SS, Marchi M, Goepfert H. A single center's experience with 308 free flaps for repair of head and neck cancer defects. *Plast Reconstr Surg* 1994;93:472-8.
20. Gbara A, Darwich K, Li L, Schmelzle R, Blake F. Long-term results of jaw reconstruction with microsurgical fibula grafts and dental implants. *J Oral Maxillofac Surg* 2007;65:1005-9.
21. Olszewski R. Surgical engineering in craniomaxillofacial surgery: A literature review. *J Healthc Eng* 2012;3:53-86.
22. Altobelli DE, Kikinis R, Mulliken JB, Cline H, Lorenson W, Jolesz F. Computer-assisted three-dimensional planning in craniofacial surgery. *Plast Reconstr Surg* 1993;92:576-85.
23. Antony AK, Chen WF, Kolokythas A, Weimer KA, Cohen MN. Use of virtual surgery and stereolithography-guided osteotomy for mandibular reconstruction with the free fibula. *Plast Reconstr Surg* 2011;128:1080-4.
24. Gilbert A. Vascularized transfer of the fibular shaft. *Int J Microsurg* 1979;1:100-2.
25. Ling XF, Peng X. What is the price to pay for a free fibula flap? A systematic review of donor-site morbidity following free fibula flap surgery. *Plast Reconstr Surg* 2012;129:657-74.
26. Metzger MC, Hohlweg-Majert B, Schön R, Teschner M, Gellrich NC, Schmelzisen R, *et al.* Verification of clinical precision after computer-aided reconstruction in craniomaxillofacial surgery. *Oral Surg Oral Med Oral Pathol Oral Radiol Endod* 2007;104:e1-10.
27. Froum SJ, Tarnow DP, Wallace SS, Rohrer MD, Cho SC. Sinus floor elevation using anorganic bovine bone matrix (OsteoGraf/N) with and without autogenous bone: A clinical, histologic, radiographic, and histomorphometric analysis – Part 2 of an ongoing prospective study. *Int J Periodontics Restorative Dent* 1998;18:528-43.
28. Rude K, Thygesen TH, Sørensen JA. Reconstruction of the maxilla using a fibula graft and virtual planning techniques. *BMJ Case Rep* 2014;2014. pii: Bcr2014203601.
29. Vasconcelos Jde A, Avila GB, Ribeiro JC, Dias SC, Pereira LJ. Inferior alveolar nerve transposition with involvement of the mental foramen for implant placement. *Med Oral Patol Oral Cir Bucal* 2008;13:E722-5.
30. Kaing L, Grubor D, Chandu A. Assessment of bone grafts placed

- within an oral and maxillofacial training programme for implant rehabilitation. *Aust Dent J* 2011;56:406-11.
31. Thorwarth M, Schlegel KA, Wehrhan F, Srouf S, Schultze-Mosgau S. Acceleration of de novo bone formation following application of autogenous bone to particulated anorganic bovine material *in vivo*. *Oral Surg Oral Med Oral Pathol Oral Radiol Endod* 2006;101:309-16.
 32. Infante Cossío P, Martínez de Fuentes R, Carranza Carranza A, Torres Lagares D, Gutiérrez Pérez JL. Recurrent central giant cell granuloma in the mandible: Surgical treatment and dental implant restoration. *Med Oral Patol Oral Cir Bucal* 2007;12:E229-32.
 33. Sekine H, Taguchi T, Seta S, Takano M, Takeda T, Kakizawa T. Dental implant treatment with different techniques for sinus floor elevation – A case report. *Bull Tokyo Dent Coll* 2007;48:87-91.
 34. Sawaki M, Ueno T, Kagawa T, Kanou M, Honda K, Shirasu N, *et al.* Dental implant treatment for a patient with bilateral cleft lip and palate. *Acta Med Okayama* 2008;62:59-62.
 35. Contar CM, Sarot JR, Bordini J, Galvão GH, Nicolau GV, Machado MA. Maxillary ridge augmentation with fresh-frozen bone allografts. *Int J Oral Maxillofac Surg* 2009;38:1280-5.
 36. Grecchi F, Mancini G, Parafioriti A, Mineo G, Zollino I, Pricolo A, *et al.* Ectodermal dysplasia treated with one-step surgical rehabilitation: A case report. *Singapore Dent J* 2010;31:9-14.
 37. Cho-Lee GY, Naval-Gías L, Martos-Díaz PL, González-García R, Rodríguez-Campo FJ. Vertical distraction osteogenesis of a free vascularized fibula flap in a reconstructed hemimandible for mandibular reconstruction and optimization of the implant prosthetic rehabilitation. Report of a case. *Med Oral Patol Oral Cir Bucal* 2011;16:e74-8.
 38. Infante-Cossío P, Martínez-de-Fuentes R, García-Perla-García A, Jiménez-Castellanos E, Gómez-Izquierdo L. Myxofibroma of the maxilla. Reconstruction with iliac crest graft and dental implants after tumor resection. *Med Oral Patol Oral Cir Bucal* 2011;16:e532-6.
 39. Fu PS, Wu YM, Tsai CF, Huang TK, Chen WC, Hung CC. Immediate provisional restoration of a single-tooth implant in the esthetic zone: A case report. *Kaohsiung J Med Sci* 2011;27:80-4.
 40. Moon JW, Choi BJ, Lee WH, An KM, Sohn DS. Reconstruction of atrophic anterior mandible using piezoelectric sandwich osteotomy: A case report. *Implant Dent* 2009;18:195-202.
 41. Ahn MR, An KM, Choi JH, Sohn DS. Immediate loading with mini dental implants in the fully edentulous mandible. *Implant Dent* 2004;13:367-72.
 42. Schwartz-Arad D, Ofec R, Eliyahu G, Ruban A, Sterer N. Long term follow-up of dental implants placed in autologous onlay bone graft. *Clin Implant Dent Relat Res* 2016;18:449-61.
 43. Aghaloo TL, Moy PK. Which hard tissue augmentation techniques are the most successful in furnishing bony support for implant placement? *Int J Oral Maxillofac Implants* 2007;22 (Suppl):49-70.
 44. Chiapasco M, Casentini P, Zaniboni M. Bone augmentation procedures in implant dentistry. *Int J Oral Maxillofac Implants* 2009;24 (Suppl):237-59.
 45. Balshi TJ, Wolfinger GJ, Petropoulos VC. Quadruple zygomatic implant support for retreatment of resorbed iliac crest bone graft transplant. *Implant Dent* 2003;12:47-53.
 46. Motamedian SR, Khojasteh M, Khojasteh A. Success rate of implants placed in autogenous bone blocks versus allogenic bone blocks: A systematic literature review. *Ann Maxillofac Surg* 2016;6:78-90.
 47. Shimono K, Oshima M, Arakawa H, Kimura A, Nawachi K, Kuboki T. The effect of growth factors for bone augmentation to enable dental implant placement: A systematic review. *Jpn Dent Sci Rev* 2010;46:43-53.
 48. Chiapasco M, Romeo E, Vogel G. Tridimensional reconstruction of knife-edge edentulous maxillae by sinus elevation, onlay grafts, and sagittal osteotomy of the anterior maxilla: Preliminary surgical and prosthetic results. *Int J Oral Maxillofac Implants* 1998;13:394-9.
 49. Anitua E. Plasma rich in growth factors: Preliminary results of use in the preparation of future sites for implants. *Int J Oral Maxillofac Implants* 1999;14:529-35.
 50. Peleg M, Mazor Z, Garg AK. Augmentation grafting of the maxillary sinus and simultaneous implant placement in patients with 3 to 5 mm of residual alveolar bone height. *Int J Oral Maxillofac Implants* 1999;14:549-56.
 51. You TM, Choi BH, Zhu SJ, Jung JH, Lee SH, Huh JY, *et al.* Platelet-enriched fibrin glue and platelet-rich plasma in the repair of bone defects adjacent to titanium dental implants. *Int J Oral Maxillofac Implants* 2007;22:417-22.
 52. Sjöström M, Sennerby L, Nilson H, Lundgren S. Reconstruction of the atrophic edentulous maxilla with free iliac crest grafts and implants: A 3-year report of a prospective clinical study. *Clin Implant Dent Relat Res* 2007;9:46-59.
 53. Lundgren S, Cricchio G, Palma VC, Salata LA, Sennerby L. Sinus membrane elevation and simultaneous insertion of dental implants: A new surgical technique in maxillary sinus floor augmentation. *Periodontol* 2000 2008;47:193-205.
 54. Hernández-Alfaro F, Sancho-Puchades M, Guijarro-Martínez R. Total reconstruction of the atrophic maxilla with intraoral bone grafts and biomaterials: A prospective clinical study with cone beam computed tomography validation. *Int J Oral Maxillofac Implants* 2013;28:241-51.
 55. Sohn DS, Heo JU, Kwak DH, Kim DE, Kim JM, Moon JW, *et al.* Bone regeneration in the maxillary sinus using an autologous fibrin-rich block with concentrated growth factors alone. *Implant Dent* 2011;20:389-95.

"Quick Response Code" link for full text articles

The journal issue has a unique new feature for reaching to the journal's website without typing a single letter. Each article on its first page has a "Quick Response Code". Using any mobile or other hand-held device with camera and GPRS/other internet source, one can reach to the full text of that particular article on the journal's website. Start a QR-code reading software (see list of free applications from <http://tinyurl.com/yzlh2tc>) and point the camera to the QR-code printed in the journal. It will automatically take you to the HTML full text of that article. One can also use a desktop or laptop with web camera for similar functionality. See <http://tinyurl.com/2bw7fn3> or <http://tinyurl.com/3ysr3me> for the free applications.