

Case Report

Prosthetic rehabilitation of surgically treated orbital defects - evisceration, enucleation, and exenteration: A case series

Anna Serene Babu, V. Manju, Vinod P. Nair, C. Tony Thomas

Departments of Prosthodontics, Amrita School of Dentistry, Kochi, Kerala, India

Abstract

The rehabilitation of a patient who has suffered the psychological trauma due to loss of an eye requires a prosthesis that will provide the optimum cosmetic and functional result. The mode of rehabilitation varies based on the type of defect and surgical approach being adopted. A case series of prosthetic rehabilitation of three types of orbital defects - evisceration, enucleation and exenteration have been reported in this article. The clinical relevance of surgical approaches highlights the preservation of remaining anatomic structures creating a negative space or concavity to aid in future prosthetic rehabilitation. A multidisciplinary management and team approach is essential in providing esthetics and to regain the confidence. Follow-up care for the patient is mandatory.

Key Words: Enucleation, evisceration and exenteration, orbital defects

Address for correspondence:

Dr. Anna Serene Babu, Department of Prosthodontics, Amrita School of Dentistry, Ponekkara, Kochi, Kerala, India. E-mail: annarcher16@gmail.com

Received: 8th June, 2015, **Accepted:** 30th August, 2015

INTRODUCTION

Congenital defects, severe trauma and tumor attribute to the loss of an eye, and subsequent deformity. Defects of the eye can be ocular or orbital. Ocular defects involve only the eyeball, whereas orbital defects include periorbital tissue.^[1] Successful rehabilitation of the defect with orbital prosthesis aims to improve the physical and emotional status of the patient thus ensuring social acceptance.

Surgical procedures adopted for the removal of an eye were classified by Peyman *et al.*, into three general categories: Evisceration (removal of intraocular contents of the globe),

enucleation (removal of the globe and parts of the optic nerve) or exenteration (removal of the entire orbital contents, primarily for eradication of malignant orbital tumors).^[2] The lost orbital volume following surgical resection can be replaced either by surgical reconstruction of soft-tissue or prosthetic rehabilitation by an orbital prosthesis. The prosthesis can be retained by natural undercut of the lids, medical grade adhesives, or osseointegrated extraoral implants.^[3]

This article discusses the prosthetic rehabilitation of patients with three different types of orbital defects and highlights the techniques involved in the fabrication of orbital prosthesis for each type of defect. The evisceration and enucleation

Access this article online	
Quick Response Code: 	Website: www.j-ips.org
	DOI: 10.4103/0972-4052.167947

This is an open access article distributed under the terms of the Creative Commons Attribution-NonCommercial-ShareAlike 3.0 License, which allows others to remix, tweak, and build upon the work non-commercially, as long as the author is credited and the new creations are licensed under the identical terms.

For reprints contact: reprints@medknow.com

How to cite this article: Babu AS, Manju V, Nair VP, Thomas CT. Prosthetic rehabilitation of surgically treated orbital defects - evisceration, enucleation, and exenteration: A case series. *J Indian Prosthodont Soc* 2016;16:216-20.

defects discussed in the case presentations are rehabilitated using intraocular acrylic prosthesis, whereas an extraocular silicone prosthesis retained with an adhesive was the mode of rehabilitation adopted in an exenteration defect. Management of orbital defects by proper diagnosis, treatment planning, and rehabilitation with appropriate maxillofacial prosthesis was expected to improve the function and cosmetic efficiency.

CASE REPORTS

Case 1 (evisceration)

An 18-year-old female patient reported to our Maxillofacial Prosthetic Clinic. She presented with a history of panophthalmitis and had undergone a minimal invasive surgery. The surgical procedure involved removal of the globe contents leaving the sclera intact [Figure 1].

“Evisceration is a form of mutilating surgery involving removal of intraocular contents through an incision in the cornea or sclera. The remaining tissues containing optic nerve, sclera, extraocular muscle, and periorbita are left undisturbed.”^[4] The procedure provides a superior final cosmetic outcome minimally affecting the orbital contents.^[5]

Fabrication of prosthesis

A prefabricated eye shell was selected that perfectly matches the contralateral eye. Selective grinding of the eye shell was performed followed by minimal acrylic relining. The intraocular prosthesis was then inserted to the socket [Figure 2].

Case 2 (enucleation)

A 48-year-old male patient who was a victim of road traffic accident where glass piece penetrated into his eye and a secondary infection developed. The surgical resection procedure involved removal of the entire eyeball severing muscles and optic nerve [Figure 3]. Enucleation removes the entire globe (without opening it) by severing all muscles, nerves, and blood vessels attached to it from the orbit. The most common indications for enucleation are treatment of intraocular malignancies, relief of pain in blind eyes; removal of severely traumatized, deformed, or phthisical eyes without visual potential; and prevention of sympathetic ophthalmia.^[6]

Fabrication of prosthesis

The custom tray was fabricated and impression made with light body polyvinyl siloxane impression material (Aquasil, Dentsply) because of its accuracy in capturing surface details and dimensional stability [Figure 4]. The material was injected slowly into the socket and patient was asked to perform various eye movements to facilitate the flow of impression material into all aspects of the socket. Master cast was poured and wax pattern fabricated with the eye shell in position on the outer surface. After dewaxing heat cure acrylic packed. Prosthesis

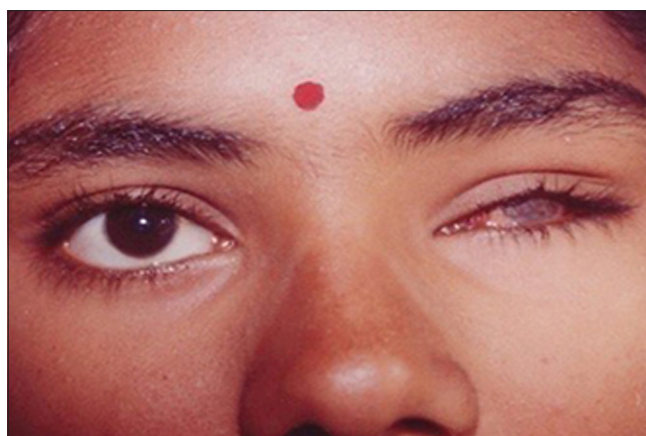

Figure 1: Eviscerated defect



Figure 2: Postrehabilitation

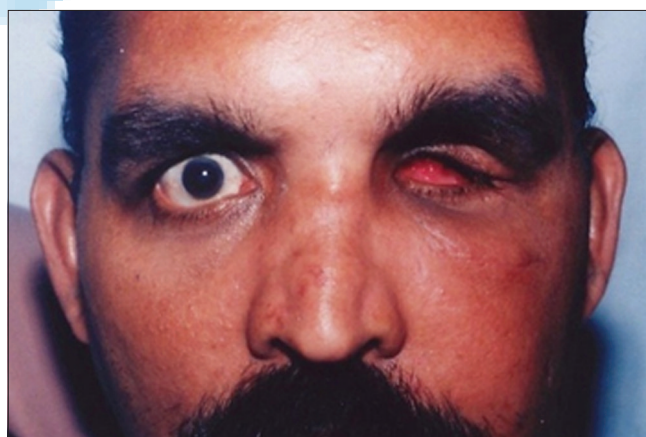

Figure 3: Enucleated defect

recovered after curing; finishing and polishing done to deliver it to the patient [Figures 5 and 6].

Case 3 (exenteration)

This 8-year-old boy reported to our department in 2005 with retinoblastoma of the left eye. The surgical resection involved a radical procedure where in the entire orbital contents; eyelid and surrounding tissue were removed [Figure 7]. After completing

the surgical procedures, the patient was referred to the maxillofacial prosthetic clinic for further management. "Orbital exenteration is a radical procedure consisting of removal of the orbital contents, including orbital fat, conjunctival sac, globe, and part or all of the eyelids. This procedure is indicated in cases of potentially life-threatening malignancies, tumor, trauma, or acid burns or relentlessly progressive conditions unresponsive to other treatments."^[7] Orbital exenteration is classified as total exenteration when all orbital contents including the globe and periorbita are removed and as subtotal when orbital tissue is removed partially with sacrifice of the eye. Extended exenteration are defined as cases that include excision of adjacent bone.^[1]

Surgical modification to enhance prosthetic results in exenteration defects: When the tissue is displaced or deformed, surgical reconstruction yields a more favorable result.^[8] The entire defect should be skin lined to provide a better intaglio surface for the prosthesis. If the prosthesis is the treatment option, sufficient space should be created for retaining the prosthesis in the socket. A postsurgical conformer prevents the cul-de-sac from shrinking thus maintaining adequate space. Once the wound is healed properly, silicon prosthesis can be inserted.^[9]

Fabrication of silicon prosthesis

The impression of the defect is made with light viscosity polyvinyl siloxane and supported with plaster of Paris. The cast is then retained, and the wax pattern is sculpted with care. The edge of the wax pattern is made thin to merge with the remnant surrounding soft tissue [Figure 8]. Recontouring of the wax segment that represented the palpebral fissure was done to attain a smooth convex surface. A prefabricated eye shell was selected which matched with the shade of the contralateral eye. The landmarks were determined to position the iris by making the patient look straight. During the trial, the wax pattern was placed into the patient's socket and modified as that of the contralateral eye.

The wax pattern with the master cast is then invested. When the flask is opened after dewaxing procedure, the eye shell is secured firmly to a single component of the flask. Room temperature vulcanization silicone (A-2186, Factor II incorporated) was packed into the mold with intrinsic stains. After curing, recover the prosthesis followed by extrinsic staining to match the skin colour and eyelashes were attached using patient's own hair. The extraoral silicone prosthesis was delivered to the patient

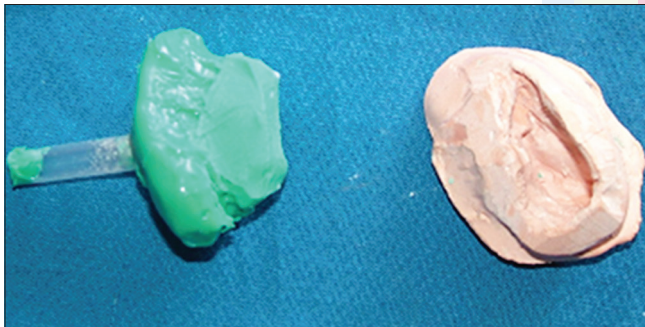

Figure 4: Impression and cast



Figure 5: Prosthesis

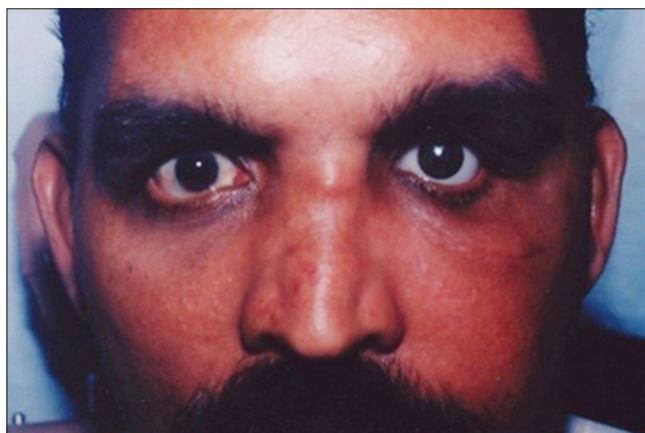

Figure 6: Rehabilitation with intraoral acrylic prosthesis

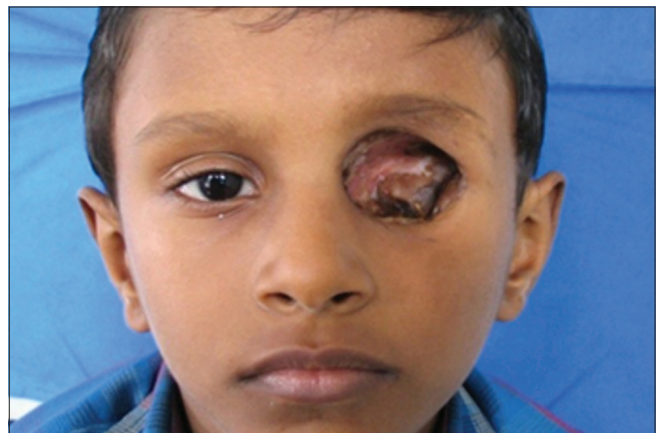

Figure 7: Exenterated defect

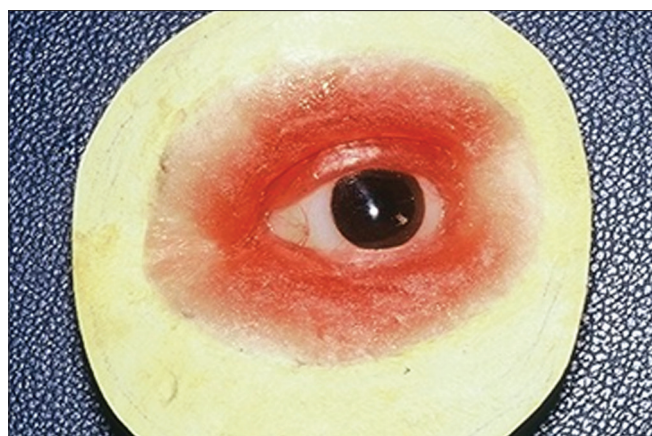


Figure 8: Wax pattern

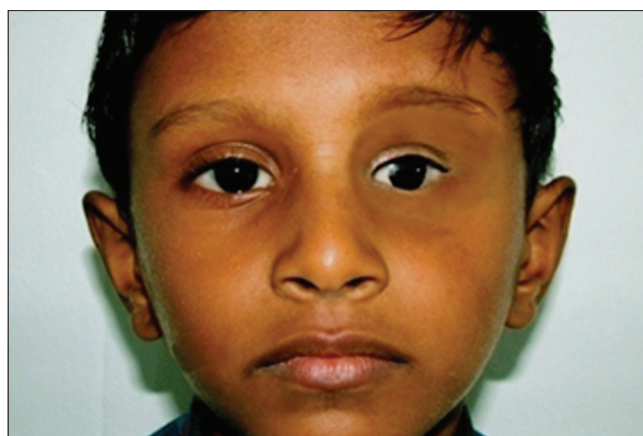

Figure 9: Rehabilitation with silicone prosthesis

after finishing and polishing. The retention of prosthesis was achieved using Daro Hydro Bond adhesive (Factor II incorporated) [Figure 9].

Maintenance of the prosthesis

The patients were given instructions regarding the maintenance and use of adhesives. Home care protocol includes handling the prosthesis with clean hands and cleaning using disinfectant solution. Removal of the prosthesis during night is required. Recall visits were advised every year for routine polishing of prosthesis to prevent deposition of protein and bacteria.

DISCUSSION

The techniques discussed in the above-reported cases ensure that prosthetic rehabilitation restore the patient anatomy as normal as possible and helped the patient to regain the self-confidence assuring an improvement in the quality of life.

An accurate impression reproducing the details of the defect is the prime requisite for a successful prosthesis. A selection of ideal maxillofacial prosthetic material and reliable retentive aid paves the way for a better aesthetic and functional outcome. Since 1960, Medical grade silicone remains superior to other maxillofacial prosthetic materials due to their desirable material properties including flexibility, biocompatibility and ability to accept intrinsic and extrinsic colorants, chemical and physical inertness, and ease to mould.^[10]

In the present case reports with evisceration and enucleated defects, a prefabricated eye shell was used for the prosthetic rehabilitation. An alternative technique involves fabrication of prosthesis using a combination of iris button from the prefabricated eye and customized scleral portion from the impression of the socket.^[11]

The mode of retention of the prosthesis can be either by adhesives or with implants. Orbital implants provide reliable

retention and improved postoperative cosmetic result by filling the orbital volume and also reducing the chance of socket contractions due to scar tissue formation.^[12] However, in cases where the bone density is less and bone growth is incomplete, adhesive retained prosthesis is the preferred option. For implant supported orbital prosthesis, magnetic attachment is the preferred mode as it requires minimum space (can be used in shallow regions), strong attractive force at placement time, simpler hygiene maintenance, and ease to locate. However, the disadvantages reported include its corrosive nature and need for encapsulation with an inert material.

CONCLUSION

The present clinical works reported the surgical interventions such as evisceration, enucleation and exenteration; and prosthetic rehabilitation of such defects. For evisceration and enucleation defects, intraocular acrylic prostheses given; whereas for exenteration defect adhesive retained extraocular silicon prosthesis given. A multidisciplinary approach with proper diagnosis and treatment planning will help to improve the overall quality of life of the patient. The prime factors that need to be considered for a final outcome include surgical modifications to enhance the prosthetic rehabilitation; accurate impression of the defect should be made, selection of proper material, and technique for the fabrication of prosthesis. This helps to recover confidence and self-esteem in today's cosmetically challenging world.

Declaration of patient consent

The authors certify that they have obtained all appropriate patient consent forms. In the form the patient(s) has/have given his/her/their consent for his/her/their images and other clinical information to be reported in the journal. The patients understand that their names and initials will not be published and due efforts will be made to conceal their identity, but anonymity cannot be guaranteed.

Financial support and sponsorship


Nil.

Conflicts of interest

There are no conflicts of interest.

REFERENCES

1. Ben Simon GJ, Schwarcz RM, Douglas R, Fiaschetti D, McCann JD, Goldberg RA. Orbital exenteration: One size does not fit all. *Am J Ophthalmol* 2005;139:11-7.
2. Peyman GA, Sanders DR, Goldberg MF. Principles and Practice of Ophthalmology. Vol. 3. 1st Indian ed. New Delhi: Jaypee Bros; 1987. p. 2.
3. Supriya M, Ghadiali B. Prosthetic rehabilitation of a patient with an orbital defect using a simplified approach. *J Indian Prosthodont Soc* 2008;8:116-8.
4. Levine MR, Fagien S. Enucleation and evisceration. In: Stewart WB, editor. Surgery of the Eyelids, Orbit and Lacrimal System. Ophthalmology Monographs. Vol. 3. American Academy of Ophthalmology; 1995. p. 8.
5. Shore JW. Evisceration. In: Levine MR, editor. Manual of Oculoplastic Surgery. New York: Churchill Livingstone; 1988. p. 189-94.
6. Nunnery WR, Ng JD, Hertzler KJ. "Enucleation and Evisceration." In: Spaeth G, editor. Ophthalmic Surgery: Principles and Practice. 3rd ed. Philadelphia, PA: Elsevier; 2003. p. 485-507.
7. Rahman I, Cook AE, Leatherbarrow B. Orbital exenteration: A 13 year Manchester experience. *Br J Ophthalmol* 2005;89:1335-40.
8. Manju V. Prosthetic rehabilitation of facial defect with silicone prosthesis. *KDJ* 2009;32:154-5.
9. Amornvit P, Rokaya D, Shrestha B, Srithavaj T. Prosthetic rehabilitation of an ocular defect with post-enucleation socket syndrome: A case report. *Saudi Dent J* 2014;26:29-32.
10. Maller US, Karthik KS, Maller SV. Maxillofacial prosthetic materials – Past and present trends. *J Indian Acad Dent Spec* 2010;1:25-30.
11. Devaraju K, Gopalkrishna H, Rao S. Ocular prosthesis. A unique method, for post evisceration ocular defect. *Eur J Prosthodont* 2014;2:86-8.
12. Bairo F, Perero S, Ferraris S, Miola M, Balagna C, Verné E, *et al.* Biomaterials for orbital implants and ocular prostheses: Overview and future prospects. *Acta Biomater* 2014;10:1064-87.



"Quick Response Code" link for full text articles

The journal issue has a unique new feature for reaching to the journal's website without typing a single letter. Each article on its first page has a "Quick Response Code". Using any mobile or other hand-held device with camera and GPRS/other internet source, one can reach to the full text of that particular article on the journal's website. Start a QR-code reading software (see list of free applications from <http://tinyurl.com/yzh2tc>) and point the camera to the QR-code printed in the journal. It will automatically take you to the HTML full text of that article. One can also use a desktop or laptop with web camera for similar functionality. See <http://tinyurl.com/2bw7fn3> or <http://tinyurl.com/3ysr3me> for the free applications.