

Case Report

Rehabilitation of resorbed mandibular ridges using mini implant retained overdentures: A case series with 3 year follow-up

Pooja Kumari, Mahesh Verma, Vikrant Sainia¹, Rekha Gupta, Shubhra Gill

Department of Prosthodontics, Crown and Bridge, Maulana Azad Institute of Dental Sciences, ¹Department of Periodontics, NDMC Hospital, Chanakya Puri, New Delhi, India

Abstract

With the increasing average life expectancy of human beings, the need to cater geriatric patients is ever increasing. Complete dentures are an indispensable tool in this regard. The loose and unstable lower complete denture owing to residual ridge resorption is one of the most common problems faced by edentulous patients. Dental implant retained overdentures have emerged as an efficient treatment modality for such patients. Though useful, not every patient is a suitable candidate to go for conventional implant-borne prosthesis, limitation being the available bone width. In such cases, mini implants may be used for augmenting the retention of the dentures and improving the quality of life of patients. In this case series, rehabilitation of three compromised cases with mini implant retained overdentures have been described wherein patients are experiencing instability of lower denture due to thin resorbed mandibular ridges. In one of the cases, three mini implants placed in A, C, and E position were splinted using a cemented bar to retain the mandibular denture. The other two cases were rehabilitated using unsplinted ball type one piece mini implants placed in A, C, and E position in one case and B and D position in another case. Though splinted bar design should be preferred but the lack of available vertical space precluded the utilization of bar in other two cases. The results were found to be satisfactory with no complications reported during a follow-up period of over 3 years in all the cases.

Key Words: Complete denture, dental implant, mini-implants, overdentures, retention

Address for correspondence:

Dr. Pooja Kumari, Department of Prosthodontics, Crown and Bridge, Maulana Azad Institute of Dental Sciences, New Delhi - 110 002, India.

E-mail: pooja_pathak4@yahoo.in

Received: 22th July, 2015, Accepted: 08th September, 2015

INTRODUCTION

According to the World Health Organization, edentulism has an important adverse impact on the individual and, in some cultures, on the community, as well (World Health

Organization, 2000). Complete dentures have been playing the important role of oral rehabilitation of these compromised groups of patients but they have their own limitations. Patients

Access this article online	
Quick Response Code: 	Website: www.j-ips.org
	DOI: 10.4103/0972-4052.167948

This is an open access article distributed under the terms of the Creative Commons Attribution-NonCommercial-ShareAlike 3.0 License, which allows others to remix, tweak, and build upon the work non-commercially, as long as the author is credited and the new creations are licensed under the identical terms.

For reprints contact reprints@medknow.com

How to cite this article: Kumari P, Verma M, Sainia V, Gupta R, Gill S. Rehabilitation of resorbed mandibular ridges using mini implant retained overdentures: A case series with 3 year follow-up. J Indian Prosthodont Soc 2016;16:221-6.

usually get easily adapted to the maxillary denture, but the mandibular denture has its own share of problems to cope up with. Some of these could be attributed to resorption of the bone, as well as the movement of the tongue, cheek, and lips leading to instability of the denture. Even the denture-wearers who can wear an upper denture without problems often have difficulties eating with the lower denture.

Implant retained and supported overdentures have evolved as a potential solution to the problem of stability and retention of the complete dentures. It has been shown that implants significantly reduce the amount of bone loss, denture instability, pain, and sore spots, leading to improved masticatory efficiency. Patients treated with implant overdentures have shown higher levels of satisfaction than patients wearing conventional dentures.^[1] The overwhelming evidence in support of implant overdentures led to the McGill consensus statement and, more recently, to the York consensus statement, both of which declare that mandibular two-implant overdentures be considered “as the first choice standard of care for edentulous patients.”^[2,3]

If implant retained overdentures are the treatment of choice, then one major requirement will be the available bone at the edentulous site which is often limited due to bone loss during extraction or resorption over time. Some residual ridges are very thin and will not accept a standard diameter (3.75–4.1 mm) implant without site development. Often, grafting procedures can be accomplished if the patient desires this form of treatment. If bone grafting is planned for implant placement, then there is some debate as to the true supportive quality of grafted bone.

In such compromised situations, narrow diameter implants can be used instead of regular diameter implants and additional cost and surgical intervention can be avoided. There is small diameter implants available in a range from 3.0 to 3.3 mm. Furthermore, available are very small or “mini” 1.8 to 2.5 mm diameter implants. These mini implants can provide a solution in challenging edentulous clinical situations having limited bone volume. The added advantage of immediate loading of the mini implants, reduced cost factor, reduced overall treatment time; avoidance of repeated surgical procedures and associated complications also makes it a treatment of choice for the elderly edentulous patients.

Usually, ball attachments are being used when we are using mini implants to retain overdentures, because the bone to implant contact area is smaller in case of mini implants and also they are mechanically weak due to smaller surface area, so to further increase the clinical longevity of the prosthesis, they should preferably be splinted using bar type attachment. The lateral forces exerted over the mini implants can be significantly

reduced if we are choosing the splinted bar design to retain the overdentures.^[4] Furthermore, there is reduced marginal bone loss in splinted mini-implants in comparison to the nonsplinted ball attachments.^[5]

This case series describes rehabilitation of three patients with mini implant retained overdentures in the mandibular arch to solve the problems of reduced retention and stability. The mini implants were used only for the lower arch, first, because the retention is usually not that big a problem for maxillary arch as it is for the mandibular arch. Second, the survival rates and health status are better for mini implant retained overdentures applied in the mandible than for those applied in the maxilla.^[6] The significance of this case series is that both the unsplinted ball and splinted bar type attachments have been used depending upon the clinical condition, and all the reported cases have a minimum 3 years follow-up period. Though preference was given to the splinted bar attachment, but ball attachments were chosen when available vertical space was an issue.

CASE REPORTS

Case 1

A 61-year-old edentulous woman, wearing complete dentures for last 13 years, presented with a complaint of the looseness of a lower denture. On examination, the mandibular residual ridge was found to be highly resorbed. The residual alveolar ridge had adequate height, but the width was < 5 mm. Standard diameter implants would not fit in the space available without ridge augmentation procedure. Mini-implant retained overdenture with unsplinted implants having individual ball attachments was planned to augment the retention of a lower denture. Ball attachment was selected instead of bar and clip attachment due to the limitation of vertical space. The placement of 2.5 mm diameter implants in A, C, and E positions were planned.

The surgery was carried out under infiltration anesthesia, and a full thickness flap was raised using a mid-crestal incision. Duplicated denture was modified and used as a positional guide for implant insertion. Osteotomy site preparation was done using just the lance drill and 1.8 mm diameter pilot drill. Rotary insertion of the two mini implants of dimension 2.5 mm × 13 mm at A and C position and 2.5 mm × 10 mm at C position was done. (MS implant denture, Osstem, South Korea, Lot: FMN11C002, FMN11C004) were done using torque controlled ratchet device till a torque of 40 Ncm was reached. The flap was sutured using 3-0 silk sutures [Figure 1a and b]. The patient was instructed in after-care and advised not to use the lower denture till the soft-tissue healing was complete. After 1-week, the lower denture was generously relieved to seat over the ball abutments

and lined with soft-tissue conditioner (Viscogel, Dentsply, Germany). The patient was instructed well about the usage and maintenance of the denture in the healing phase.

An integration phase of 14 weeks was observed, whereupon patient returned for the incorporation of the retentive components. Radiographic examination was done to assess the status of implants [Figure 2] and it was found to be satisfactory as no thread loss was observed. Tissue conditioner was removed from the denture. Nylon O-rings and metal housings were picked up in the denture in a chair side procedure using self-cure acrylic resin [Figure 3a and b]. The patient has successfully functioned with the prosthesis with no complications for 3 ½ years.

Case 2

A 47-year-old completely edentulous woman presented with highly resorbed mandibular ridge leading to compromised retention of the lower denture. The width of the bone was inadequate in the interforaminal region. With the patient's consent, mini implant retained over denture with bar and clip attachment was planned. Bar and clip attachment was preferred as it allows rigid splinting of the implants and the available vertical space to accommodate it was found to be satisfactory. Three mini implants (MS implant narrow ridge, Osstem, South Korea, Lot: FMN11C009) of crown and bridge type having dimensions of 2.5 × 13 were placed in B, C, and D positions in the interforaminal region after raising full thickness flap. Nonresorbable silk suture was used for flap approximation, and simple interrupted sutures were given. On the day of the surgery itself, the implants were prepared to reduce the height of the abutments to around 3 mm in height and an impression was made in a stock tray using irreversible hydrocolloid material for fabrication of primary cast. The mandibular denture was relieved on the intaglio surface and was relined with tissue conditioner (Viscogel, Dentsply, Germany). Patient was recalled after one week for suture removal. Also in this visit, a final impression of the prepared abutments was made using custom tray that was fabricated over the primary cast. The impression was made using polyether impression material (Impregum™ Polyether MB, 3M ESPE, US) for fabrication of cementable bar. The bar was fabricated over the implant abutments using castable Hader bar plastic pattern (Rhein 83, Item code-0220BB). Two weeks postsurgery, implants were splinted with cementable Hader bar [Figures 4 and 5]. The bar was luted in place using self-adhesive resin cement (RelyX™ U200, 3M ESPE). The denture was cleaned of previously loaded tissue conditioner material, and additional space was created for the bar and it was again relined with tissue conditioner. The patient was kept on a regular follow-up and after 15 weeks of healing phase, the clip was incorporated in the denture over the cemented Hader bar using self-cure acrylic resin through

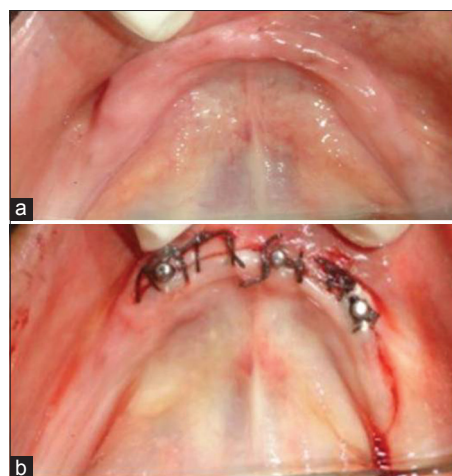


Figure 1: (a) Intraoral occlusal view showing atrophic mandibular ridge. (b) Three one-piece mini implants with ball abutments inserted

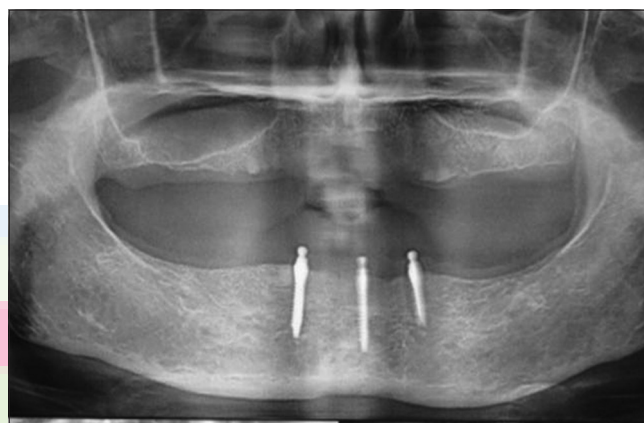


Figure 2: Orthopantomogram showing osseointegrated implants after 14 weeks of surgery

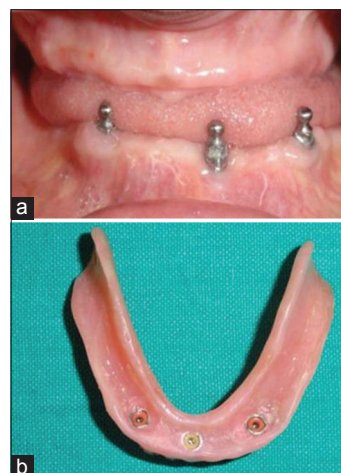


Figure 3: (a) The three mini implants after 14 weeks of the healing period. (b) Retention elements (nylon rings) picked up in the lower denture using a chairside procedure

a chairside reline procedure. The positions of implants lead to fabrication of nonlinear bar. Only one clip was used as the use of multiple clips would reduce the prosthetic mobility

considerably on such nonlinear bar. Patient has been using the prosthesis satisfactorily since last 3 years.

Case 3

Another 53-year-old female patient was rehabilitated using mini implant retained mandibular overdenture. Two mini implants of dimensions 2.5 mm length and 13 mm length (MS implant denture, Osstem, South Korea, Lot: FMNIOJ009) with ball attachments were used and they were placed in B and D region [Figure 6]. The implants were immediately loaded as done in previous cases. After 3 months of healing phase, denture was prepared to receive the nylon O-rings and metal housing. There is associated 3-year follow-up of uneventful usage of the overdenture by the patient.

DISCUSSION

Though dentistry has evolved a lot in last few decades, but the problem of retention associated with the conventional complete denture given in compromised residual ridges still persists. Dental implant retained overdentures have proven to be a satisfactory treatment option to enhance the retention of dentures, but there are obvious limitations associated with this therapy.

Conventionally used regular diameter implants cannot be used if the bone volume is not sufficient, or bone augmentation can either not be performed or has failed. In such cases very small diameter mini implants can be used to retain overdentures.

There may be certain physiologic advantages of mini implants over wider implants. Due to very small osteotomy prepared, the blood supply at the osseous crest is not remarkably compromised as it happens with the larger implant causing the characteristic resorption to the first thread phenomenon seen with them. This phenomenon does not seem to be prevalent with the narrow diameter implants.^[7,8] Also mini implant retained overdentures are naturally subjected to immediate gradual bone loading due to one piece nature of the implant and abutment. According to Wolff's Law, gradual bone loading is associated with superior bone healing.^[9,10] In the presented cases, bone loss around the implants as evident from the orthopantomograph were found to be almost negligible, as seen in the orthopantomogram made after 3 years of placement in the patient restored with splinted bar retained prosthesis [Figure 7]. Also the survival rate of small-diameter implants appears to be similar to that of regular diameter implants.^[11]

One of the possible concerns related to mini implants is the smaller surface area and volume that places more force per square millimeter against the encasing bone. Keeping this in mind, they are indicated in areas having a favorable bone density of type I, II or III. However, the less dense bone may require the use of longer mini implants to resist occlusal forces

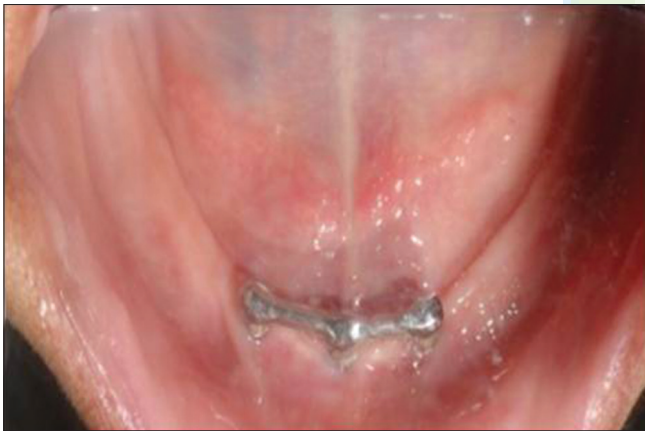

Figure 4: Three mini implants placed in B, C, and D position splinted together with bar attachment

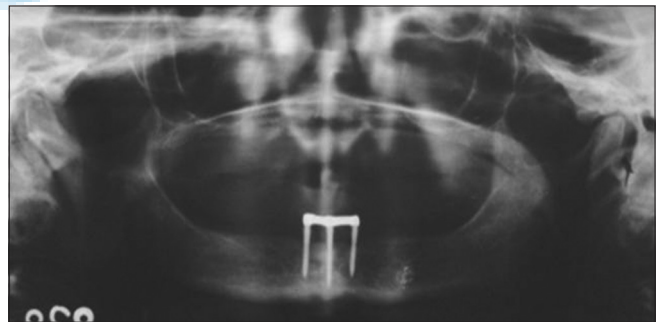


Figure 5: Orthopantomogram showing the splinted mini implants after osseointegration phase

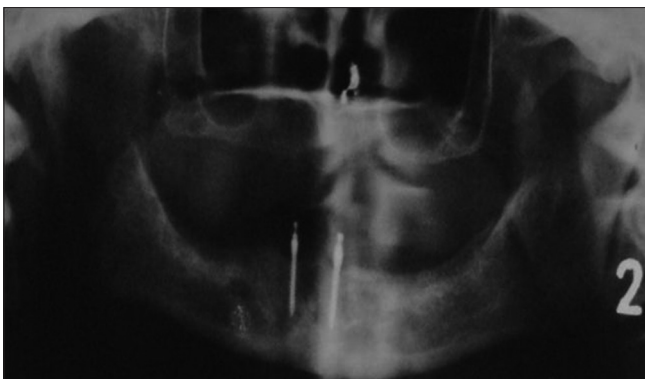


Figure 6: Orthopantomogram showing two mini implants placed in B and D position

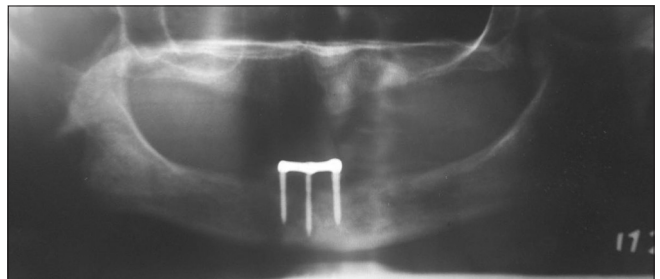


Figure 7: Orthopantomogram showing maintenance of marginal bone level around the splinted mini implants after 3 years of placement

and present less per square millimeter of bone compression during service.^[7]

Also because of the smaller surface area of the implant body, metal fatigue leading to implant fracture can happen if insertion torque is too high.^[7] To avoid complications related to implant overloading, fatigue and fracture, multiple mini implants should be used and they should be splinted if possible.^[4] Hence, they are ideally not suited for patients with bruxism and parafunctional activity due to high uncontrolled forces seen in them.

Though the advantages and satisfactory success rate pertaining to mini implant usage has been documented in the recent literature,^[7,8,11] there is scarcity of data related to long-term usage of mini implants for rehabilitation of edentulous patients. Most of the documented cases have a limited follow-up period of <3 years and also they have chosen the nonsplinted, individual ball abutments to retain the overdentures,^[12] which should not be technically preferred over the splinted bar retained design.^[4,5]

In this case series, we have described a case wherein the mini implants have been splinted using a Hader bar to retain the mandibular overdenture and also the follow-up period of discussed cases is more than 3 years.

Two of the discussed cases have been rehabilitated with three mini implants each and one with two implants for retaining the mandibular complete denture. Though splinting of mini implants is recommended but due to limitation of the available prosthetic space, nonsplinted ball abutment retained overdenture was given in two of the cases. In the second case, splinting of the mini implants was performed using bar and clip attachment. As these implants are available in one piece system, so crown and bridge type implant was chosen, and its abutment was prepared to receive a casted cemented bar. Also only one clip was used to retain the denture because incorporation of two clips on a nonlinear bar splinting three implants would reduce the prosthetic mobility considerably. In all the cases, the patient response was very satisfactory and there was no complication reported over an average follow-up period of 3 years.

Clinical significance

Multiple mini implants either used individually or in splinted form offers improved retention and function of the complete dentures, especially the lower denture. Because the surgical placement of mini implants is much less traumatic as compared to standard sized implants, they may be useful for medically compromised or elderly patients. Also the financial constraints might not allow the patient to undergo the conventional implant treatment procedure. In such cases, mini implants can be used

for augmenting the retention of the dentures and improving the quality of life of patients. Though the surface area is smaller for these implants, maintenance of marginal bone level around them has been found to be better and their survival rate has been found to be similar to that of the regular diameter implants. Thus, it is our role to promote the development and testing of low cost, minimally invasive implant therapies. Though the follow-up associated with the discussed cases is relatively short, but the satisfactory outcome should encourage their further study and usage.

CONCLUSION

In selected edentulous complete denture wearers having poor bone volume, multiple very small diameter, or mini, implants may be used to retain the dentures. This therapy increases the comfort and satisfaction of the patients with minimal investment in terms of time as well as money.

Financial support and sponsorship

Nil.

Conflicts of interest

There are no conflicts of interest.

REFERENCES

1. Stellingsma K, Bouma J, Stegenga B, Meijer HJ, Raghoobar GM. Satisfaction and psychosocial aspects of patients with an extremely resorbed mandible treated with implant-retained overdentures. A prospective, comparative study. *Clin Oral Implants Res* 2003;14:166-72.
2. Feine JS, Carlsson GE, Awad MA, Chehade A, Duncan WJ, Gizani S, *et al.* The McGill consensus statement on overdentures. Mandibular two-implant overdentures as first choice standard of care for edentulous patients. Montreal, Quebec, May 24-25, 2002. *Int J Oral Maxillofac Implants* 2002;17:601-2.
3. Thomason JM, Feine J, Exley C, Moynihan P, Müller F, Naert I, *et al.* Mandibular two implant-supported overdentures as the first choice standard of care for edentulous patients – The York consensus statement. *Br Dent J* 2009;207:185-6.
4. Takagaki K, Gonda T, Maeda Y. Lateral forces exerted through ball or bar attachments in relation to the inclination of mini-implant underneath overdentures: *In vitro* study. *Clin Oral Implants Res* 2015;26:1060-3.
5. Jofre J, Cendoya P, Munoz P. Effect of splinting mini-implants on marginal bone loss: A biomechanical model and clinical randomized study with mandibular overdentures. *Int J Oral Maxillofac Implants* 2010;25:1137-44.
6. Preoteasa E, Imre M, Preoteasa CT. A 3-year follow-up study of overdentures retained by mini-dental implants. *Int J Oral Maxillofac Implants* 2014;29:1170-6.
7. Flanagan D. Fixed partial dentures and crowns supported by very small diameter dental implants in compromised sites. *Implant Dent* 2008;17:182-91.
8. Tarnow D, Elian N, Fletcher P, Froum S, Magner A, Cho SC, *et al.* Vertical distance from the crest of bone to the height of the interproximal papilla between adjacent implants. *J Periodontol* 2003;74:1785-8.
9. Roberts WE, Garetto LP, DeCastro RA. Remodeling of devitalized bone threatens periosteal margin integrity of endosseous titanium implants with threaded or smooth surfaces: Indications for provisional loading and axially directed occlusion. *J Indiana Dent Assoc* 1989;68:19-24.

10. Misch CE. Density of bone: Effect on treatment plans, surgical approach, healing, and progressive boen loading. *Int J Oral Implantol* 1990;6:23-31.
11. Sohrabi K, Mushantat A, Esfandiari S, Feine J. How successful are small-diameter implants? A literature review. *Clin Oral Implants Res* 2012;23:515-25.
12. Scepanovic M, Calvo-Guirado JL, Markovic A, Delgado-Ruiz R, TodorovicA, Milicic B, *et al.* A 1-year prospective cohort study on mandibular overdentures retained by mini dental implants. *Eur J Oral Implantol* 2012;5:367-79.

