

# Classification system on the selection of number of implants and superstructure design on the basis available vertical restorative space and interforaminal distance for implant supported mandibular overdenture

Akshay Bhargava, Manoti Sehgal<sup>1</sup>, Sharad Gupta, Praful Mehra

Department of Prosthodontics, Institute of Technology and Sciences, Centre for Dental Studies and Research, Ghaziabad, Uttar Pradesh, <sup>1</sup>Department of Prosthodontics, Faculty of Dental Sciences, SGT University, Gurgaon, Haryana, India

## Abstract

**Purpose:** The rehabilitation of the edentulous mandible is a challenge due to various limiting factors, of which the available vertical restorative space (AVRS) has been well understood in the literature. However, other anatomic variations such as arch form, arch size, and also the interforaminal distance (IFD) (due to the presence of mandibular nerve) are influential in the selection of size and position of implants, and thereby the prosthetic design. **Materials and Method:** In the present study, 30 edentulous patients from a group of 300 edentulous patients, representing all the three jaw relations (Class I, II, and III) were evaluated for designing a classification that could help in a comprehensive treatment plan for the edentulous mandible. Dental panoramic radiographs of each individual with a trial or final prosthesis were made. The horizontal IFD and AVRS values were calculated. **Results:** One-way analysis of variance followed by *post-hoc* test (multiple comparison) and Bonferroni method having  $P < 0.05$  as significant value showed an overall mean of 38.9 mm for horizontal distance and 13.69 mm for the AVRS in 30 edentulous patients. **Conclusion:** The results showed that in the majority of cases (90%) there is insufficient space to place a bar attachment supported by five implants for mandibular overdentures. This suggests that a universal treatment plan cannot be followed due to varying anatomic factors. Hence, it becomes imperative to have a set of clinical guidelines based on the AVRS and IFD, for the selection of implant number and type of attachment. The article proposes a simple classification system based on the AVRS and IFD for establishing guidelines in the treatment planning of the edentulous mandible, to aid in selection of implant size, number, and position along with the associated prosthetic design.

**Key Words:** Attachment, available vertical restorative space, implant, interforaminal distance, mandibular overdenture

## Address for correspondence:

Dr. Manoti Sehgal, 1225/19 Hari Nagar, Rohtak - 124 001, Haryana, India. E-mail: manoti.02@gmail.com

Received: 09<sup>th</sup> January, 2015, Accepted: 04<sup>th</sup> October, 2015

Access this article online	
Quick Response Code:	Website: <a href="http://www.j-ips.org">www.j-ips.org</a>
	DOI: 10.4103/0972-4052.176541

This is an open access article distributed under the terms of the Creative Commons Attribution-NonCommercial-ShareAlike 3.0 License, which allows others to remix, tweak, and build upon the work non-commercially, as long as the author is credited and the new creations are licensed under the identical terms.

For reprints contact: [reprints@medknow.com](mailto:reprints@medknow.com)

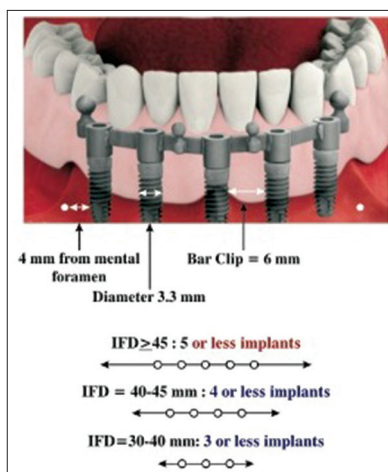
**How to cite this article:** Bhargava A, Sehgal M, Gupta S, Mehra P. Classification system on the selection of number of implants and superstructure design on the basis available vertical restorative space and interforaminal distance for implant supported mandibular overdenture. J Indian Prosthodont Soc 2016;16:131-5.

## INTRODUCTION

An implant overdenture requires an adequate amount of three-dimensional space for accommodating implant superstructures/attachments to enhance retention and stability. In edentulous patients, this space is bounded by the proposed occlusal plane, denture bearing tissues of the edentulous jaw, facial tissues (cheeks and lips), and the tongue. Lack of space can result in fracture of the acrylic resin, esthetic problems, and other technical problems.<sup>[1]</sup> Various techniques can be employed during the diagnosis and treatment planning phase, to assess and accurately, calculate the available interarch distance at the correct vertical dimension of occlusion. These include (a) Assessment of properly articulated diagnostic or master casts, (b) diagnostic wax-up of the planned prostheses, and (c) evaluation of existing interim or immediate conventional dentures.

For designing mandibular overdentures, the anterior mandible can be divided into five positions (from left first premolar to right first premolar), namely A, B, C, D, and E.<sup>[2]</sup> Implants are placed in these positions depending upon the arch size, jaw relation, interforaminal distance (IFD), and the available vertical restorative space (AVRS). For the placement of five implants with a minimum diameter of 3.3 mm in the mandibular interforaminal region, the space requirement for five implants needs to be approximately 44.5–48.5 mm [Figure 1], i.e., a 2 mm safe space from mental foramina; further, sometimes if there is a loop of inferior alveolar nerve, then additional 2 mm is needed as a safety distance from the mental nerve (4 mm); if a bar clip is to be placed, an interimplant distance of 6 mm is required for the clip accommodation, similarly for a bar superstructure with clips, the vertical space requirement is at least 15 mm from the alveolar crest [Figure 2].

Accommodating the bars as compared to other attachments (balls or magnets) is often problematic due to reduced IFD and insufficient vertical space. It was observed in our study on



**Figure 1:** Interforaminal distance aiding the selection of number of implants for implant supported mandibular overdenture

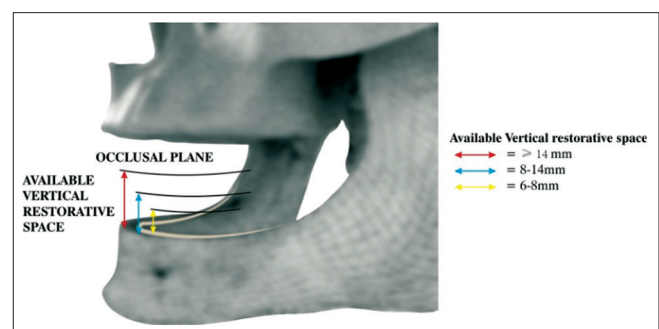
subjects from the Indian population with edentulous mandible, the available horizontal space (38.9 mm, interforaminal) and AVRS (13.69 mm) is lesser than that observed and reported in the Western population.<sup>[2]</sup>

With this aforementioned in mind, the aim of the present study was to calculate the IFD and vertical space availability and devise a classification system based on the AVRS and IFD for establishing guidelines in the treatment planning of edentulous mandible, to aid in selection of implant size, number, and position along with the associated prosthetic design [Table I].

## MATERIALS AND METHODS

Ethical approval for the study was granted by the Dental College and Hospital Institutional Ethical Committee. Three hundred edentulous subjects were studied, and complete denture of these patients were fabricated. Based upon the jaw relation, they were further segregated into Class I (45%), Class II (31%), and Class III (24%). Out of each class, 10 patients were randomly selected for the study, who fulfilled the inclusion criteria (completely edentulous patients between age group of 50 and 65 years, edentulous span of 6 months to 1 years, first time denture wearer, and nonsmoker) and exclusion criteria (the subjects with any systemic disease related to bone metabolism and on medication effecting bone turnover were excluded).

In each edentulous subject, jaw relation and type of mandibular arch form were analyzed and recorded during the fabrication of complete denture. Radio-opaque material, i.e., gutta-percha points were attached on incisal surface of the mandibular acrylic teeth from the distal surface of left mandibular canine to right canine. Two ball bearing of 3 mm diameter were placed on upper and lower denture, to check the magnification error and the relative error was neutralized for each case [Figure 3]. The patients were asked to wear a prosthesis, and panoramic radiographs were obtained (Planmeca Proline (EC), Model No. 00880, Helsinki Finland, 2002). Images were recorded using the radiographic digital screen, which was later digitalized by placing in the Vista scanner (VistaScan Combi+, Model No.

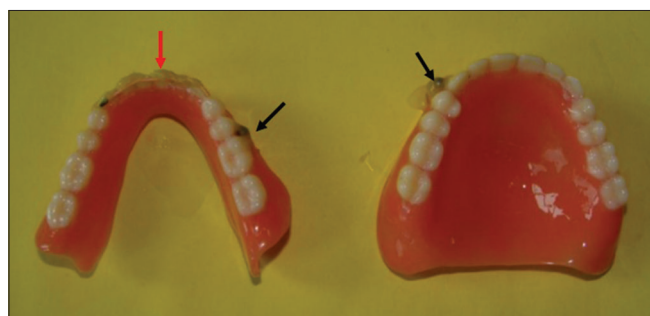


**Figure 2:** Available vertical restorative space aiding the selection of type of superstructure for implant supported mandibular overdenture

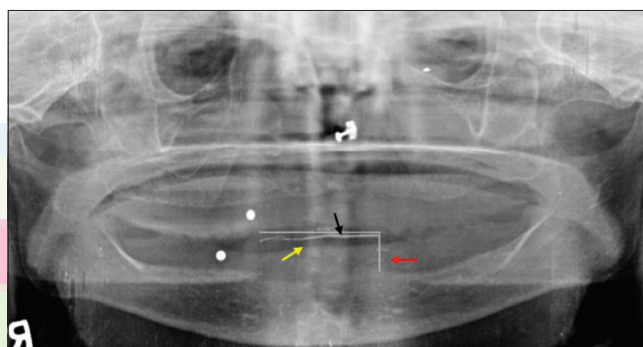
**Table 1: Classification system for selection of number of implants and superstructure selection on the basis (AVRS and IFD) for implant supported mandibular overdenture**

Groups	Subdivision on the basis of AVRS and IFD	Number of implants	Super structure selection		Positioning of implants
			Primary option	Secondary options	
Class I	Class Ia AVRS ≥ 14 mm IFD ≥ 40 mm	05 or less	Bar + locators	Bar and clip	A, B, C, D, E
	Class Ib AVRS ≥ 14 mm IFD 30-40 mm	04 or less	Bar + locators	Ball-locator/bar and clip	A, B, D, E
Class II	Class IIa AVRS 8-14 mm IFD ≥ 30 mm	04	Ball/locator	-	A, B, D, E
	Class IIb AVRS=8-14 mm IFD < 30 mm	02	Ball/Dalla-Bona	Stud	B, D
Class III	Class IIIa AVRS=6-8 mm IFD ≥ 30	04	Ball/locators	Locator	A, B, D, E
	Class IIIb AVRS 6-8 mm IFD < 30	02	Locators	-	B, D

AVRS: Available vertical restorative space, IFD: Interforaminal distance



**Figure 3:** Demonstrating the final denture of the patient, red arrow indicating the gutta-percha marked from the distal of left mandibular canine teeth to the distal of right canine, and black arrow representing the ball bearing (3 mm) on both maxillary and mandibular prosthesis



**Figure 4:** Digital orthopantomography of a patient, where yellow arrow indicates the gutta-percha marked over the mandibular denture teeth, black arrow representing the calibrated interforaminal distance, and red arrow shows the calibrated vertical space (from crest of alveolar ridge to occlusal plane)

D7432I, Biegheim-Bissingen, 2007). Image Tool computer programming was used to calculate the radio-opaque markings.

The horizontal distance (IFD) and vertical space values i.e., from the crest of mandibular residual alveolar ridge to the proposed occlusal plane were calculated with the help of a two-dimensional digitized measuring tool provided in Vista software (Vistascan Combi+, Model no. D7432I, Biegheim Bissingen, 2007) [Figure 4], the radiographic errors were standardized. Values were then computed and statistically analyzed. Jaw relation and type of mandibular arch form was analyzed and recorded. Descriptive statistics was calculated for each group. The results were subjected to one-way analysis of variance (ANOVA) and two-way ANOVA statistical analysis with a significance level of  $P < 0.05$ .

## RESULTS

Table 2 shows the mean and standard deviation of IFD (horizontal) and the vertical space in Class I, Class II,

and Class III jaw relation patients are  $38.9 \pm 4.5$  mm and  $13.69 \pm 0.9$  mm, respectively. Table 3 shows the comparison of horizontal and vertical distance between Class I, Class II, and Class III jaw relation in 30 edentulous patients. Comparison of mean between these groups depicts that the value of horizontal distance and vertical space is more in Class I than Class II ( $P = 0.001$  and  $P = 0.005$ , respectively), and value of horizontal distance and vertical space in Class III is more than Class II ( $P = 0.013$  and  $P = 0.016$ , respectively). However, there is no clinically significant difference in the values of horizontal distance and vertical space among Class I and Class III ( $P = 0.87$  and  $P = 1.00$ , respectively).

Table 4 shows the correlation of interforaminal (horizontal) distance and vertical distance in Class I, Class II, and Class III jaw relation with different arch form, the mean of square arch form was on higher side, but it was statistically insignificant ( $P > 0.05$ ).

**Table 2: Descriptive analysis of interforaminal (horizontal) distance and vertical distance in Class I, Class II, and Class III jaw relation showing mean and SD of the variables (n=30)**

Groups	n	Mean±SD
Horizontal distance		
Class I	10	41.810±4.8716
Class II	10	34.990±2.3350
Class III	10	40.060±3.2391
Total	30	38.953±4.5789
Vertical distance		
Class I	10	14.160±0.6736
Class II	10	12.920±1.0207
Class III	10	14.000±0.6515
Total	30	13.693±0.9537

SD: Standard deviation

**Table 3: Comparison of horizontal and vertical distance in between Class I, Class II, and Class III jaw relation showing the mean difference and their significance value (P value) (n=30)**

Group	Mean Difference	P-value
Horizontal distance (IFD)		
Class I		
Class II	6.820*	0.001
Class III	1.750	0.874
Class II		
Class I	-6.820*	0.001
Class III	-5.070*	0.013
Class III		
Class I	-1.750	0.874
Class II	5.070*	0.013
Vertical distance		
Class I		
Class II	1.240*	0.005
Class III	0.160	1.00
Class II		
Class I	-1.240*	0.005
Class III	-1.080*	0.016
Class III		
Class I	-0.160	1.00
Class II	1.080*	0.016

IFD: Interforaminal distance, \*demarcates significant values

**Table 4: Descriptive analysis of correlation of interforaminal (horizontal) distance and vertical distance in Class I, Class II, and Class III jaw relation with different arch form showing mean and SD of the variables (n=30)**

Groups	Arch form	n	Mean±SD
Horizontal distance			
	Ovoid	13	38.12±4.97
	Taper	10	38.27±4.54
	Square	07	41.47±3.35
	Total	30	38.95±4.57
Vertical space			
	Ovoid	13	13.84±1.11
	Taper	10	13.51±1.01
	Square	07	13.67±0.53
	Total	30	13.69±0.95

SD: Standard deviation

## DISCUSSION

Implant supported/retained mandibular overdentures have 3 crucial components: The implant fixtures (two or more), the choice of attachment (bars, studs, or magnets), and the prosthesis.

Prosthetic complications in mandibular overdentures have remained a topic of interest in the literature. Berglundh *et al.*, in 2002, in their systematic review concluded, that prosthetic complications reported in mandibular implant overdentures were 4–10 times greater as compared to implant supported fixed prosthesis.<sup>[3]</sup>

Looking at the above literature, it becomes increasingly important to give added consideration in the treatment planning phase of implant supported/retained mandibular prosthesis. The individual anatomic variations in the patients should be respected, and the treatment plan regarding the number of implants and choice of superstructure should be based upon the same.

Evaluation of the individual values showed that among 30 edentulous patients, only 7% of patients has sufficed for OD-5 prosthesis, i.e. five implants were rigidly joined with a bar. Forty percentage of patients had sufficient space for the placement of four or fewer implants with bar supported prosthesis (OD-3, OD-4). In these patients, we need to carefully evaluate the arch form and the residual alveolar bone height. Advanced atrophy of mandibular alveolar ridge would require prosthetic stabilization, which can be achieved with bars.<sup>[4,5]</sup> Further, if the arch form is narrow V-shaped, it is desirable to place two implants with stud attachments, or three implants splinted with bar such that it does not compromise the tongue space area.<sup>[6]</sup> Remaining 53% of patients sufficed for two or four implants with the ball or locator attachment due to limited interocclusal space. These cases require greater parallelism of implants to reduce the prosthetic complications. Chung *et al.* stated that in cases of parallel implants placement, solitary attachments such as locators may exceed the retention offered by Hader bar and metal clip.<sup>[7]</sup> In case, if the operator is not confident of absolute parallelism, a guided surgery may be chosen. In a photoelastic analysis conducted by sadowsky and caputo, there was no significant difference in stress transfer between cantilevered bar, non cantilevered bar and solitary attachments with two or four implants supported denture with intimate contact in parasymphyseal region.<sup>[8]</sup>

Goodacre *et al.*, in 2003, reported that the prosthetic complications reported in mandibular overdentures in the following order (listed in order of frequency): Overdenture loss of retention or adjustment (30%), overdenture rebasing or relining (19%), clip or attachment fracture (17%), overdenture fracture (12%), opposing prosthesis fracture (12%), acrylic resin base fracture (7%), abutment screw loosening (4%), abutment screw fracture (2%), and implant fracture (1%).<sup>[9]</sup>

Considering the above data and varied intraoral situations, a classification system is developed based on IFD and AVRS [Table 1]. Ahuja and Cagna<sup>[10]</sup> proposed a classification



considering the vertical space as a decisive parameter for attachment selection. However, the classification has not considered the IFD. The classification system presented here suggests the size, number, and position of implants to be placed with the associated prosthetic designs. Once established, it would facilitate the conceptualization of available space in the patient and associated treatment modalities.

### Classification

- Class I describes the clinical condition where AVRS, from the soft tissue crest of the residual edentulous ridge to the proposed occlusal plane, is equal to or  $>14$  mm. (This situation may associate with long-standing edentulism, characterized by significant alveolar bone resorption. There is a good amount of vertical and horizontal restorative space, so a wide range of implant overdenture superstructures are possible. This classification may be further subdivided on the basis of IFD):
  - Class Ia, wherein IFD  $\geq 40$  mm and AVRS  $\geq 14$  mm. While designing the prosthesis for Class Ia, an option of five or fewer implants could be used with bar and clip attachments or bar and locators attachments
  - Class Ib, wherein IFD is in the range of 30–40 mm and AVRS is  $\geq 14$  mm. While designing the prosthesis for Class Ib, an option of four or fewer implants could be used with bar and clip attachments or ball and locators attachments.
- Class II describes a condition when AVRS, from the crest of the residual edentulous ridge to the proposed occlusal plane, is in a range between 8 and 14 mm. (Large range of overdenture attachments could be used in this case. It is further subdivided on the basis of IFD):
  - Class IIa, wherein IFD  $\geq 30$  mm and AVRS is between 8 and 14 mm. For Class IIa, an option of four implants could be used with ball and locators/Dalla-Bona attachments when designing the prosthesis
  - Class IIb, wherein IFD  $\leq 30$  mm and AVRS is between 8 and 14 mm. For Class IIb, an option of two could be used with ball and stud type when designing the prosthesis.
- Class III is a condition in which AVRS from the crest of the residual ridge to the occlusal plane is between 6 and 8 mm. (In this condition due to dimensional restrictions, selection of number of implants and an appropriate overdenture attachment system becomes more critical, particularly at the low end of this dimensional range. It is further subdivided on the basis of IFD):

- Class IIIa, wherein IFD  $\geq 30$  mm and AVRS is between 6 and 8 mm. For Class IIIa, an option of four implants could be used with ball or locators attachments when designing the prosthesis
- Class IIIb, wherein IFD  $\leq 30$  mm and AVRS is between 6 and 8 mm. For Class IIIb, an option of two could be used with locator type of attachments when designing the prosthesis.

The deciding factor for rehabilitating the edentulous patients with implant supported mandibular overdenture is interforaminal space; however, the final selection is modified by AVRS.

### CONCLUSION

The article proposes a simple classification system based on the AVRS and IFD, for establishing the guidelines in the treatment planning of the edentulous mandible, to aid in selection of implant size, number, and position along with the associated prosthetic design.

### Financial support and sponsorship

Nil.

### Conflicts of interest

There are no conflicts of interest.

### REFERENCES

1. Zarb GA, Schmitt A. The edentulous predicament. I: A prospective study of the effectiveness of implant-supported fixed prostheses. *J Am Dent Assoc* 1996;127:59-65.
2. Misch CE. *Dental Implant Prosthetics*. 11<sup>th</sup> ed., Vol. 58. U.S.A: Elsevier Mosby; 2005. p. 130-40.
3. Berglund T, Persson L, Klinge B. A systematic review of the incidence of biological and technical complications in implant dentistry reported in prospective longitudinal studies of at least 5 years. *J Clin Periodontol* 2002;29 Suppl 3:197-212.
4. Heckmann SM, Schrott A, Graef F, Wichmann MG, Weber HP. Mandibular two-implant telescopic overdentures. *Clin Oral Implants Res* 2004;15:560-9.
5. Eitner S, Schlegel A, Emeka N, Holst S, Will J, Hamel J. Comparing bar and double-crown attachments in implant-retained prosthetic reconstruction: A follow-up investigation. *Clin Oral Implants Res* 2008;19:530-7.
6. Mericske-Stern RD, Taylor TD, Belser U. Management of the edentulous patient. *Clin Oral Implants Res* 2000;11 Suppl 1:108-25.
7. Chung KH, Chung CY, Cagna DR, Cronin RJ Jr. Retention characteristics of attachment systems for implant overdentures. *J Prosthodont* 2004;13:221-6.
8. Sadowsky SJ, Caputo AA. Effect of anchorage systems and extension base contact on load transfer with mandibular implant-retained overdentures. *J Prosthet Dent* 2000;84:327-34.
9. Goodacre CJ, Bernal G, Rungcharassaeng K, Kan JY. Clinical complications with implants and implant prostheses. *J Prosthet Dent* 2003;90:121-32.
10. Ahuja S, Cagna DR. Classification and management of restorative space in edentulous implant overdenture patients. *J Prosthet Dent* 2011;105:332-7.